This is a digital copy of a book that was preserved for generations on library shelves before it was carefully scanned by Google as part of a project to make the world's books discoverable online.

It has survived long enough for the copyright to expire and the book to enter the public domain. A public domain book is one that was never subject to copyright or whose legal copyright term has expired. Whether a book is in the public domain may vary country to country. Public domain books are our gateways to the past, representing a wealth of history, culture and knowledge that's often difficult to discover.

Marks, notations and other marginalia present in the original volume will appear in this file - a reminder of this book's long journey from the publisher to a library and finally to you.

Usage guidelines

Google is proud to partner with libraries to digitize public domain materials and make them widely accessible. Public domain books belong to the public and we are merely their custodians. Nevertheless, this work is expensive, so in order to keep providing this resource, we have taken steps to prevent abuse by commercial parties, including placing technical restrictions on automated querying.

We also ask that you:

+ *Make non-commercial use of the files* We designed Google Book Search for use by individuals, and we request that you use these files for personal, non-commercial purposes.
+ *Refrain from automated querying* Do not send automated queries of any sort to Google's system: If you are conducting research on machine translation, optical character recognition or other areas where access to a large amount of text is helpful, please contact us. We encourage the use of public domain materials for these purposes and may be able to help.
+ *Maintain attribution* The Google "watermark" you see on each file is essential for informing people about this project and helping them find additional materials through Google Book Search. Please do not remove it.
+ *Keep it legal* Whatever your use, remember that you are responsible for ensuring that what you are doing is legal. Do not assume that just because we believe a book is in the public domain for users in the United States, that the work is also in the public domain for users in other countries. Whether a book is still in copyright varies from country to country, and we can't offer guidance on whether any specific use of any specific book is allowed. Please do not assume that a book's appearance in Google Book Search means it can be used in any manner anywhere in the world. Copyright infringement liability can be quite severe.

About Google Book Search

Google's mission is to organize the world's information and to make it universally accessible and useful. Google Book Search helps readers discover the world's books while helping authors and publishers reach new audiences. You can search through the full text of this book on the web at `http://books.google.com/`

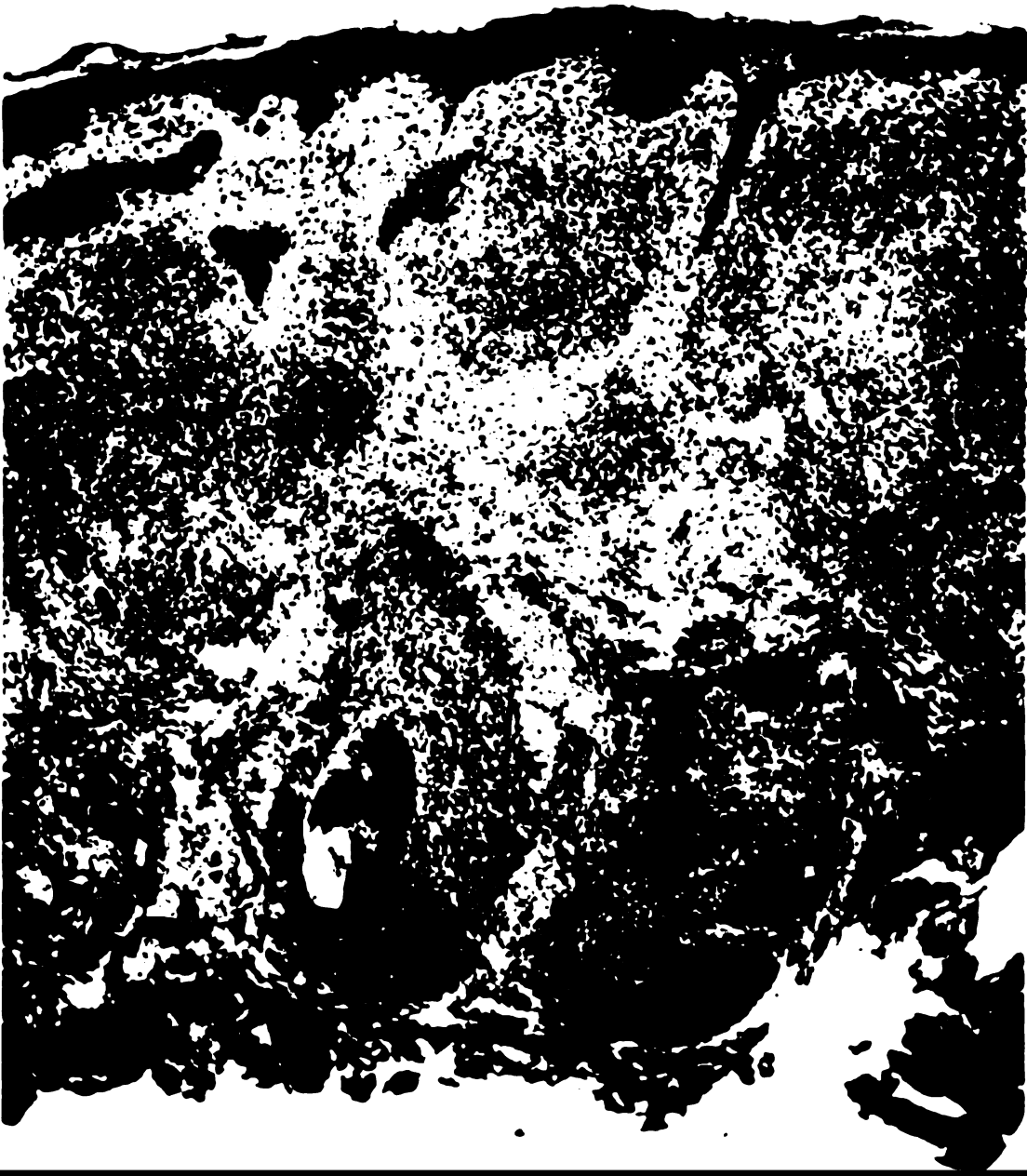

Transactions

American Medical Association.
Section on Dermatology

Digitized by Google



Digitized by Google

6 1
A S
M
A 8

John G. Eulks, Jr.

Suite 3122
JENKINS ARCADE BUILDING
Pittsburg, Pa.

Digitized by Google

Digitized by Google

TRANSACTIONS OF THE

SECTION ON

DERMATOLOGY

of the
American Medical Association
at the Sixty-Sixth Annual
Session, held at San Francisco,
June 22 to 25, 1915

AMERICAN MEDICAL ASSOCIATION PRESS
CHICAGO: NINETEEN HUNDRED AND FIFTEEN

Digitized by Google

Reprinted from
THE JOURNAL
of the
AMERICAN MEDICAL ASSOCIATION

Copyright 1915
by the
American Medical Association

Digitized by Google

Medical
Engin
10-7-25
12372

OFFICERS FOR 1914-1915

CHAIRMAN

HOWARD FOX - - - - - - - - - - NEW YORK

VICE CHAIRMAN

A. RAVOGLI - - - - - - - - - - - CINCINNATI

SECRETARY

H. H. HAZEN - - - - - - - WASHINGTON, D. C.

EXECUTIVE COMMITTEE

CHARLES J. WHITE, BOSTON
JOSEPH ZEISLER, CHICAGO
RICHARD L. SUTTON, KANSAS CITY, MO.

OFFICERS FOR 1915-1916

CHAIRMAN

HOWARD MORROW - - - - - - - SAN FRANCISCO

VICE CHAIRMAN

EVERETT S. LAIN - - - - - - - OKLAHOMA CITY

SECRETARY

H. H. HAZEN - - - - - - - WASHINGTON, D. C.

EXECUTIVE COMMITTEE

JOSEPH ZEISLER, CHICAGO
RICHARD L. SUTTON, KANSAS CITY, MO.
HOWARD FOX, NEW YORK

Digitized by Google

Digitized by Google

LIST OF OFFICERS

This Section was organized in 1887 and has been served by the following officers, the year being the date of election. The list is compiled from the published records, which are incomplete in some cases. It will be appreciated if any errors are brought to the attention of the Secretary of the American Medical Association.

SECTION ON DERMATOLOGY AND SYPHILOGRAPHY

1887 Chairman, L. D. Bulkley, New York.
Secretary, F. F. Dunlop, Kentucky.

1888 Chairman, L. D. Bulkley, New York.
Secretary, W. T. Corlett, Cleveland, Ohio.

1889 Chairman, J. E. Atkinson, Baltimore.
Secretary, W. T. Corlett, Cleveland, Ohio.

1890 Chairman, L. D. Bulkley, New York.
Secretary, W. T. Corlett, Cleveland, Ohio.

1891 Chairman, L. D. Bulkley, New York.
Secretary, J. C. McGuire, Washington, D. C.

1892 Chairman, L. A. Duhring, Philadelphia.
Secretary, W. H. Dunlop, New York.

1893 Chairman, A. H. Ohmann-Dumesnil, St. Louis.
Secretary, L. F. Frank, Milwaukee, Wis.

1894 Chairman, A. E. Regensburger, San Francisco.
Secretary, D. H. Rand, Portland, Ore.

1895 Chairman, L. D. Bulkley, New York.
Secretary, T. C. Gilchrist, Baltimore.

1896 Chairman, A. Ravogli, Cincinnati.
Secretary, T. C. Gilchrist, Baltimore.

1897 Chairman, A. W. Brayton, Indianapolis.
Secretary, T. C. Gilchrist, Baltimore.

SECTION ON CUTANEOUS MEDICINE AND SURGERY

1898 Chairman, W. T. Corlett, Cleveland, Ohio.
Secretary, J. M. Blaine, Denver.

1899 Chairman, L. D. Bulkley, New York.
Secretary, R. R. Campbell, Chicago.

1900 Chairman, W. L. Baum, Chicago.
Secretary, R. R. Campbell, Chicago.

1901 Chairman, H. W. Stelwagon, Philadelphia.
Secretary, R. R. Campbell, Chicago.

1902 Chairman, John A. Fordyce, New York.
Secretary, R. R. Campbell, Chicago.
Delegates, M. B. Hartzell, Philadelphia, and William L. Baum, Chicago.

1903 Chairman, Henry G. Anthony, Chicago.
Secretary, R. R. Campbell, Chicago.
Delegate, Jay F. Schamberg, Philadelphia.

1904 Chairman, Douglas W. Montgomery, San Francisco.
Secretary, R. R. Campbell, Chicago.
Delegate, A. W. Brayton, Indianapolis.

1905 (The Section did not meet and the old officers acted two years.)

1906 Chairman, R. R. Campbell, Chicago.
Secretary, M. L. Heidingsfeld, Cincinnati.
Delegate, Henry R. Varney, Detroit.

Digitized by Google

LIST OF OFFICERS—Continued

1907 Chairman, M. B. Hartzell, Philadelphia.
Secretary, M. L. Heidingsfeld, Cincinnati.
Delegate, R. R. Campbell, Chicago.

1908 Chairman, William Allen Pusey, Chicago.
Secretary, M. L. Heidingsfeld, Cincinnati.
Delegate, R. R. Campbell, Chicago.

SECTION ON DERMATOLOGY

1909 Chairman, Grover W. Wende, Buffalo, N. Y.
Secretary, H. R. Varney, Detroit.
Delegate, William Allen Pusey, Chicago.

1910 Chairman, Charles J. White, Boston.
Vice Chairman, Martin F. Engman, St. Louis.
Secretary, H. R. Varney, Detroit.

1911 Chairman, Charles J. White, Boston.
Vice Chairman, Martin F. Engman, St. Louis.
Secretary, H. R. Varney, Detroit.

1912 Chairman, Joseph Zeisler, Chicago.
Vice Chairman, H. R. Varney, Detroit.
Secretary, Howard Fox, New York.
Delegate, Frank C. Knowles, Philadelphia.

1913 Chairman, Richard L. Sutton, Kansas City, Mo.
Vice Chairman, J. B. Kessler, Iowa City, Iowa.
Secretary, Howard Fox, New York.
Delegate, William A. Pusey, Chicago.

1914 Chairman, Howard Fox, New York.
Vice Chairman, A. Ravogli, Cincinnati.
Secretary, H. H. Hazen, Washington, D. C.
Delegate, O. H. Foerster, Milwaukee.

1915 Chairman, Howard Morrow, San Francisco.
Vice Chairman, Everett S. Lain, Oklahoma City.
Secretary, H. H. Hazen, Washington, D. C.
Delegate, Ernest Dwight Chipman, San Francisco.

Digitized by Google

CONTENTS

PAGE

List of Officers 5

Proceedings of the Section 9

Chairman's Address: Dermatology of the Ancients. Howard Fox 13

An Uncommon Case of Multiple Benign Sarcoid of the Skin. Joseph Zeisler 33

The Management of Burns. A. Ravogli 42

Symptomatology and Treatment of Some Common Palmar Eruptions. Richard L. Sutton 55

Lupus Erythematosus of the Mucous Membranes. George D. Culver 67

Illustrations of the History of Leprosy. Douglass W. Montgomery 84

Symptoms and Diagnosis of Leprosy with Report of Cases. Howard Morrow and A. W. Lee 96

The Etiology and Treatment of Leprosy. Ernest Dwight Chipman 108

Cases from the Skin Clinic of Leland Stanford Jr. University School of Medicine. Harry E. Alderson 124

Factitious Dermatoses. Oliver S. Ormsby 129

Acanthosis Nigricans as an Indication of Internal Malignancy. A. J. Markley 165

Xeroderma Pigmentosum. Its Treatment with Autogenous Serum. J. B. Kessler 172

Cutaneous Cancer of the Extremities. H. H. Hazen 177

The Roentgen-Ray Treatment of Skin Diseases. George M. MacKee 189

Radiant Energy in the Treatment of Diseases of the Skin. Everett S. Lain 206

List of Fellows Registering in This Section 217

Index 221

Digitized by Google

Digitized by Google

PROCEEDINGS OF THE SECTION

Tuesday, June 22—Afternoon

The Chairman, Dr. Howard Fox, New York, called the meeting to order at 2:20 p. m. Dr. Fox expressed his appreciation of the honor conferred in electing him to the high office which had been held by Dr. Zeisler and Dr. Sutton, and he thanked Dr. H. H. Hazen, secretary, for energetic, kind and cordial cooperation, and the San Francisco gentlemen for their kindness in providing the section with a symposium on leprosy.

Dr. Howard Fox, New York, then read the Chairman's Address entitled "Dermatology of the Ancients."

The Chairman designated the following Nominating Committee: Dr. A. Ravogli, Dr. A. J. Markley and Dr. George Miller MacKee.

Dr. Joseph Zeisler, Chicago, read a paper on "An Uncommon Case of Multiple Sarcoid of the Skin." Discussed by Dr. Richard L. Sutton, Kansas City, Mo.

Dr. A. Ravogli, Cincinnati, read a paper on "The Treatment of Burns." Discussed by Drs. W. A. Pusey, Chicago; Joseph Zeisler, Chicago; Ernest Dwight Chipman, San Francisco, and A. Ravogli, Cincinnati.

Dr. Richard L. Sutton, Kansas City, Mo., read a paper on "Symptomatology and Treatment of Some Common Palmar Eruptions." Discussed by Drs. A. Ravogli, Cincinnati; W. A. Pusey, Chicago; Howard Morrow, San Francisco; Ernest Dwight Chipman, San Francisco; Douglas W. Montgomery, San Francisco; Howard Fox, New York; E. S. Lain, Oklahoma City; A. J. Markley, Denver; J. C. Pickett, San Francisco; George D. Culver, San Francisco; Richard L. Sutton, Kansas City, Mo., and Howard Fox, New York.

Dr. George D. Culver, San Francisco, read a paper on "Lupus Erythematosus of the Mucous Membranes." Discussed by Drs. Joseph Zeisler, Chicago; Everett S. Lain, Oklahoma City; J. B. Kessler, Iowa City, Iowa; W. A. Pusey, Chicago; Douglas W. Montgomery, San Francisco; A. Ravogli, Cincinnati; A. J. Markley, Denver; H. H. Hazen, Washington, D. C.; Ernest Dwight Chipman, San Francisco, and George D. Culver, San Francisco.

Thursday, June 24—Morning

The Nominating Committee presented its report, placing in nomination the following names: Chairman, Dr. Howard Morrow, San Francisco; Vice-Chairman, Dr. Everett S. Lain,

Digitized by Google

Oklahoma City; Delegate, Dr. Ernest Dwight Chipman, San Francisco; Alternate, Dr. George Miller MacKee, New York.

On motion, the secretary cast one ballot for the nominees presented by Dr. Ravogli, chairman of the Nominating Committee, which motion being carried, the chairman declared the members elected to the respective offices mentioned.

A recess was taken for five minutes to receive and arrange twelve patients brought by Dr. Howard Morrow from the Isolation Hospital, San Francisco.

The Chair reconvened the section, and the following papers were read as a Symposium on Leprosy:

Dr. Douglass W. Montgomery, San Francisco, "Historical Review of Leprosy."

Drs. Howard Morrow and A. W. Lee, San Francisco, "Symptomatology and Diagnosis of Leprosy, with Presentation of Cases."

Dr. Ernest Dwight Chipman, San Francisco, "Treatment of Leprosy."

Dr. A. A. O'Neill, San Francisco, "Public Control of Lepers." [Dr. O'Neill gave an oral presentation of the subject.]

These papers were discussed by Drs. Joseph Zeisler, Chicago; George W. McCoy; Honolulu; A. Ravogli, Cincinnati; Richard L. Sutton, Kansas City, Mo.; Schmidt; Everett S. Lain, Oklahoma City; Howard Fox, New York; Douglass W. Montgomery, San Francisco; Howard Morrow, San Francisco; A. W. Lee, San Francisco; A. A. O'Neill, San Francisco, and Ernest Dwight Chipman, San Francisco.

Dr. Harry E. Alderson, San Francisco. "Demonstration of Cases from the Skin Clinic of the Stanford University Medical School." Discussed by Drs. George Miller MacKee, New York; Oliver S. Ormsby, Chicago; Joseph Zeisler, Chicago; Everett S. Lain, Oklahoma City; Richard L. Sutton, Kansas City, Mo.; A. J. Markley, Denver; Ernest Dwight Chipman, San Francisco; Howard Fox, New York, and Harry E. Alderson, San Francisco.

Thursday, June 24—Afternoon

The Chairman called the section to order at 2:10 p. m., and invited Vice-Chairman Dr. Ravogli to take the chair.

Dr. Oliver S. Ormsby, Chicago, read a paper on "Fictitious Dermatoses." Discussed by Drs. Howard Morrow, San Francisco; Lasher Hart, Los Angeles; George Miller MacKee, New York; A. J. Markley, Denver; Richard Sutton, Kansas City, Mo.; and Oliver S. Ormsby, Chicago.

Dr. A. J. Markley, Denver, read a paper on "Acanthosis Nigricans as an Indication of Internal Malignancy." Discussed by Dr. Oliver S. Omsby, Chicago.

Dr. J. B. Kessler, Iowa City, Iowa, read a paper on "Xeroderma Pigmentosum: Its Treatment with Autogenous Serum."

Digitized by Google

(Dr. Fox returned to the chair.) Discussed by Drs. Oliver S. Ormsby, Chicago, and J. B. Kessler, Iowa City, Iowa.

Dr. H. H. Hazen, Washington, D. C., read a paper on "Cutaneous Cancer of the Extremities." Discussed by Drs. A. Ravogli, Cincinnati; Richard L. Sutton, Kansas City, Mo.; Douglass W. Montgomery, San Francisco; Harry E. Alderson, San Francisco; George Miller MacKee, New York; Everett S. Lain, Oklahoma City; Howard Fox, New York, and H. H. Hazen, Washington, D. C.

Dr. George Miller MacKee, New York, read a paper on "The Present Status of the Roentgen Ray in the Treatment of Diseases of the Skin."

Dr. Everett S. Lain, Oklahoma City, read a paper on "Radiant Energy in the Treatment of Diseases of the Skin."

These two papers were discussed by Drs. Richard L. Sutton, Kansas City, Mo.; Ernest Dwight Chipman, San Francisco; Douglass W. Montgomery, San Francisco; H. H. Hazen, Washington, D. C.; Harry E. Alderson, San Francisco; George Miller MacKee, New York, and Everett S. Lain, Oklahoma City.

Digitized by Google

Digitized by Google

DERMATOLOGY OF THE ANCIENTS *

HOWARD FOX, M.D.
NEW YORK

The present condition and the future prospects of dermatology have been ably discussed by former chairmen of this section. Since Hippocrates has said that the physician must know what his predecessors have known, if he does not wish to deceive both himself and others, it has seemed to me that an account of the dermatologic knowledge of our earliest predecessors might prove of interest if not of practical value.

An historical sketch of dermatology of the ancients properly begins with the Egyptians, as there is no doubt that the written account of their civilization is the oldest that is known. According to Comrie,[1] the medical practitioners in the early days of Egypt belonged to a learned class, enjoyed a high social position and were in many cases the friends and counselors of kings. This is shown by monuments that were erected to them, one of their number, indeed, I-em-hotep (3000 B. C.) having been later deified. As a rule, however, the names and personalities of the physicians, however skilful or famous they may have been, remain unknown.

The source of our knowledge of ancient Egyptian medicine is mostly derived from six papyri, all having been discovered and deciphered within recent years. The most important of these is the famous Papyrus Ebers,[2] a manuscript nearly 65 feet in length. It consists of 108 columns (or pages), each composed

* Chairman's Address.

1. Comrie, J. D.: Medicine Among the Assyrians and Egyptians in 1500 B. C., Edinburgh Med. Jour., 1909, ii, 101.

2. Ebers, G. M.: Papyrus Ebers, Das Aelteste Buch über Heilkunde (German trans. by Joachim), Berlin, 1890.

Digitized by Google

of about twenty lines of so-called hieratic script, beautifully written in red and black ink. This precious document, together with five other papyri, contain in less than 185 pages a most valuable amount of information about medicine and pharmacology of the ancient Egyptians. From various data it was calculated by Ebers that the Papyrus which bears his name was written about 1552 B. C., at a period before the exodus of the Jews from Egypt. It is now generally agreed that the Ebers Papyrus is not the work of any single author but a compilation of medical knowledge of many previous centuries. Like the Hearst Papyrus, as Reisner[3] says, it is "only a collection of practical remedies intended for the use of practicing physicians."

While the Egyptians doubtless had a considerable knowledge of practical medicine, they felt that its effectiveness was increased by the addition to some of their prescriptions of various magic incantations. Many of their drugs had a real therapeutic value, while others contained various disgusting ingredients whose purpose it was to drive out the wicked demons from the bodies of the unfortunate sufferers. An example of the latter class is shown by a prescription in the Berlin Papyrus, containing seven ingredients, five of which consisted of the dung of various animals.

The dermatologist should be especially interested in the medicine of the ancient Egyptians on account of the prevalence among them of skin diseases. We learn of this indirectly from Pliny and other writers, and have direct evidence from the numerous references to diseases of the skin and scalp that appear in the medical papyri. In a tabulated list of various diseases in the Papyrus Ebers, von Klein[4] mentions, among diseases of the scalp, "tumors, alopecia and eruptions," also prescriptions to prevent hair from turning gray, to produce its growth on bald heads, to promote the growth, to make it grow on cicatrices,

3. Reisner, G. A.: The Hearst Medical Papyrus, Leipzig, 1905, p. 4.
4. Von Klein, C. H.: The Medical Features of the Papyrus Ebers, The Journal A. M. A., Dec. 23, 1905, p. 1928.

Digitized by Google

to depilate the scalp and to dye the hair. Under facial diseases he mentions sunburn, freckles, wrinkles, discolorations, roughness and blotches; under diseases of the skin, pustules, prurigo, swellings, tumors with fetid suppurations, leprosy, eczema, scabies, itching cankers, boils and carbuncles. In addition, von Klein mentions gangrene, eschar formation, burns, spots or white cicatrices which such sores leave and alteration of the hair on the burnt surfaces, perspiration of the feet, sore toes, corns, bunions, callosities of all sorts and falling nails. In Chapter 12 of the Hearst Papyrus there are thirteen remedies, according to Reisner, "relating to the hair and skin, etc."

Some of the dermatologic prescriptions in the Ebers Papyrus are extraordinary, to say the least, in their composition. As an example, equal parts of the toes of a dog, ripe dates and asses' hoof were suggested as a remedy to make hair grow, the ingredients first being boiled carefully in a pan of oil. Another prescription for baldness, that has been frequently quoted, consisted of equal parts of cerebrospinal fluid and writing ink. Perhaps the most unusual recipe for the cure of baldness consisted of equal parts of the fat of a lion, hippopotamus, crocodile, goose, snake and ibex. Thus we see that goose grease, which has recently been recommended as a very penetrating ointment base, is not particularly new to the medical profession. Most of the ancient Egyptian prescriptions were ordered to be taken for a period of not more than four days, a fact that might account for the prevalence of skin diseases which, as we know, are so often distressingly chronic. While most cases of scabies might have been cured by appropriate treatment of four days, we hate to think of the disappointment of the sufferers from psoriasis or chronic eczema, whose physicians felt content with such a short course of treatment.

"The question of syphilis," writes Comrie, "has been raised in connection with the advanced atheroma that

Digitized by Google

has been found in the large arteries, the diffuse signs of periostitis and particularly in regard to a case of ulceration of the skull described recently by Professor Lortet. No absolutely conclusive evidence as to the existence of this disease in early Egypt has, however, yet been found, and Professor Elliot Smith has demonstrated that the supposed ulceration is probably due to the attack of insects ages after the bones were buried."

That specialism in medicine is not confined to modern times is shown by the account of Herodotus, who was one of the two chief authorities on Egyptian medicine in the fifth century before Christ. Referring to the medical practitioners of Egypt, Herodotus says, "The art of medicine is divided among them. Each physician applies himself to one disease only and not more. All places abound in physicians. Some physicians are for the eyes, others for the teeth, others for the belly and others for the internal disorders." The fame of at least one Egyptian specialist in skin diseases, it appears, was great enough for him to be summoned to Greece in consultation.

The conception of medicine among the ancient Egyptians was certainly much broader than that of the present day. Thus the subject of cosmetics was not considered beneath the dignity of the profession to practice as a special art. According to Paschkis, identical substances that are in vogue today as cosmetics were used thousands of years ago in Egypt. No less a personage than Cleopatra is said to have written a treatise on the subject, which has unfortunately perished. Furthermore, the duties of the medical fraternity included the work that is nowadays performed by professional vermin exterminators, and we find in the papyri recipes for preventing bees from stinging, flies from biting and rats from eating corn.

Among the ancient Hebrews the art and science of medicine occupies a peculiar position from the fact that all of our knowledge on the subject is derived from nonmedical sources. There were no ancient

Digitized by Google

Hebrew books devoted especially to medicine, and we cannot properly speak of a system of Hebrew medicine comparable to that of the ancient Egyptians, Hindoos or Greeks. The sources of our information are chiefly the Bible and Talmud. The oldest Hebrew literature was the Pentateuch or Mosaic Law, revealed to Moses by Jehovah on Mount Sinai, and centuries after committed to writing. According to Jewish belief, other revelations beside this "written law" were made to Moses, which were handed down from generation to generation as oral traditions and eventually compiled and recorded in the third century of the Christian era. This compilation was known as the Mishnah, and consisted of a "collection of binding precepts and legal decisions deduced by the ancient rabbis from the Pentateuch and itself forming a second or oral law." In the course of time, numerous commentaries and discussions relating to the Mishnah were also compiled and committed to writing, which were known as the Gemara. The Mishnah and Gemara together constituted the Talmud, of which there were two, the Palestinian and Babylonian Talmuds. Of these the Babylonian Talmud was much more voluminous and of somewhat later date than the Palestinian compilation, being completed about the sixth century A. D.

The references to medical subjects in the Bible and Talmud deal mostly with the prevention rather than the treatment of diseases, and the remark of Bennett[5] seems quite proper that "the Mosaic sanitary code may be said to constitute the basis of modern sanitary legislation." One of the functions of the priest, who may be considered as a sort of health officer, was to decide whether a skin disease was "clean" or "unclean," though nothing is said about his having to treat these diseases. While it is quite likely that the priests and some of the prophets had more or less medical knowledge, the practice of medicine, such as it was, was

5. Bennett, Sir R.: The Diseases of the Bible, 1887.

Digitized by Google

carried on by the physician or rophé. That the esteem in which the physician was held varied considerably may be seen from a saying in the Talmud that the proper place for the best physician was in Hades, while according to another more flattering saying, the wise man was advised not to live in a town that has no physician or bloodletter.

Before discussing particular diseases of the ancient Hebrews, I should like to mention the difficulty of their recognition as pointed out by Higier.[6] As this writer says, we are often puzzled at the present day to make a diagnosis when a patient is presented to us for examination with a full history. When a history alone, without the patient is presented, our difficulties increase. When, however, the history was written many centuries ago by physicians whose terminology and conception of medicine were different from our own, we are still further embarrassed. But when such ancient histories of disease were written by laymen, we must admit in most cases our complete helplessness in making a proper diagnosis. It is such difficulties as these that are encountered in the study of biblical leprosy.

To the modern dermatologist, the subject of leprosy as described in the Old Testament is as fascinating as it is difficult. The question to be settled is whether the disease described by Leviticus as Zaraath and translated as leprosy in the Authorized Version really refers to the modern disease leprosy, with which we are all familiar. The thirteenth chapter of Leviticus contains fifty-nine verses which consist of hard and fast rules for the differentiation of leprosy from harmless diseases of the skin. An idea of their medical value may be obtained by reading the following verses:

1. And the Lord spake unto Moses and Aaron saying
2. When a man shall have in the skin of his flesh a rising (sëeth) a scab, (sappachath) or bright spot (bahéreth) and

6. Higier, H.: Was lehren uns die Bibel, der Talmud, und das Evangelium über Lepra und Syphilis? St. Petersburg Med. Wchnschr., 1907, xxiv, 67.

Digitized by Google

it be in the skin of his flesh like the plague of leprosy; then he shall be brought unto Aaron the priest or to one of his sons the priests:

3. And the priest shall look on the plague in the skin of the flesh: and when the hair in the plague is turned white, and the plague in sight be deeper than the skin of the flesh, it is a plague of leprosy: and the priest shall look on him and pronounce him unclean:

Reading further, we are told that if the symptoms of white hair and depression of the patches are not present, the individual is to be isolated for further observation, and if at the end of two weeks the "scab" has spread, the case is pronounced leprosy.

McEwen,[7] who has recently written a most interesting and careful analysis of the subject, says that the "differential criteria, white hair, depression and spreading, are absurdly insufficient to constitute a dividing line between harmless skin diseases and leprosy." He then proceeds to tabulate the eleven pathologic conditions of the skin mentioned in the remaining verses of the chapter, which he states are "far too scant effectually to distinguish leprosy from the many other skin diseases which must have been prevalent at that time." With this opinion, I most heartily agree, as also with that expressed by my father, Dr. George Henry Fox,[8] who said in referring to the Mosaic law that "there are no scriptural references to any disease which is unmistakably the leprosy of the present day." If the description in Leviticus does not accord with the conception of modern leprosy, how much less do certain miraculous statements convey the idea of this disease, as when we read in Exodus 4-6, that Moses put his hand into his bosom at the command of the Lord "and when he took it out, behold his hand was leprous as snow."

7. McEwen, E. L.: The Leprosy of the Bible in Its Medical Aspect, Biblical World, 1911, xxxviii, No. 3.

8. Fox, G. H.: Biblical and Modern Leprosy, Pop. Sc. Month., 1884, xxiv, 797.

Digitized by Google

Various modern writers, including von Bärensprung,[9] Danielson, Neumann,[10] and Bloch,[11] consider the Zaraath of the Bible to have been true leprosy. Preuss,[12] who is an authority on the medicine of the Bible and Talmud, is also of this opinion, and calls attention to the chronicity of the disease, to the fear in which it was held and to the fact that its victims were not bedridden. He argues that there are only two diseases, namely, syphilis and leprosy, which could inspire such fear, and, by the easy exclusion of syphilis, concluded that the disease Zaraath referred to true leprosy. On the other hand, Münch[13] considered the disease to be an endemic vitiligo, and Katzenelson and Sack[14] thought it a form of dermatomycosis from the references to spreading of the lesions and to leprosy of garments. Finaly[15] thought it syphilis, while Ebstein[16] considered that Zaraath represented a composite name for various skin diseases that cannot now be recognized.

While it thus seems difficult or impossible to understand the significance of the word Zaraath from a medical standpoint, a more reasonable explanation is afforded from the religious point of view as expressed in the conclusion of McEwen[17] that "the word leprosy did not refer ever and always to true leprosy, but was rather a generic term covering various sorts of inflammatory skin diseases, which rendered the one afflicted unfit to associate with others, not because his condition was contagious as a disease, but because by virtue of the belief among the Hebrews in the principle today known as 'taboo,' it disqualified him for the worship

9. Von Bärensprung, F.: Die Hautkrankheiten, Erlangen, 1859, p. 1.
10. Neumann, I.: Lehrbuch der Hautkrankheiten, Vienna, 1880, p. 1.
11. Bloch, I.: Der Ursprung der Syphilis, Part 2, Jena, 1911, p. 486.
12. Preuss, J.: Biblisch-talmudische Medizin, Berlin, 1911, p. 369.
13. Münch, G. N.: Die Zaraath (Lepra) der Hebräischen Bibel, Dermatologische Studien, 1893, xvi, 72.
14. Sack, A.: Was ist die Zaraath (Lepra) der Hebräischen Bibel? Virchows Arch. f. path. Anat., 1896, clxiv, 201.
15. Finaly, S.: Ueber die wahre Bedeutung des Aussatzes in der Bibel, Arch. f. Dermat. u. Syph., 1870, ii, 125.
16. Ebstein, W.: Die Medizin im Alten Testament, Stuttgart, 1901, 89.
17. McEwen, E. L.: The Leprosy of the Bible: Its Religious Aspects, Biblical World, 1911, xxxviii, No. 4.

Digitized by Google

of Jehovah, threatened others by contact with a like disqualification, and required ceremonial procedure for removal."

Among the references in the Bible of dermatologic interest may be mentioned the disease with which Job was afflicted. We read in the description that he was smitten by Satan "with sore boils (schechin ra) from the sole of his foot unto his crown," and, furthermore, that "he took him a potsherd to scrape himself withal." It would seem that a diagnosis of boils would hardly be compatible with the pruritus that would cause the patient to sit in the ashes, as we read, and scratch himself with a piece of pottery. From a consideration of the entire narrative, Preuss considers the disease of Job to have been a universal eczema.

An interesting case of hypertrichosis is mentioned in the Bible in the person of Esau, the twin brother of Jacob, who at his birth was "all over like a hairy garment," and of whom Jacob later said "Behold, Esau my brother is a hairy man and I am a smooth man."

The medicine of the ancient Hindoos ranks next to that of the Egyptians, Babylonians and Hebrews in point of antiquity. It is superior to the former, according to Baas,[18] and not far behind Grecian medicine in the extent and elaboration of its doctrines. The oldest and most celebrated treatises on Hindoo medicine that are now extant are the Charaka Sauhita and Susruta Ayurveda. "An older work," writes Dutt,[19] "called Ayurveda is mentioned in both these works as having formed a part of Athar Veda. It is said to have been originally composed by Brahma the Creator and to have consisted of a thousand chapters and a hundred thousand slokas. Afterward in con-

18. Baas, J. H.: Outlines of the History of Medicine and the Medical Profession, New York, 1889, p. 49.

19. Dutt, U. C.: The Materia Medica of the Hindus compiled from Sanskrit Medical Work, Calcutta, 1877, p. 6.

Digitized by Google

sideration of the short lives and small intellects of human beings it was abridged into eight chapters. The Ayurveda with a hundred thousand slokas is probably a myth, but the Ayurveda with its eight divisions seems to have had a real existence although it is not available at the present day. It probably became obsolete after the works of Charaka and Susruta were composed." The works of Charaka and Susruta are supposed to be commentaries on the Ayurveda, and though written by men, are given divine origin. Thus, it is said that Charaka was prepared by Atreya, who was instructed by Indra the King of Heaven, while Dhanwantaree, the physician to the gods, imparted his knowledge to his pupil Susruta. Charaka is the more ancient work, and is thought by many to have been written about the time of Christ. Susruta was probably of later origin, and is especially noted for its attention to surgery.

The relation of all the ancient systems of medicine to the priestly class is nowhere better shown than in India, where the art of medicine was controlled by Brahmins, although for a time Buddhist priests contested their supremacy in this field. Medicine in ancient India was very highly respected, as may be judged by the saying that one of the fourteen precious objects which their gods are believed to have produced by churning the ocean was a learned physician. While the Brahmins themselves were philosophers and teachers, the actual practitioners of medicine were the Vaidyas or a sub-caste of the powerful and aristocratic Brahmins.

The teaching of the ancient Hindoos in anatomy and physiology shows that they were not accustomed to dissect the human body or those of animals. In their description of anatomy it is stated that the body contains 500 muscles, though only 490 in women, from 300 to 360 bones, twenty-four nerves and, of special interest to us, that the skin consisted of seven

Digitized by Google

layers or membranes. According to Wise,[20] the skin was supposed to be healthy when it was soft and had much hair.

"Hindu physiology," writes Garrison,[21] "presupposes that the vital processes are actuated by means of the air (below the navel), the bile (between the navel and heart) and the phlegm (above the heart) from which are derived the seven proximal principles chyle, blood, flesh, fat, bone, marrow and semen."

The ancient Hindoo conception of the cause of disease included many natural phenomena, such as exposure, climate, irregularity in food, exercise, etc., which were supposed to corrupt or derange the humors. They also thought that diseases could be caused by sins committed in the present or in a former life. Thus, one who killed a cow might suffer from lepra. A drunkard might be punished by a skin disease, and an incendiary by erysipelas, etc.

While we have seen that Egypt was the land of specialism in medicine often carried to an absurd extreme, the opposite condition prevailed among the ancient Hindoos. As Baas says, "Indian medical practice is distinguished from that of all other people of antiquity by the fact that it recognizes no proper specialties but simply physicians practicing general medicine." Though there were no skin specialists in ancient India, there evidently would have been plenty of occupation for such, had they existed. Many diseases of the skin are mentioned by the ancient Sanskrit writers, and this in spite of the strict regulations that were given concerning personal hygiene and diet. Such regulations involved a daily bath and inunctions with oil, especially about the head, ears and the soles of the feet. Their clothing had to be absolutely clean, as it was said that soiled clothes produced skin diseases. The nails, beard and hair were to be kept clean and cut every fifth day, etc.

---

20. Wise, T. A.: Review of the History of Medicine, London, 1867, p. 181.

21. Garrison, F. H.: An Introduction to the History of Medicine, Philadelphia and London, 1913, p. 50.

Digitized by Google

Of the many diseases described by the ancient Sanskrit writers, none is of greater interest to the dermatologist than leprosy, especially as the disease is now so prevalent and severe in Asia. The early descriptions of leprosy, as in every country, appear to have included other harmless diseases of the skin. According to Wise, the "Hindoos distinguished three kinds of leprosy, a black, white and red variety and eighteen forms; seven of those are severe in their nature and eleven are mild." One of these spurious varieties is evidently ichthyosis, in which the patient does not perspire and presents large, oblong patches like the scales of a fish, rough like the skin of an elephant and of a dark brown color. Portions of the description, however, point unquestionably to leprosy, such as the hands and feet becoming stiff, insensible, ulcerating and dropping off, the nose falling in, the eyes becoming red, and the voice unnatural and hoarse

In the differential diagnosis of leprosy, the modern physician would certainly excel his ancient Hindoo colleague, though in regard to treatment he would have little to suggest, except as to the benefits of segregation. What better advice could we give than that of the ancient physician who instructed his leprous patient to "bathe, to avoid wine and fatigue and to attend to diet, take a proper degree of exercise and wear clean clothes." Some of their medicines would not be considered so favorably, as, for instance, tumeric powder in cow's urine to be taken every day for one month. The seriousness of leprosy was recognized by the ancient Hindoo physician, who classified it among the seven diseases which had a bad prognosis.

The ancient Hindoo account of elephantiasis is short but unmistakable. To quote from Wise, "It is stated that damp and cold situations produce this disease, that it attacks different parts of the body, and that it

Digitized by Google

is incurable after it has remained upwards of a year, or is very large." We read of "small eruptions appearing upon the face at the time of puberty, produced by phlegm, wind and blood," evidently a description of acne. For dandruff, which is supposed to be due to deranged phlegm and wind, Susruta recommends bleeding, a rather heroic method of treatment. A remedy recommended by Chakradatta for a peculiar itching of the scrotum (possibly eczema) would not be suitable to an acute condition at least. This consists of sulphate of iron, concrete juice of the bile of the cow, sulphate of copper, sulphuret of arsenic and of antimony, to be made up in a paste with acid rice water. For the cure of external worms (pediculosis), fluid mercury is to be rubbed with sulphur until a homogeneous black mass is produced and rubbed over the affected part. Among other cutaneous affections described by the ancient Hindoo writers may be mentioned acne, boils, carbuncles, abscesses, alopecia, canities, erysipelas, urticaria, purpura, nevus, verruca, ulcers, diseases of the nails and chicken pox.

In the very extensive materia medica of the ancient Hindoos there were a good many remedies recommended which appear to us rather grotesque. Thus, it is hard to see any value in using the moisture contained in cow dung for inflammation and discoloration of the skin. On the other hand, the Hindoos deserve credit for having used arsenic not only in leprosy but also in other diseases affecting the skin. Mercury also, according to Royle,[22] appears to have been externally employed in the time of Pliny. Their external remedies included oils, plasters, poultices, baths, hot applications for inducing perspiration, fumigation for ulcers and skin diseases, and the cautery, both actual and potential.

Whatever opinion we may hold in regard to the medical knowledge of the ancient peoples of whom

22. Royle, J. F.: An Essay on the Antiquity of Hindoo Medicine, London, 1837, p. 45.

Digitized by Google

we have spoken, it must be admitted that the real foundations for the scientific study of medicine were laid by that remarkable race, the ancient Greeks, under the leadership of the immortal Hippocrates. Although himself a descendant of a long line of priest-physicians, Hippocrates (460-377 B. C.) was the first to separate medicine from religious superstitions and philosophical sophistries. He said that disease arose from natural causes and not from the anger of the gods. He was a great exponent of the vis medicatrix in advising us to "follow nature," and he recognized that accurate observation was necessary for all medical progress.

Without much knowledge of anatomy and little or none of physiology, it is hardly surprising that little progress was made by Hippocrates and his followers in ascertaining the essential nature of disease. Like the four elements, earth, air, fire and water, and the four qualities, heat, cold, moisture and dryness, there were supposed to be four cardinal fluids or humors in the body, the yellow bile, blood, mucus and black bile, in the order named. By a uniform mixture and adjustment of all of these, health was maintained. The basis of life was the innate heat, the evaporation of which caused death. The presence of air that was supposed to exist in the vessels was also considered essential to life. In a disease running a normal course, the process went through the stages of "crudity," "coction" and "crisis," the first being a degeneration of the fluids, the second a preparation stage for their removal and the third their actual removal.

In regard to the Hippocratic conception of skin diseases, it is not to be doubted, as Kaposi[23] has said, that certain affections were considered to be independent or idiopathic in their origin. Others were thought to consist of deposits on the skin (apostases) which resulted from certain morbid conditions of the humors within the body. In this sense the Hippocratic writers spoke of a skin disease as an eruption, a breaking

23. Kaposi, M.: Diseases of the Skin, New York, 1883, p. 3.

Digitized by Google

out or an efflorescence (exanthema). They looked on many diseases of the skin as curative attempts of nature which should not be disturbed, as otherwise the morbid condition might return inward or be "driven in," to use an expression that is frequently heard at the present day among the laity. While mainly considering skin diseases from the humoral-pathologic standpoint, Hippocrates also discussed the etiologic effect on them of age, sex, climate, seasons and even the weather.

As Rayer[24] says, Hippocrates "enquires into the symptoms of eruptions rather than attempts to describe them." Indeed, from his descriptions, it is difficult for us to judge of the original meaning of the terms, many of which are still in use in our dermatologic nomenclature. The form and color and certain features are often mentioned, but there are no exact descriptions of appearance and locality of skin disease.

In a critical study of the names of skin diseases used by Hippocratic writers, von Bärensprung says that the word "exanthemata" is used to refer without distinction to the "most diverse, acute, and chronic, itchy and non-itchy, dry and moist, flat and vesicular forms of eruption." Under this general conception are included three groups of disease. The first of these are the phymata, to which belong "all boils or tumors that rise upon or under the skin and gradually undergo suppuration." In this class are included furuncles (dothienes and terminthoi). The second group of diseases consists of the dry, scaly eruptions, the lopoi (from lopos the epidermis and lepo to scale). This includes lepra (which was doubtless psoriasis), lichen and pityriasis. A third group of exanthemata helchodea comprised the moist eruptions such as kerion, and achor, the moist eczema occurring in the scalp and face of children and eruptions consisting of vesicles or pustules (phlyctenai).

24. Rayer, P.: Treatise on the Diseases of the Skin, London, 1835, xxxv.

Digitized by Google

Attention is also called by von Bärensprung to the broad conception that was intended for the words "herpes" and "psora." Herpes referred to eruptions that gradually crawl or spread from a given point. One variety, herpes esthiomenos, appeared to be synonymous with phagedaina, a term with which we are all familiar. By psora was understood every pruritic eruption, whether dry or moist in character. Among other Greek names that are now in common use for skin diseases may be mentioned erysipelas, gangraina, petechia, ephelide, ecthyma and alopecia.

Among the famous aphorisms of Hippocrates which have been commented on by such a host of writers for the past 2,400 years may be mentioned several of dermatologic interest. Hippocrates says, for instance, "In dropsical persons, ulcers forming on the body are not easily healed," a statement with which all will agree. Again he says, "It is better not to apply any treatment in cases of occult cancer, for if treated the patients die quickly, but if not treated they hold out for a long time." Accepting the view of the ancient commentators that "occult" may mean deep seated, Adams[25] says that the conception of this aphorism will be that when cancer is superficial it can be removed by knife or cautery, but is best left alone when it is deep." In some of the aphorisms the meaning is not very clear, as in the statement that "broad exanthemata are not very itchy," or that "patients who have become bald are not subject to large varices, but should such varices supervene upon persons who are bald, their hair again grows thick."

One of the case histories of Hippocrates that is of interest to the dermatologist was that of a man who had suffered severely from general pruritus and thickening of the skin. Failing to obtain relief he went to the island of Melos where hot baths were to be found. We then read that he was cured of his pruritus and

25. Adams, F.: The Genuine Works of Hippocrates, New York, 1886, ii, 256.

Digitized by Google

thickening of the skin but unfortunately developed dropsy and died, a statement that illustrates the honesty of Hippocrates, in consequence of which he was spoken of by jealous rivals as a practitioner of the "medicine of death."

If the reputation of the ancient Romans depended on their medical instead of their military and political achievements, we would indeed have a poor opinion of their genius. There was no such thing as a Roman system of medicine, and, indeed, there were comparatively few Roman physicians. The practice of medicine was almost entirely in the hands of the Greeks, who were responsible for all scientific progress and most of the literature. Before the appearance of Greek physicians, the Romans, as Pliny says, had gotten along without physicians for six hundred years, relying on simple remedial herbs, charms, etc. In their superstitious effort to be protected from illness, they worshipped innumerable goddesses of disease, among them being a goddess of scabies.

The physicians of the early Romans were looked on with contempt, and were not even entitled to citizenship until the time of Julius Caesar. The prejudice against them, however, gradually lessened until they were finally accorded unusual privileges. "The honorarium of a physician," writes Baas, "for an ordinary visit amounted to about 29 cents," though Pliny mentions a high priced physician who was paid the equivalent of ten thousand dollars by Manlius Cornutus for relieving him of a skin disease. The medical profession in ancient Rome, it may be added, was not in any way responsible for the splendid achievements in hygiene, such as the building of great aqueducts, sewers and public baths, which were undertaken without their aid or advice.

While the practice of medicine, as has been said, was chiefly carried on by the Greeks, the best account of the art at that time was written by a Roman, Aulus

Digitized by Google

Cornelius Celsus[26] (25 B. C.-50 A. D.). In spite of his masterly descriptions of diseases, it is even doubtful whether Celsus was a physician. He certainly did not engage in practice for a livelihood. In addition to his work on medicine entitled "de re medica" and consisting of eight books, he was the author of treatises on agriculture, philosophy, jurisprudence and history. Though Celsus made no impression on his contemporaries or the medieval writers, his work on medicine was eventually appreciated and is the only part of his writings that has survived.

The work of Celsus is of special interest to the dermatologists on account of the comparative importance given to diseases of the skin. In the fifth book, twenty-eighth chapter, of his "de re medica," a number of diseases are described with considerable accuracy and can be easily identified. They include carbuncle, furuncle, carcinoma, phagedenic ulcer (therioma, corresponding to the herpes esthiomenos of the Greeks), scrofuloderma (phygethlon) abscess, fistula, kerion, warts (achrocordon and myrmecia) and corns. A few other diseases whose identity we can probably recognize were venereal warts (thymia), acne, pustules (phlyzakia), erythema multiforme (epinyktis) and anthrax (from a remark that certain cases of carbuncle are painless.)

The terms "impetigenes" and "papulae" included eczema, while "pustulae" referred not only to what we term pustules but also lesions of urticaria and miliaria. Scabies referred to various forms of eczema, and vitiligo included three affections, alphos, leuce and melas. Of these, alphos might have been guttate psoriasis from the description, which reads, "It is called alphos when it is white; it is commonly a little rough and not continued, but appears like drops dispersed here and there. Sometimes it spreads wider leaving some places between free."

26. Celsus, A. C.: Medicine in Eight Books, Trans. by Grive, London, 1838.

Digitized by Google

In his sixth book, Celsus describes various conditions of the hair and beard. He recommends frequent shaving for hair that falls after an illness, and adds with great truth that "no remedy whatever can prevent the heads of some people from becoming bald with age." The term "porrigo" was used for ordinary dandruff and probably eczema as well. The latter disease was also apparently included under the name "sycosis." Under the title of "area" is described alopecia areata, often spoken of as area Celsi. He writes that it is "almost folly" to cure freckles, "but it is impossible to prevent women from being nice in what regards their beauty." Other dermatologic affections that are described by Celsus include elephantiasis Graecorum, ulcers and burns, condyloma, varicose veins and gangrene.

Pliny the historian (23-79 A. D.) mentions several diseases that were not included by Celsus, among them being herpes zoster, which was described by Scribonius Largus under the title of Zona. Pliny also speaks of several unusual diseases, among them the cutaneous affection called mentagra, which some have erroneously considered to be syphilis. Caelius Aurelianus wrote about phtheiriasis and elephantiasis; while, according to Bloch,[27] who is our best dermatologic historian, the first accurate description of leprosy was written by Arataeus the Cappedocian (30-90 A. D.).

As the period of ancient history is considered to end with the fall of the Roman Empire in 476 A. D., it would hardly be proper to lengthen this address to include an account of the Byzantine and Arabian writers, who cannot strictly be classed among the ancients. It is sufficient to say that valuable contributions to dermatology were made by the Arabian physicians, especially in their account of leprosy and of elephantiasis. Rhazes (860-932) was the first to

27. Bloch, I.: Aufgaben und Ziele einer Geschichte der Hautkrankheiten im Altertum, Monatsh. f. prakt. Dermat., 1898, xxvii, 605.

Digitized by Google

accurately describe smallpox and measles. Avicenna and Haly Abbas wrote careful descriptions of diseases of the scalp, and Avenzoar is said to have discovered the parasitic cause of scabies.

In conclusion, I hope that I have shown that the study of the history of ancient medicine is not altogether a thankless or uninteresting task. I can merely add that I not only appreciate the honor of my position as chairman but also the opportunity it has afforded me for dermatologic studies of fascinating interest.

Digitized by Google

AN UNCOMMON CASE OF MULTIPLE BENIGN SARCOID OF THE SKIN

JOSEPH ZEISLER, M.D.
Professor of Dermatology, Northwestern University
CHICAGO

Etymologically the term "sarcoid" would seem to convey the conception of a tumor formation resembling sarcoma. It was first employed by Kaposi to comprise a number of cutaneous disorders, including mycosis fungoides, lymphodermia and even true sarcoma. Its more general and exact use dates from Boeck's publication in 1899. He there described as multiple benign sarcoid and later, in 1905, as benign miliary lupoid, cases presenting numerous deep-seated cutaneous nodules or tumor-like formations of varying size, situated on the face and other parts of the body, presenting a characteristic histologic picture and thought to be due to a modified effect of the tubercle bacillus.

Far from strengthening or clarifying this new clinical and pathologic entity, further observations have rather complicated the situation, not only in morphologic respect, but also in regard to the histology and etiology. Thus we find Darier in 1910 giving us four types of sarcoid, based on a careful analysis of about thirty-five cases, viz.:

1. Boeck's type: Tuberous, papular and diffuse infiltrating form.

2. Darier-Roussy type: Subcutaneous sarcoid, symmetrically distributed on the trunk, histologically resembling tuberculosis.

3. "Sarcoides noueuses et nodulaires," resembling erythema induratum.

Digitized by Google

4. Spiegler-Fendt type: Round cell, nontuberculous tumors.

Since 1910 there have been reported probably less than thirty cases.

Plancherel collected reports of twenty-two instances of sarcoid, of which fifteen were of Boeck's type, seven of the subcutaneous variety and of the erythema nodosum type. Sutton has recently reported an unusual case in a child 2½ years old, showing lesions on the face. At the last meeting of this Association Sweitzer[1] reported, together with a review of the whole subject, a case of supposedly typical Boeck's sarcoid. In view of this recent contribution, a detailed survey here of the literature would seem superfluous.

That many cases of sarcoid bear a more or less intimate relationship to tuberculosis must be admitted from a study of the material collected so far. But whether we should readily identify sarcoid and tuberculosis, as Fordyce recently suggested in a discussion before the American Dermatological Association, seems as yet open to debate. Let us briefly analyze the last twenty-eight cases reported. In five of them a family history of tuberculosis is recorded. Ten cases presented concomitant features of tuberculosis, such as iridocyclitis, glandular affections and other signs. Stümpke reported a case of sarcoid associated with generalized tuberculosis. Kyrle emphasizes the resemblance of the histologic picture in real tuberculosis of the skin to that of benign miliary lupoid. Tuberculin injections produced a general reaction in five, a local reaction in two cases. The Pirquet test proved positive in three instances. Animal inoculation, undertaken by various investigators, has in most instances given negative results, though Morovetz, Kyrle, Volk and Sweitzer report positive effects. In twelve cases careful searching for tubercle bacilli was unsuccessful. So were stains for Much's granules.

1. Sweitzer, S. E.: Sarcoid of Boeck, The Journal A. M. A., Sept. 19, 1914, p. 991.

Digitized by Google

Most of the cases of the erythema induratum type showed unmistakable evidences of their tuberculous nature.

These apparently divergent findings need not surprise us, when we look back at the history of lupus by way of analogy. Here also, in this classical form of cutaneous tuberculosis, as we regard it today, demonstration of bacilli is very difficult and if at all successful, only in very small numbers. Here, also, the subjects affected by it often enjoy robust health and present no vestige of other foci of tuberculosis. And it has taken many years of struggle to establish its etiologic position.

A somewhat different attitude may be justified as regards the supposed relationship of sarcoid to syphilis, which has been brought out by some recent observations. Ravaut reports two cases of angiolupoid, one of the patients giving a positive Wassermann, and both cured by salvarsan. Similar experiences are recorded by Brocq, Tzank and Pelbois. Pautrier noted the simultaneous occurrence of a serpiginous syphilid with a sarcoid tumor of the nose, clinically and histologically typical. The Wassermann was positive and both kinds of lesions responded to salvarsan. He also describes another case of ulcerative sarcoid of the Darier-Roussy type of the upper arm showing epithelioid cells, giant cells and lymphocytes histologically, which was eventually cured by injections of sodium benzoate. A similar observation was made by Plancherel. Pautrier insists on the necessity of revising the sarcoid group, and its division into two classes, the one belonging to the tuberculids, the other related to syphilis.

It may be permitted to point, in this connection, to the remarkable capacity of syphilis for imitating other well-defined clinical pictures. We know this to be true with reference to lichen planus, to lupus vulgaris and lupus erythematosus, to psoriasis, erythema induratum and many other diseases. On the other hand, it must

Digitized by Google

be insisted that a positive Wassermann and even response to salvarsan do not of necessity establish as syphilitic any lesion happening to be present on the skin. For a patient with latent syphilis may be yet capable of developing on the skin lesions which in themselves are not the products of syphilis. And salvarsan on account of its arsenical effects will often cure cutaneous disorders other than syphilis. It therefore seems not improbable that some cases reported as sarcoid do not really belong to that class. Similar errors are liable to occur, after all, in the case of any unusual dermatosis, for the human eye is not infallible, and even the microscope and the test tube do not protect us against errors. To establish finally the clinical and pathologic entity of a so-called new disease we must continue to study each case carefully and record our findings. It is to this end that the following report is here submitted.

REPORT OF CASE

History. — Giacomo F., aged 36, saloonkeeper, presented himself, Oct. 31, 1914, for examination, through the kindness of Dr. W. P. Curtis of Chicago. Patient was born in Italy, lived in Brazil from 1892 to 1897, when he came to this country. He has been married for ten months to an 18-year-old, perfectly healthy woman. A baby, 4 weeks old, is in every respect well. Patient had gonorrhea and soft chancres eighteen years ago, but no cutaneous eruption at the time. While in South America he had yellow fever. He has had sore throat repeatedly and has been treated for it with mercury and iodids. There is no evidence of tuberculosis in his family history.

Present Illness.—In May, 1914, he noticed a red spot on his left buttock, and on the following day a similar one appeared on his cheek, causing some itching and burning. At the same time he had a sore throat and a painful cord formed at the angle of the right jaw. New spots followed in rapid succession on the face, the arms, legs and the back, while the older ones became larger. He describes them as pinkish nodules or swellings of the skin. The family physician pronounced his case syphilis. Two salvarsan injections were given intravenously, followed by ten intramuscular injections of mercury with no improvement whatever, but a continued multiplication of the lesions. A Wassermann test made at

Digitized by Google

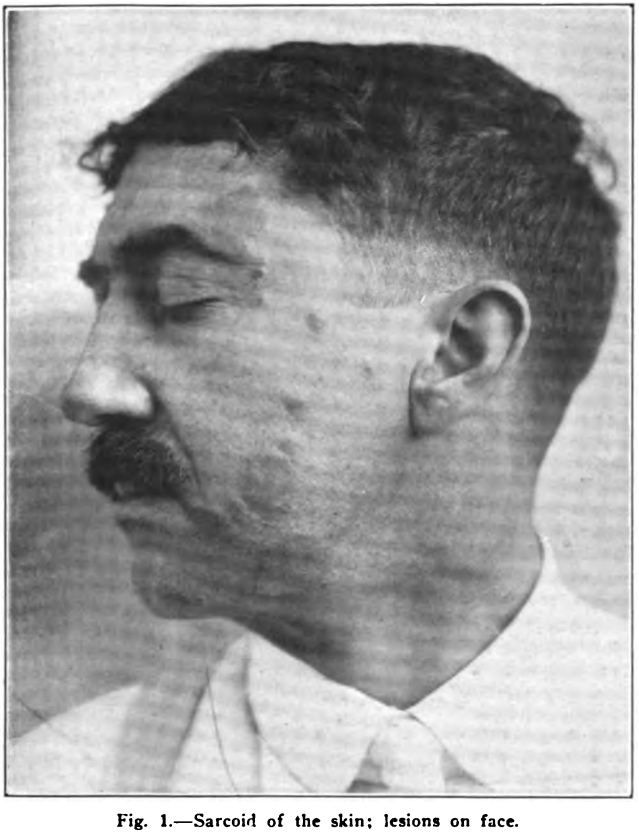

Fig. 1.—Sarcoid of the skin; lesions on face.

Digitized by Google

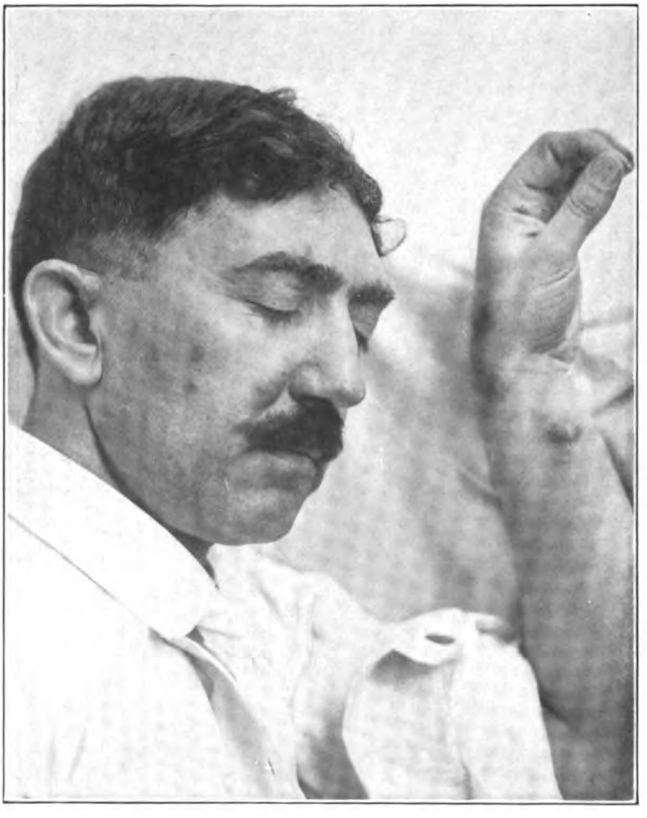

Fig. 2.—Sarcoid lesions on hand and face.

Digitized by Google

the beginning and again in August proved negative. The patient's general health has continued good and there has been no loss of weight. Appetite is good and bowels regular. Formerly a heavy drinker, he has become very temperate.

Examination.—Well-nourished man of short stature, weighing 136 pounds. There is an external strabismus of the left eye and a deformed iris due to an old injury. Careful exami-

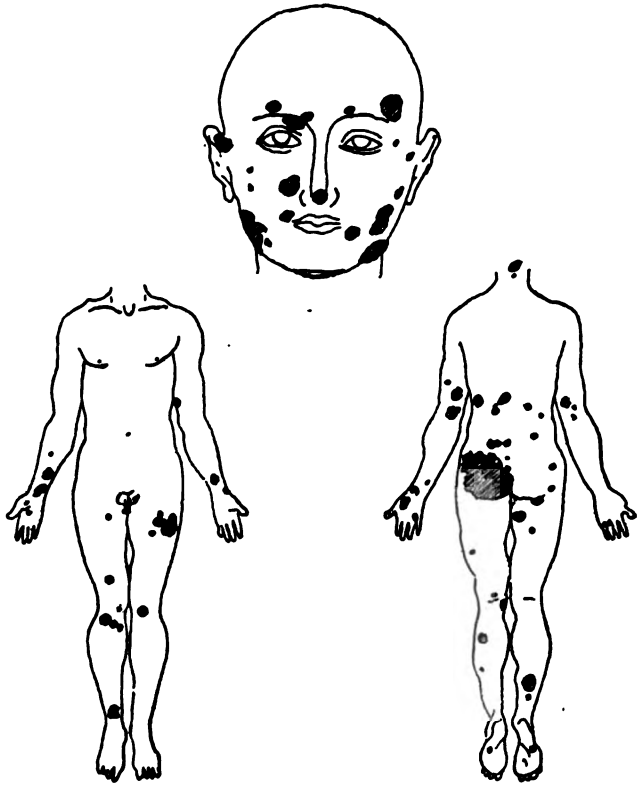

Fig. 3.—Distribution of sarcoid lesions on face and body.

nation of the chest and abdomen revealed nothing abnormal. The genitalia are normal with exception of very small meatus. The ulnar nerves show no enlargement at the cubital region. The knee reflexes are normal.

The urine shows a few shreds, a faint trace of albumin and microscopically a few hyaline casts and leukocytes.

Digitized by Google

A blood count made on two occasions showed: hemoglobin, 90; red blood cells, 5,250,000; leukocytes, 4,800; differential count: neutrophils, 62; small mononuclears, 30; large mononuclears, 5; eosinophils, 2; basophils, 1.

The mucous membranes are pale and free from any lesions. The tongue is moderately coated. The teeth are in good condition. At each angle of the jaw a hard subcutaneous cord is palpable, running in the direction of the sternomastoid. A few small movable cervical glands can be felt. The suboccipital glands are markedly enlarged. The axillary glands are barely noticeable. A distinctly enlarged cubital gland is present at the right elbow, none in the left. The inguinal glands are firm and bean-sized.

Cutaneous Manifestations.—The eruptive features present an unusual, almost grotesque picture. Their distribution may be best seen in the accompanying illustrations. The lesions on the face (Figs. 1 and 2) are sharply circumscribed nodules and infiltrated plaques varying in size from a split pea to a half dollar. They are brownish red in color, at times almost bluish red. Situated superficially, they are markedly raised above the level of the skin, easily movable, and of a tumor-like, firm consistence. Under glass pressure their color changes to a yellowish brown, and occasionally there can be seen miliary foci. A few of the lesions show fine telangiectases. There is no tendency to scaling. Chest, upper abdomen and shoulders are not invaded. In the lumbar regions are about ten round tumors, dark red, sharply demarcated and varying in size, from 0.5 to 3 cm., in diameter. The left gluteal region is almost totally occupied by an irregularly outlined plaque, whose borders show a distinct infiltrate, while the center is flattened, suggesting a peripherally progressing, somewhat serpiginous development. The color on the borders is dark red while the center is light brown. On the lower extremities are a few scattered symmetrical infiltrates of irregular contour, rather yellowish brown in color and lichenoid in type. On the sole of each foot is a small brownish nodule. Near the elbows and wrists of both arms several irregularly shaped plaques with raised borders and depressed centers. The back of the right hand shows some small infiltrates and two brownish nodules on the thenar eminence of the palm. There is one small lesion on the scrotum and several flat lichenoid efflorescences on the glans. Nowhere is any tendency to ulceration evidenced. The subjective features of the eruption are insignificant, but the cosmetic disturbance is greatly annoying to the patient.

Microscopic Study (Fig. 4).—Two lesions were excised from the back for purposes of histologic study and hardened in Zenker's fluid and formaldehyd solution. The sections were subjected to the usual stains, and in addition special stains for acid-fast bacilli were made.

Digitized by Google

The epidermis was unchanged except for a slight parakeratosis. The corium was occupied by infiltrated areas in the perivascular and perifollicular spaces. The infiltration was diffuse in some sections, more sharply demarcated into nodes in others, and extended down to the subcutaneous layer. The nodes were separated by connective tissue without evidence of inflammatory reaction. The infiltrates were composed of epithelioid cells, round cells and giant cells of the Langhans type. There were no evidences of caseation. The blood vessels showed varying degrees of endarteritis. Plasma cells were absent. The elastic tissue was thinned out. The glands were not affected. Numerous sections were stained for tubercle bacilli and Much's granules without success. The sections were submitted for inspection to Prof. Robert Zeit of the Northwestern University Medical School, who, without any reference to the clinical phases of the case, unhesitatingly pronounced them as presenting the picture of tuberculosis.

I desire here to express my sincere thanks to him for his kind interest.

Animal Inoculation.—Two guinea-pigs were inoculated with pieces of tissue from the tumors, one subcutaneously and one intraperitoneally. Three months later both pigs were necropsied and found to be perfectly healthy.

Tuberculin and Luetin Tests.—The Pirquet and Moro tests were negative. The luetin test was also negative. No reaction was obtained from 0.5 mg. of Koch's O. T.; 2 mg. caused a rise of temperature to 99 degrees, general reaction with headache and malaise but no local reaction in the lesions themselves.

Much of the work above recorded was done by my son, Dr. Erwin P. Zeisler, to whom I desire here to give credit due him.

Diagnosis.—At first sight the cutaneous picture seemed so unusual that, while sarcoid was at once suggested, a careful differential diagnosis became important. Syphilis, for which the patient had been treated, could be excluded without difficulty, not merely through the negative Wassermann and the lack of response to specific medication. The protuberant lesions, if syphilitic, would have to be addressed as gummas; as such they would show a tendency to break down and ulcerate. The large flat plaque on the left buttock (Fig. 5) was entirely foreign to the usual appearance of syphilitic lesions. Nothing in the history of the case pointed to that diagnosis. The freedom of the mucous membranes and the healthy condition of the baby were further arguments against it.

Lepra was considered on account of the patient's sojourn for a long time in South America. The absence of the char-

Digitized by Google

acteristic leonine facial expression, thickened ulnar nerves, anesthetic areas, any tendency to ulceration and bacilli in the sections seemed sufficient to dispose of that possibility.

Lupus does not appear at so late a period in life, in such rapid development, or in the form of such large flat plaques as in this case, and only rarely in such large numbers of lesions on the body.

Mycosis fungoides, also, develops much more slowly, usually after a long period of precursory phenomena, shows great tendency to breaking down of the lesions, general cachexia with itching and burning of the skin and a progressiveness which was markedly lacking here.

Lymphodermia could be excluded on the ground of the blood count. Against generalized sarcomatosis speaks the distinctly benign character of the affection.

Further observation of the case for a period of many months strengthened in every way the original diagnosis of multiple benign sarcoid.

Treatment.—A variety of measures, both local and constitutional, were employed in the treatment of the patient.

Roentgen rays were used over many of the lesions, and while there resulted a marked reaction, the effect seemed slight and nowhere was there a complete involution.

Mercurial plaster and various salves made little impression.

Freezing with carbon dioxid snow, which was practiced on a number of the tuberous lesions, caused a violent reaction, followed by an almost complete disappearance of the same.

Radium was consistently applied to a few selected small tumors, with moderately beneficial effect.

Arsenic was employed both internally and by way of injection. At first elarson was used in large doses for several weeks; then Fowler's solution in increasing strength, both without much apparent benefit. Only the intravenous injection of sodium cacodylate, used in weekly intervals for several months, seemed beneficial. But while the patient at the present time (June 1, 1915) is greatly improved, particularly as far as the facial appearance is concerned, he seems far from a perfect recovery.

The case was presented before the Chicago Dermatological Society at its annual meeting last January, where the unusual picture was commented on and the diagnosis concurred in by most of the members.

32 North Michigan Avenue.

ABSTRACT OF DISCUSSION

Dr. Richard L. Sutton, Kansas City, Mo.: A few years ago I had an opportunity to make a differential study of Boeck's sarcoid and subcutaneous tuberculosis. In addition

Digitized by Google

Fig. 4.—Section of sarcoid lesion; from photomicrograph.

Digitized by Google

Fig. 5.--Sarcoid lesions on buttocks.

Digitized by Google

to sections from my own cases, Dr. Udo J. Wile was kind enough to loan specimens from three cases of Boeck's sarcoid which had previously been studied by Dr. George Henry Fox and himself, and Dr. Wende's preparations from his rare case of nodular tuberculosis of the hypoderm. At that time I concluded that the disorders which Darier has placed in the so-called "Sarcoid Group" may be separated into two distinct groups; (1) true sarcoids: Boeck; Spiegler-Fendt; (2) subcutaneous tuberculosis: Darier-Roussy; Wende. The first two are probably separate and distinct diseases; the last two are probably identical, and bear no relation whatever to the true sarcoids. Therapeutically, true sarcoids respond favorably and fairly promptly to arsenic, a drug which has little or no effect on tuberculous lesions. I think those two facts alone separate and identify them from the tuberculosis group.

Digitized by Google

THE MANAGEMENT OF BURNS

A. RAVOGLI, M.D.
CINCINNATI

To attempt to establish a line of management of all burns *a priori* is somewhat preposterous. Following the doctrines of Hebra, and accepting his division of burns into three degrees, we find that the pathologic process in each is different. In burns of the first and second degree there is an inflammatory reaction of the skin, while in the third degree there is primary necrosis. The degree of the burn, the medium producing the burn, the depth of the injury in the tissues, the extent of skin burned and the condition of the nervous system of the patient, all influence the treatment of such important injuries. In general we can state that the best treatment is that which favors the sloughing of the burned skin, which maintains the sterility of the resulting wound and promotes granulation and the newly forming epidermis, so that a regular soft cicatrix may be obtained.

A burn is always a serious injury in view of the resulting shock, and of the action of poisonous substances arising from the burned skin. The treatment of the local lesion is only a part of that necessary, for the results on the general system have to be taken under consideration.

In 1902 I reported 88 cases of burns, of which 56 were in men and 32 in women.

The burns seen in that year were: of the first degree, 8; second degree, 54; of the third degree, 26.

The results of that year were: recovery in 61; death in 24, while 3 left the hospital.

Digitized by Google

Last year we had 49 cases of burns: in men, 34; in women, 7; in children, 8.

The results were: of the 34 men, 32 recovered, 2 died. Of the 7 women, 5 recovered, 2 died. Of the 8 children, 6 recovered, 2 died.

In severe burns the patients when taken to the hospital are greatly excited, crying and screaming with pain. As soon as the wounds are dressed and the patient is placed in bed an injection of morphin, ¼ grain, produces quiet. Some so regain their normal power as to furnish details of the accident and ask questions about their relatives. After a severe burn, the patients as a rule do not void urine, and when they do it is scanty and contains either blood or a quantity of albumin.

A woman suffering from a slight epileptic attack fell while carrying a coal-oil lamp, her clothes being set on fire. When taken to the hospital nearly two thirds of the body was burned to a crisp, from the feet to the chest. Both legs were just baked, the whole surface brown, hard and insensible (Fig. 1). She received an injection of morphin, ¼ grain, and was placed in a water bed in which a handful of sodium borate had been dissolved to remove the burned clothes adherent to the skin. After cleansing the burned surface she was placed in bed, and compresses were applied moistened with a 2 per cent. solution of aluminum subacetate. The patient lay in apathy and began to vomit bilious and bloody matter. This continued for two days. The urine was scanty and contained albumin. The following day she received a subcutaneous injection of normal salt solution, and also strychnin, 1/30 grain. The stupor passed away and the pulse improved considerably. She lived twenty-four days. The eschar was detaching, but it was a difficult matter to remove it, because the muscles were becoming detached and exhaling an offensive odor. The patient grew very weak, became delirious, fell into stupor and died.

Digitized by Google

Death was due to sepsis. Although the action of the fire or of different mediums at an elevated temperature is limited to the skin, yet general disease follows. The burn has a remarkable influence on the organism. The severe symptoms following an extensive burn of the skin are in relation with the entity of the lesion. At times, even in consequence of an apparently light combustion, severe symptoms endanger the life of the patient. For this reason the burns have a general as well as a local treatment.

The treatment of burns[1] by forcibly removing the burned skin and deep blisters is risky, unnecessary, and will not accomplish the purpose. This was proposed by Sneve[2] and summarized by W. A. Jack, Jr.,[3] and Brazer[4] recommended that as much as possible of the burned skin be removed, and the surface then washed with gasoline, while Lieber,[5] advocating the same process, advises washing the bleeding surface with benzin. Although this operation is carried on under an anesthetic, and is followed by an injection of morphin, it is to be avoided. The shock is so severe that the patient may not recover from it.

According to my experience, time is necessary to give the burned tissues a chance to detach from the normal nonburned structures. Even in the second-degree burns, when large blisters are formed, it is better to puncture the blisters in several places to allow the serum to exude, leaving the old epidermis for some time to cover and protect the denuded papillae of the derma. Some blisters are superficial, the serum is contained only in the stratum corneum, and when punctured the whole contents ooze out. Other blisters are deep, they affect the entire thickness of the

1. The Treatment of Burns, New York Med. Jour., March 14, 1914, p. 541.
2. Sneve, Haldor: Treatment of Burns, The Journal A. M. A., July 1, 1905, p. 1.
3. Jack, W. A., Jr.: Washington Med. Ann., May, 1912.
4. Brazer, Louis: New York Med. Jour., Aug. 2, 1913.
5. Lieber, M.: Beitr. z. klin. Chir., 1912, lxxxi; Die Verbrennungen und ihre Behandlung, Dermat. Wchnschr., 1913, No. 23, p. 657.

Digitized by Google

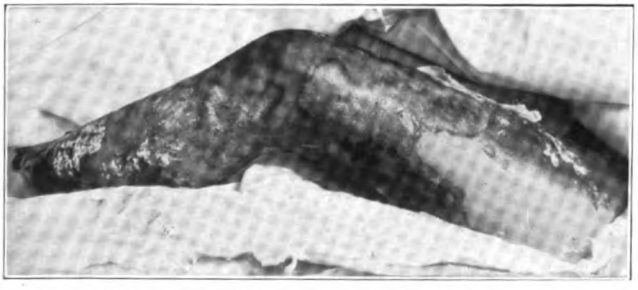

Fig. 1.—Burn of third degree. Leg baked. Surface hard and insensible.

Fig. 2.—Burn of third degree caused by flame. Skin dark brown and dry like leather.

Digitized by Google



Fig. 3.—Section of burned skin. From photomicrograph. Epidermis missing; no papillary layer. Lymph spaces filled with coagulated albuminous matter. Blood vessels shown as streaks of dark granules, the upper surface infiltrated with black granules. Collagenous tissues hardened and shrunk.

Digitized by Google



Fig. 4.—Same burn shown in Figure 2, one week later.

Digitized by Google

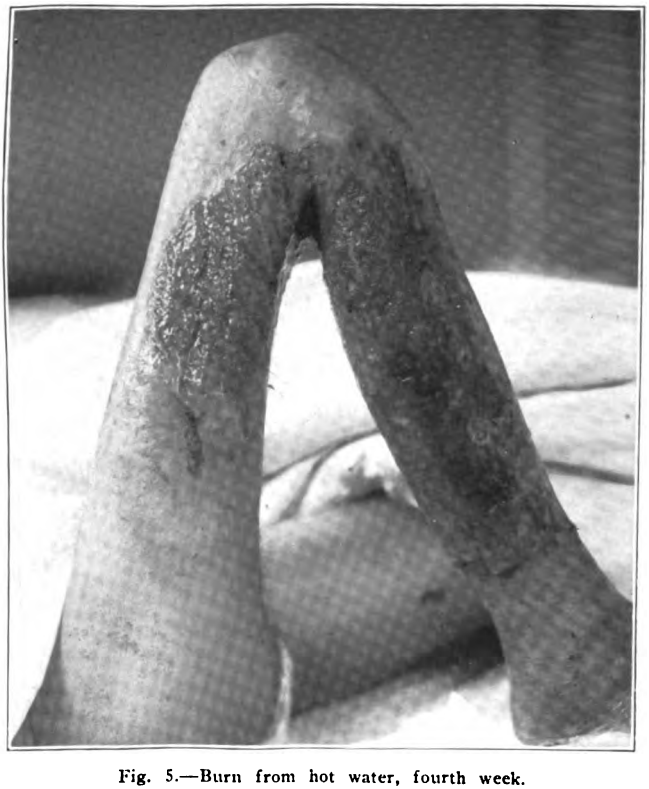

Fig. 5.—Burn from hot water, fourth week.

Digitized by Google

Fig. 6.—Burn of second degree. One week after occurrence.



Fig. 7.—Burn of third degree. Four weeks required for full recovery.

Digitized by Google

Digitized by Google

corpus mucosum, and when opened very little or no serum escapes. The corpus mucosum is thick and has the appearance of grayish pulp.

The histologic changes of the skin in a second-degree burn are characterized by an enlargement of the papillae, enlargement and congestion of the capillary blood vessels, swelling and infiltration of the collagenous tissues of the derma. The corpus mucosum is swollen, and a layer of small leukocytes lies on the papillae and beneath the epidermis, which forms the vault of the bulla. According to Kaposi[6] the papillae appear like a reticular tissue whose meshes contain serum and white cells, epithelium and fibrinous masses. The blister, either breaking of itself by the pressure of the serum or artificially broken, undergoes a regressive process. When exposed to the air the cuticle dries up, the fibrinous contents form a thick crust under which the epithelium is reproduced, which covers the papillae. When a deep blister is opened the disorganized tissues of the mucous layer gradually slough off. The inflammatory process diminishes in intensity, the epithelial cells underneath become more coherent, cover the papillae and form a new epithelial layer which completes the epidermization without leaving a scar.

The burns at the time they occur cause great pain; a few hours later fever follows. In the same way when the burned tissues begin to slough off, a high temperature shows the general systemic reaction. Although a second degree burn is not so dangerous, yet, according to the extension and the age of the patient, it can have fatal results.

In a third degree burn the skin has been disorganized; there is mortification of the tissues. The eschar involves the derma, and may reach to the subcutaneous tissue. When the skin has been burned to such a degree by flame it appears dark brown (Fig. 2) and dry like leather; when burned by steam at high pres-

6. Kaposi, M.: Pathologie et traitement des maladies de la peau, translation by Besnier and Dayon, Paris, 1891, i, 492.

Digitized by Google

sure, it looks white like marble, hard and coriaceous, and is insensible to the touch. In the skin so burned the blood circulation is destroyed, and the vitality also. Together with the disorganization of the skin (Fig. 3), coagulation and decomposition of the proteic substances takes place. The products of the disorganized albuminous tissues then arising from the burned skin are poisonous and according to Ferrarini[7] cause the systemic symptoms, and even death. Spietschka[8] found that these poisonous elements are excreted by the kidneys. The urines of men and of animals affected with extended burns are poisonous. To the coagulated albuminous matters and to the burned blood corpuscles these poisonous elements may be traced.

In the beginning it is difficult to establish whether a burn is of the second or of the third degree, especially when it has been produced by steam. After two or three days the burned skin assumes a dead appearance, and at the edges the elimination process begins, separating the burned from the healthy skin.

Figure 2 shows a third degree burn, caused by flame. It was taken the second day after the occurrence. The skin is baked brown, dry and hard, and is insensible to the touch. The whole surface is swollen; in some parts the cuticle has been removed, in others it is forming blisters. It was treated with continuous moist compresses with 2 per cent. solution of aluminum subacetate. Figure 4 shows the same burn one week later. Toward the periphery where the blisters were situated the epidermization is well advanced. Where the eschar sloughed out the granulations are forming. In the center where the burn was still deeper, the eschar is still hanging on. The eschar is removed without forcing, the shreds which are detached are

7. Ferrarini, Guido: Die toxische Lehre in der Pathogenese des Verbrennungstodes, Dermat. Wchnschr., 1913, No. 12, p. 335.

8. Spietschka: Ueber verbrennungen und Verbrennungstod, Arch. f. Dermat. u. Syph., ciii, Nos. 1 to 3.

Digitized by Google

seized with a thumb forceps and taken off with scissors. In this way we avoid pain, and still better, the bleeding. When the blood vessels are broken the door is opened for infection. The burned skin in the tissues is so adherent that it is impossible to remove it without producing trauma.

Nature removes the burned from the healthy tissues, and it is our duty to help this process and not to disturb it. In many cases when we believe we have a very deep eschar we are surprised in a few days to see that the shreds of burned skin are sloughed off and there remains underneath a clean healthy granulating surface, which soon shows islands of epithelium and in a short time heals. The elimination of the eschar begins between the third and the fifth day. An inflammatory process starts around the eschar by way of a groove which separates it from the healthy tissues. The separation is effected in from eight to twelve days. The resulting granulating wound has an uneven bottom and irregular edges, on account of the irregularity of the mortification of the tissues. After the elimination of the disorganized tissues, abundant granulations come up to replace the loss of substance of the skin. From the edges of the granulating wounds the epithelium is concentrically reformed and, furthermore, islands of epithelium appear in a round form in different places in the middle and these, gradually growing, peripherically cover the newly formed tissues. This is the process of cicatrization. Scar substitutes the lost skin; it has no papillae and no hair follicles. The difficulty of the cicatrization is the reproduction of the horny layer. The granulations sometimes are irregular, luxurious and abundant, and if not watched and kept under control, the resulting scar may become irregular, uneven, inelastic, contracted, distorted, protuberant and disfiguring. Figure 5 shows a burn of the leg and thigh, which came under my service twenty

Digitized by Google

days after the occurrence. The patient had remained in his house treating himself. It was covered with crusts and was infected with *Bacillus pyocyaneus*. The dressing in a few hours turned blue. Compresses moist with 1:2,000 solution of mercuric chlorid cleared the surface of infection. In figures 6 and 7 burns of both hands and feet of the second and third degree are well illustrated. On the hands deep blisters formed, which in a few days were removed and in a short time the burn healed. It took nearly two weeks for the eschar to slough off the feet with a third degree burn, and nearly four weeks for complete recovery.

LOCAL TREATMENT

In a first degree burn the application of dry powders such as talcum powder, bismuth, or alum is the best treatment. Rosslenger[9] has already recommended the exclusion of salves and of baths in these burns in order to avoid maceration and excoriations of the epidermis, which often constitute open doors for infection. In case of severe pain I recommend application of compresses moistened with a solution of aluminum subacetate of from 2 to 5 per cent., which will calm the burning pain. As soon as the patient is eased the dry powder is applied. In a few days the redness and swelling disappears, and under a superficial desquamation the skin returns to its normal condition.

In second degree burns I apply moist compresses of a solution of aluminum subacetate. When the blisters are distended with serum they are opened, draining the fluid and leaving the epidermis in place to protect the denuded papillary layer.

The application of compresses moistened with a 1 per cent. solution of picric acid has been highly recommended, especially by Boland[10] of Atlanta, Ga., and a

9. Rosslenger: Die erste Behandlung bei Verbrennungen und Verbruhungen, Intern. Med. Kong. in Wien, September, 1892.
10. Boland, Frank K.: New York Med. Jour., Aug. 2, 1913.

Digitized by Google

3:4,000 solution of potassium permanganate has been recommended by Beck.[11] In my service I could find no advantage that the picric acid or potassium permanganate had over the aluminum subacetate. It has been found disagreeable to handle on account of the staining. Compresses of sterile gauze are applied on the burned surface and kept continually moist with the aluminum solution, and the whole is bound with a piece of oiled silk, so cut as to hold the dressing in place.

Oily substances as carron oil, oleum lini and aqua calcis, so much recommended by Kaposi[6] and Wertheimer,[12] according to our experience must be avoided. We must agree with Verney[13] that carron oil in many cases is dangerous, on account of infecting wounds.

When the shreds of epidermis forming the blisters are easily detached all are cut off by means of a pair of scissors and a thumb forceps and the whole surface is gradually cleared. The papillae are already covered by a newly formed epithelium, the surface is red, and a little oozing can be noticed. At this point the Sneve[2] treatment, exposing the surface to plain air is very useful. In the beginning the patient complains of the burning and wishes to have it covered, but after a while he does not experience much discomfort. The surface is left exposed to the air for one hour at first, later for two or three hours. The surface is then dusted with powder and covered with sterile gauze. A second degree burn can recover in the course of one week or ten days. Some little points may remain which ooze and granulate; these may be touched up with 3 per cent. nitrate of silver, and to prevent the formation of crusts at night can be covered with 2 per cent. boric acid in petrolatum.

---

11. Beck: Treatment of Severe Burns in Children, Therap. Monatsh., No. 8, 1913.
12. Wertheimer: Zur Behandlung der Verbrennungen in Kinderalter, München. med. Wchnschr., 1892, No. 31.
13. Verney, A. E.: Ueber Behandlungen von Brandwunden, Deutsch. med. Ztg., No. 100, 1894.

Digitized by Google

The treatment for a third degree burn is nearly the same, I mostly use compresses moistened with aluminum subacetate solution for the purpose of softening the eschar and helping the process of elimination. In the skin burned to the third degree, there is no more life, no more circulation, the proteid elements are decomposed, and it has to be eliminated from the living tissues. This is done by nature herself. Between the third and the fifth day a groove is formed by inflammatory process around the eschar which is gently detached, and gradually eliminated. With scissors I cut away all the shreds of the eschar which hang on the surface, without forcing. When the eschars are removed by force the tissues tear and bleeding follows. Bleeding means the opening of the blood vessels, and causing them to absorb the putrid material, which is derived from the burned tissues which form the eschar. This is the time when the patient has more intense fever due to the entrance of the poisonous substances into the system. When fever is high and pus is formed on the surface, compresses moistened with 1:2,000 solution of mercuric chlorid have given me the most satisfactory results.

When the eschar has been completely eliminated, the resulting wound is rose red, clean, and slightly uneven on account of the different depths of the burn. On the whole surface healthy granulations form a substitute for the lost skin. From the epidermis at the edges an epidermic layer gradually tends to cover the granulating surface as a whitish thin cover. In different places in the center of the granulating wound, islands of epidermis are seen, which look like epidermic grafts, and, in a round shape, keep reforming the epidermic layer. We believe with Hebra and Kaposi that these epithelial islands are the results of preexisting epithelium emanating from portions of the mucous layer, or from hair follicles which escaped destruction.

Digitized by Google

Recovery is therefore obtained through cicatrization, from newly formed connective tissue in which papillae, hair and glands are missing, and which is covered by a thin, slowly produced epidermis.

In order not to disturb the process of epidermization, the Sneve method is useful. It has been pointed out that the direct application of the gauze on the granulating area tends to delay the healing of the burns. The adhesion of the gauze to the surface has been considered as interrupting the process of repair, and as causing unnecessary pain and drain of nervous energy each time that the dressing is removed.

As I have already said, the exposing of the granulating wound to clean plain air is advisable at this time, and the surface is improved by its drying action. So long as parts of the eschar, necrotic particles and infectious detritus are still on the surface, moist dressings with mercuric chlorid must be used, in order to clean the surface and favor their sloughing off.

The open-air treatment and the direct application of the sun's rays to ulcers and wounds has been advised for many years. Recently attention was called to this by Wagner[14] and Oscar Barnard,[15] the latter claiming it to be a disinfecting and a healing power. In minor burns, open-air treatment had been used by W. P. Copeland[16] protecting the wound by means of a pasteboard box, and by Reid,[17] who protected the surface with a wire cage. As stated, we expose the granulating surface to the air only for a certain time, from one to three hours. More than that inconveniences the patient, the secretion begins to form crusts, and we prefer to cover the surface again after this length of exposure.

---

14. Wagner, H.: Quoted by Sneve, Note 2, Zentralbl. f. Chir., December, 1903.
15. Barnard, Oscar: München. med. Wchnschr., Jan. 5, 1904, quoted by Sneve, Note 2.
16. Copeland, W. P.: New York Med. Rec., 1887, quoted by Sneve, Note 2.
17. Reid, G. Archdall: Lancet, London, March, 1898, quoted by Sneve, Note 2.

Digitized by Google

It seems that the plain air acts by stimulating the granulating surface from which clear serum is oozing. The serum dries up when exposed to the air and forms an homogeneous film, which covers the granulating papillae. From the edges the epithelial cells underneath keep extending their whitish layer which covers the granulating surface. When exposed directly to the sunlight the action is much stronger, and if the surface is not sterile, vesicles are formed at the edges, which easily break and form crusts which are soon removed with compresses moistened in a 1:2,000 solution of mercuric chlorid.

It must not be forgotten that the granulations need to be touched with a solution of silver nitrate every other day to prevent irregular, or keloidal scar. The wound after being exposed for from two to three hours, must be covered with a suitable dressing as 2 per cent. borated petrolatum on English lint. When the granulations are pale and show a tendency to the formation of pus the application of a mixture of castor oil and Peruvian balsam also gives good results. This dressing, however, cannot be used for a long time on account of producing irritation. Kuss[18] advocates covering the burned surface with a piece of caoutchouc paper as a protective, cut exactly to fit the wound, having holes to drain the serum, and allowing moistening in salt solution. This is covered with patches of gauze also moistened with salt solution. When a burn involves a joint, the scar has to be watched so that it does not cause contracture of the limb. The fingers, eyelids, and lips, must be kept separated with lint, so that no adhesions may occur.

In a burned area of a large size, without a tendency to the formation of epidermis, a few grafts of epidermis after the method of Reverdin will help to produce the epidermization.

18. Kuss, Georges: The Treatment of Burns, Med. Standard, April, 1914, No. 4, p. 137.

Digitized by Google

SYSTEMIC TREATMENT

An extensive burn, no matter of what degree, causes always a general systemic reaction. In the beginning the patient may suffer primarily from the shock. Klauder[19] calls attention to this condition, and advises injections of morphin or strychnin in the very beginning to prevent this condition. In my service cases of shock have been rare. More often I have seen gastroduodenal ulceration, with continuous vomiting, sometimes nephritis, and pneumonia. In nephritis the intravenous injection of Fisher's solution with the internal administration of digitalis has greatly helped, and in a few days the urine was clear of albumin. The fever following the burn rises and falls somewhat resembling that of typhoid fever. In all my cases the administration of chinin has been very beneficial, and I consider it one of the most useful antiseptics. Gradually as the patient improves, when the fever is gone, a substantial diet must be given with some tonic iron preparation to improve the general condition of the patient.

ABSTRACT OF DISCUSSION

Dr. W. A. Pusey, Chicago: It is not my experience to see many cases of burns, but I have a strong impression that burns are not, as a rule, well treated. I think the most useful part of Dr. Ravogli's paper is that in which he emphasizes the value of wet dressings, and particularly of wet dressings of aluminum acetate solution. There is, I believe, an open field for the writing of a book on "old and useful remedies which have been forgotten." In that book I would put among the first subjects aluminum acetate solution, with which dermatologists are all familiar, but whose value is apparently unknown to the great majority of the profession. If Dr. Ravogli's paper does no more than call to the attention of the profession the value of dilute aluminum acetate solution as a bland antiseptic dressing it will have served an excellent purpose.

Dr. Joseph Zeisler, Chicago: In the case of a burn we should always endeavor to make a prognosis at the beginning. People easily misjudge the nature and the importance of

19. Klauder, Joseph V.: New York Med. Jour., Aug. 2, 1913.

Digitized by Google

burns from the local evidence presented. I have seen severe burns in which I pronounced a fatal ending in a few hours or days, when the parents of the patient were utterly amazed. When they looked at the skin and failed to see blisters or injuries, they could not understand that it was a serious case. The general public does not know of the apparently harmless appearance of the skin in burns of the third degree. In one case in which a child was burned by a gasoline fire, the skin had a peculiarly waxen appearance; and the parents did not realize the serious case they had before them until the child died.

Dr. Ernest Dwight Chipman, San Francisco: I would like to amplify the remarks of Dr. Pusey concerning the application of wet dressings. There comes a time in the treatment of most, or many burns—as in cases of some eczemas—when the particular therapeutic indication is for something slightly astringent and something which promotes epidermization. In some cases an application of acetate of aluminum is excellent, but I like better a 1 or 2 per cent. aqueous solution of resorcin or salicylic acid. Resorcin is my favorite. Its effect many times is magical.

Dr. A. Ravogli, Cincinnati: I thank Dr. Pusey for his remarks on the utility of the acetate of aluminum solution, which I prefer to any other thing, on account of its action. It quiets the pain, diminishes the hyperemia and does not give any trouble through discoloration, such as occurs with picric acid and permanganate of potassium, which have no other beneficial effect than to soil the clothes and the attendant's hands. Early prognosis is extremely interesting, as Dr. Zeisler has said. I have seen cases in which it was thought the patient would rapidly recover, but he died, and vice versa. In the matter of resorcin, I prefer mercuric chlorid for this reason: I have shown the illustration of a leg and thigh burned after twenty days which came under my service, and when the patient was taken to the hospital the lesion was infected with the *Bacillus pyocyaneus*. I must say I am afraid of *Bacillus pyocyaneus*. The use of mercuric chlorid 1 or 2 per thousand by continuous bathing I think is the best way to get rid of the *Bacillus pyocyaneus*. The Sneve treatment is very good. Expose the resulting wound, when granulating, to the plain air for one hour, and no more, as after one hour the patient feels such discomfort that he cannot stand any more; for this reason very seldom do I extend that to two or three hours. In the same way I use the direct rays of the sun. I treated a case of very severe burn in a boy of 12 with a large granulating surface infected with pus germs; the exposure to the sun had an antiseptic effect on that suppurating surface and epidermization began. But the boy could stand hardly one hour's exposure to the rays of the sun.

Digitized by Google

SYMPTOMATOLOGY AND TREATMENT OF SOME COMMON PALMAR ERUPTIONS

RICHARD L. SUTTON, M.D.
KANSAS CITY, MO.

The cutaneous disorders which commonly involve the palms and soles are relatively few in number. Aside from eczema, the dry syphilodermas, particularly the tubercular and papulosquamous varieties, are probably the most frequent offenders. In both eczema and syphilis the palmar involvement may be dependent on the generalized distribution of the eruption, but in the later stages of both diseases the cutaneous manifestations are frequently confined to the flexor surface of the hands.

Of the palmar eruptions which are directly or indirectly due to the action of pyogenic organisms, infectious eczematoid dermatitis is the commonest, although dermatitis repens, including the acrodermatitis perstans of Hallopeau, is not unusual, and during the past year I have encountered three cases of granuloma pyogenicum in this region.

Of the various forms of dermatitis which may affect the palms as a result of the action of external irritants, that due to liquor formaldehydi is in my experience the most frequent. It is especially common in laboratory workers and in embalmers, although surgeons and their assistants are often attacked. In chronic radiodermatitis, the lesions are usually confined to the dorsal surface of the hands and fingers, but occasionally, as in two cases that have recently been under my care, the palms also may be affected.

Digitized by Google

There appears to be a generally accepted belief that psoriasis often involves the palms alone, and that when the lesions develop in this region they always display the peculiar and striking appearance that is so characteristic of psoriatic eruptions on other parts of the body. In reality, the disease seldom if ever occurs solely on the flexor surfaces of the hands, and in suspected cases which present no evidence of the malady elsewhere, the probability of a diagnosis of psoriasis may safely be ignored.

In generalized cases of icthyosis, the palms and soles are seldom markedly affected. In symmetrical keratodermia of the extremities (keratosis palmaris et plantaris hereditaria), a disorder which is sometimes referred to as "icthyosis palmaris et plantaris," the epidermal thickening is limited strictly to the flexor surfaces of the hands and feet, and is probably trophic in origin. Heredity is an important factor in many instances.

Seborrheic dermatitis of the palms is usually secondary to the disease on the scalp and in the sternal and interscapular regions, a fact which Unna pointed out in his original description of the malady, and which has more recently been emphasized by Stelwagon and others. Aside from the superficial character of the eruption, the manifestations often bear a striking resemblance to those of lues, and inasmuch as the lesions are often mixed in character, in borderline cases it is sometimes necessary to resort to laboratory tests before a definite conclusion can be reached. Of the various aids at our disposal, Wassermann's serum reaction is probably the most popular, with histopathologic examinations of biopsied tissue second, and Noguchi's luetin test third. The latter is a convenient and inexpensive method, and in my hands has proved reliable and trustworthy, particularly in the old and neglected cases of syphilis which commonly give rise to dry, scaly eruptions of the palms.

Digitized by Google

In the Southern States, pompholyx is a comparatively common disorder, and, as a rule, involves the flexor surface of the hands, and the sides of the fingers.

Of the somewhat rarer maladies, one example each of pityriasis rubra pilaris and keratosis follicularis have been included for purposes of comparison.

The general characteristics of the various types can best be illustrated by means of the accompanying photographs and case histories.

CASE 1.—Recurrent, papulovesicular eczema of the palms and fingers in a girl, aged 15. The disease had been present at intervals for more than three years. The lesions began as reddish, intensely itchy macules, and papules and vesicles quickly followed. New lesions usually developed as rapidly as the old ones disappeared, and an attack generally lasted two or three months. There was very little thickening or fissuring, but always more or less moisture. Severe itching and burning were frequently present, particularly if the hands were allowed to come in contact with soap and water.

CASE 2.—This represents a rather uncommon variety of squamous eczema of the hands. The patient was a stenographer, aged 34, an exceedingly "high-strung" woman who for many years had been subject to outbreaks of eczema of the so-called "flexural type." The palmar integument was only slightly thickened, but was dry, inelastic, scaly and fissured. The eruption was fairly symmetrical, and had been present fourteen months. The pruritus at times was intense, and there was some accompanying burning pain.

CASES 3, 4, 5 and 6.—These are illustrative of a fairly common type of chronic eczema of the palms. All of the patients were adults, between the fifth and seventh decades of life, and in every instance the disease had been present for more than one year. The affected skin was thick, horny, inelastic and fissured. There was very little itching, but the fissures, which were arranged longitudinally on the palms and transversely on the flexor surface of the fingers, were at times exceedingly painful and troublesome. The frequent use of soap and water invariably renders the condition worse. Exposure to other external irritants appears to play but little part in the causation of this type of eczema. Case 3 occurred in a minister of the gospel, Case 4 in a physician, Case 5 in a semiretired housewife, and Case 6 in a wholesale liquor dealer.

Digitized by Google

Histologically, one finds the papillary hypertrophy with capillary dilatation and perivascular cellular infiltration, acanthosis and parakeratosis which are characteristic of chronic eczema no matter where it may be located.

CASE 7.—This may be considered as a borderline case, presenting features of both chronic eczema and seborrheic dermatitis. The patient was a physician, aged 51 years, and the malady had first appeared three years prior to the date of consultation. Both palms were affected. The skin was thickened, but was fairly flexible, and there was no fissuring. Below the thenar eminence on the left hand was a large, deep-seated vesicle which had been ruptured and from which some sticky fluid exuded. Aside from the itchiness in the vicinity of this lesion, there were no subjective symptoms. The skin on the anterior half of the palm and on the flexor surface of the fingers was slightly thicker than normal, and was smooth and glossy. The Wassermann reaction was negative.

CASE 8.—This represents a chronic inflammatory disorder which, for lack of a more appropriate diagnosis, I have placed with the seborrheides. During the past year I have seen two cases of this type, one in a woman of 30, the wife of a physician, the other in a traveling salesman, aged 36. In both instances only the palms were affected, and the disease had been present for several years. The skin was of a yellowish, resinlike color, glossy and fairly smooth. The thickening was uniform throughout, and scaling practically absent. The entire flexor surface of both hands was involved, and the inflammatory process was sharply limited to these areas, except at the wrist, where the eruption extended slightly beyond the palmar margin. The affected skin was dry, and had never been moist or vesicular. The woman was the mother of two healthy young children. The man claimed to be free from syphilis, and there was no reaction to luetin. Unfortunately, neither patient was willing to submit to a biopsy, and no tissue was secured.

CASE 9.—This is a fairly representative one of psoriasis of the palms. There were accompanying lesions on the elbows and knees. The patient was a boy, aged 16, and the disease had been present five and one-half years. The integument was uniformly thickened, and dark red in color. There was very little fissuring, although movement was considerably impaired. The scaling was comparatively slight. As in all psoriatic eruptions, the lesions were dry, and subjective symptoms were practically absent.

CASE 10.—Keratosis palmaris et plantaris hereditaria. The patient was a young man, aged 20. The disease had existed

Digitized by Google

for four generations on his mother's side of the family. Both the palms and the soles were affected. No other part of the body was involved. The skin was dry, horny and keratotic, and its natural lines greatly exaggerated. Owing to the lack of flexibility and elasticity, fissuring was not infrequent, the resulting lesions being very tender and painful.

CASE 11.—A pioneer roentgenologist failed to appreciate the danger associated with his specialty until he had incurred lasting injuries of both hands. The dorsal surface was the seat of numerous keratoses, several of which have recently become malignant. The palms were less seriously affected, although they too presented characteristic evidence of long-continued actinic irritation. The skin was dry, thickened and inelastic. In addition to the score or more of keratoses present, there was a small, prickle-cell carcinoma in the center of the left palm. Histologically, the smaller lesions were precancerous in character, and the malignant growth exhibited the vascular changes and hyperkeratinization which are typical of growths of this type.

CASE 12.—This is a representative one of infectious eczematoid dermatitis affecting the palm. The disease began with a paronychia which involved the nail of the left forefinger and had been present five weeks. The skin surrounding the individual pustules was reddened and inflamed. The outer corneous layers were undermined with pus. Pure cultures of the *Staphylococcus albus* were secured from several fresh, unruptured lesions. Histologically, the papillae were swollen, edematous and infiltrated, and the interpapillary vessels dilated. There was a considerable degree of acanthosis present, but no pus collections in the rete. The destructive process was limited to the structures overlying the stratum lucidum, the superficial corneous layers being elevated, frayed and broken.

CASE 13.—The flexor surface of the hands is a favored site for the lesions of dermatitis repens, mainly because of the thick, tough, resistant character of the horny layer in this locality. In this instance the attack followed a slight infected wound of the hand, and ultimately involved the entire cutaneous covering of the base of the thumb. Pathologically, the process is somewhat allied to that occurring in infectious eczematoid dermatitis, but in dermatitis repens it is much more deeply seated, and numerous abscesses are found throughout the prickle layer in the affected areas. In this disease also, the yellow or white staphylococcus is the offending organism.

CASE 14.—Granuloma pyogenicum of the palm I formerly considered of rather unusual occurrence. Like many other supposedly rare conditions, however, its true nature is often unrecognized. In the present instance the little tumor, which was cherry-sized, bright red, and bled freely on the slightest

Digitized by Google

provocation, developed following a puncture wound of the left thumb. It had been present three months, and had been subjected to many and diverse methods of treatment when the accompanying photograph was taken. Histologically, the growth consists of granulation tissue, and is more suggestive of an angioma than of anything else.

Of the various palmar syphilids, only a few types will be considered.

CASE 16.—This represents a macular eruption of the palms occurring as part of a generalized efflorescence at this stage of the disease. The lesions are dusky red, erythematous macules, distributed with a fair degree of symmetry, and give rise to no subjective symptoms.

CASE 17.—In this case, a syphilid of the maculopapular type, the lesions are more sharply defined, and when viewed at an obtuse angle they appear distinctly elevated. In reality, owing to the thickness and density of the overlying stratum corneum, the surface of the skin is perfectly smooth.

CASE 18.—This is of the large lenticular papular type, and the eruption on the palms consists of round-topped, ham-colored tubercles, from the summits of which the outermost layers of the epidermis have exfoliated.

CASES 19 and 20.—These represent early and late examples of secondary syphilis in which there is an intermixed seborrheic element. The surface of the skin is smooth and glossy, and the amount of scaling comparatively slight.

CASES 21 and 22.—These two examples also are suggestive of seborrheic dermatitis, but the segmental and circinate outlines of the lesions, the fact that they are deeply infiltrated, and that in each instance only one hand is involved, all are indicative of lues.

CASES 23 to 27.—These are illustrative of the later stages of syphilis. It is exceedingly probable that trauma is an important factor in the localization of many of these lesions. Of the five illustrative cases, all occurred in right-handed individuals, and in every instance this hand was the one affected. From eczematous eruptions the lesions are to be differentiated by their unilateral distribution and peculiar configuration, their reddish, beefy color, their history, and the absence of itching. Should any doubt exist regarding the true nature of the eruption, recourse should be had to a serum or a luetin test.

Pompholyx is so common and distinctive a disorder that little space need be allotted to it here. The acute onset of the disorder, the symmetrical distribution of

Digitized by Google

Fig. 1 (Case 1).—Recurrent papulovesicular eczema of the palms, with slight scaling and exfoliation.

Fig. 2 (Case 2).—Squamous eczema of the palms and flexor surface of the fingers.

Digitized by Google

Fig. 3 (Case 8).—Seborrheic dermatitis of the palm.

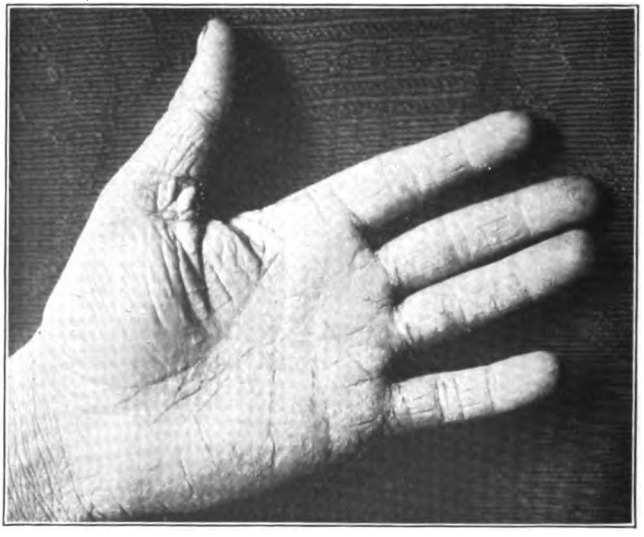

Fig. 4 (Case 9).—Psoriasis of the palm of five and one-half years' duration.

Digitized by Google

Fig. 5 (Case 10).—Condition of palm in a case of keratosis palmaris et plantaris hereditaria.

Fig. 6 (Case 11).—Keratoses on the palm due to the long continued action of the Roentgen rays.

Digitized by Google

Fig. 7 (Case 12).—Infectious eczematoid dermatitis of the palm.

Fig. 8 (Case 13).—Infectious eczematoid dermatitis, showing papillary enlargement, with congestion, acanthosis, and corneous exfoliation (moderate magnification).

Digitized by Google

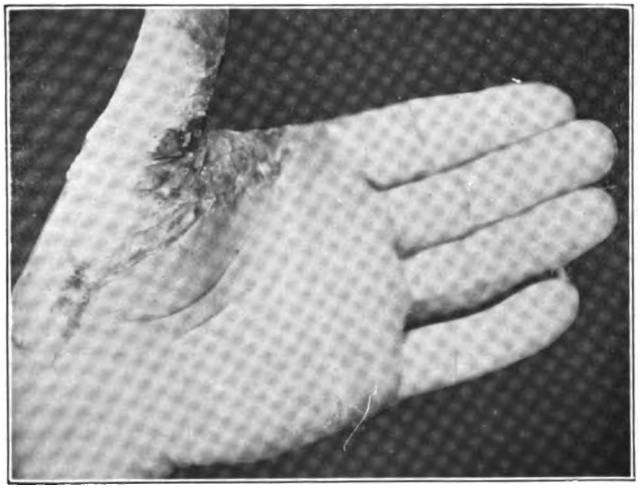

Fig. 9 (Case 14).—Dermatitis repens involving the palm. A portion of the corneous collaret has been clipped away.

Digitized by Google

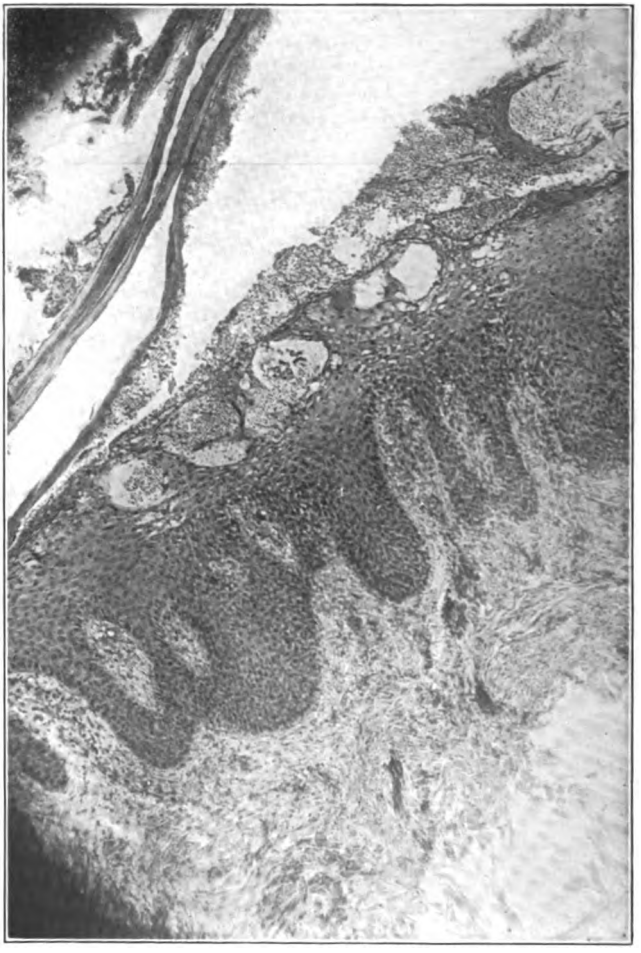

Fig. 10 (Case 14).—Dermatitis repens, showing papillary enlargement, and infiltration, with acanthosis and the formation of numerous minute abscesses in prickle layer, and exfoliation of the entire horny layer (moderate magnification).

Digitized by Google

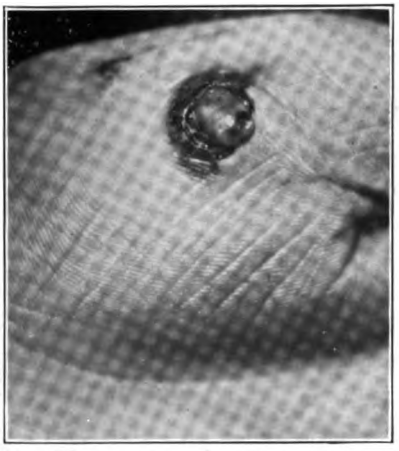

Fig. 11 (Case 15).—Granuloma pyogenicum of the palm of three months' duration.

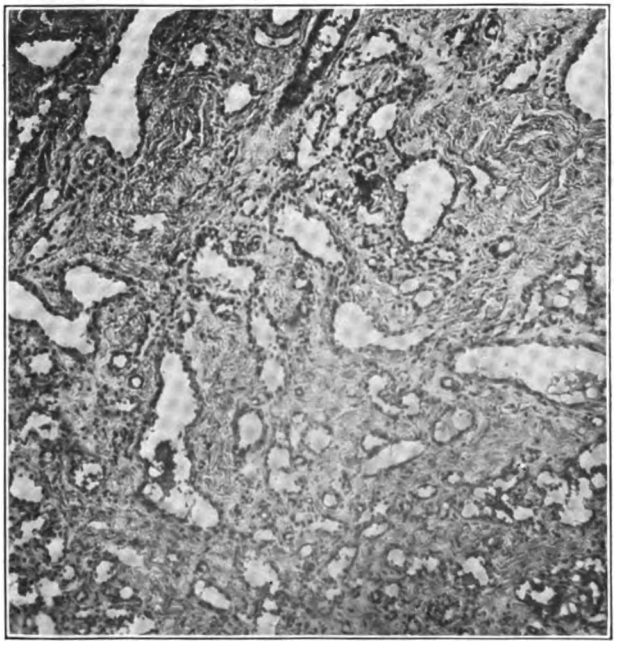

Fig. 12 (Case 15).—Illustration of characteristic histopathology of pyogenicum (moderate magnification).

Digitized by Google

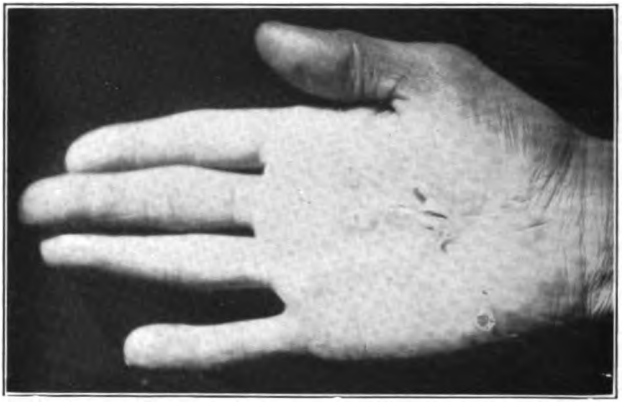

Fig. 13 (Case 18).—Late papular syphilid of the palm, with exfoliation of superficial corneous layer.

Fig. 14 (Case 21).—Segmental and circinate squamous syphilids of the palm (the so-called "psoriasiform syphilid").

Digitized by Google

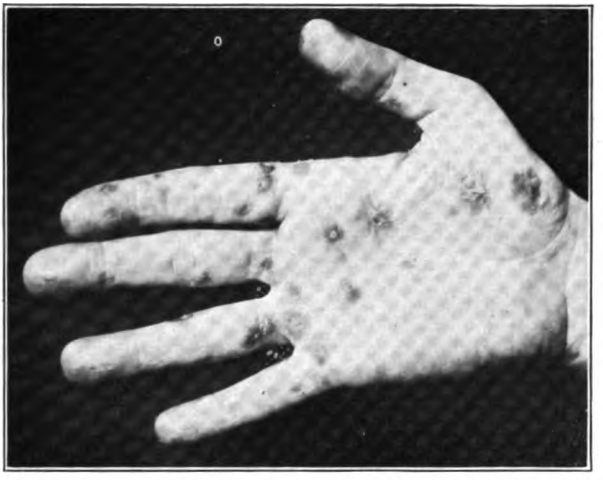

Fig. 15 (Case 29).—Pompholyx, showing pigmentation of the affected areas.

Fig. 16 (Case 31).—Keratosis follicularis, showing arrangement of corneous layer at the orifice of a coil gland duct (moderate magnification).

Digitized by Google

Digitized by Google

the lesions, and their self-limited duration are usually sufficient for differentiation. Only two examples, both of which were somewhat unusual, will be discussed.

CASE 28.—In the first, the eruption on the hands was practically confined to a small area (measuring about 5 by 7 cm.), in the center of each palm.

CASE 29.—In this case the palmar lesions were not hemorrhagic, but on healing they left sharply defined patches of pigment which persisted for some weeks.

CASE 30.—In pityriasis rubra pilaris, palmar manifestations, if present, are usually but a part of the generalized eruption. Instead of the small, acuminate, spinous projections which are characteristic of the disease on other parts of the body, however, here the integument sometimes assumes a peculiar, pig-skin-like appearance which is very striking.

CASE 31.—It is not unusual to find the palms and soles involved in extensive cases of keratosis follicularis. Instances in which the disorder is confined to one or more of these regions are comparatively rare, however; and for this reason the accompanying photograph and section are of interest. Only the flexor surfaces of the hands were involved. The disease had been present fifteen years (the patient was a man, aged 46). Superficially, the surface had the appearance of a target that had been peppered with birdshot. There was but little associated keratodermia. Subjective symptoms were absent.

The general plan of treatment for the various conditions that have been discussed may be briefly summarized as follows:

In actively inflamed lesions, soothing applications, such as carbolized calamine lotion and zinc-oil, should be employed at first, to be followed, if necessary, by the use of local stimulants (particularly those containing tar). Soap and water are to be avoided. In chronic eczema of the palms, recourse must often be had to the more powerful keratolytics and reducing agents. Of the various chemical keratolytics, salicylic acid (in strengths of from 5 to 20 per cent.) is one of the most efficient and reliable. It may be advantageously prescribed alone or combined with green soap, in the form of a plaster, or in an ointment. Of the commoner tar preparations, oleum rusci (oil

Digitized by Google

of white birch) is superior to oleum cadini (oil of cade). It is best employed in ointment mixtures, and in strengths of from 8 to 20 per cent. Radiotherapy often proves valuable in combating this type of the disease, and if the affected areas are not too large, radium also may be employed with benefit. In a few instances in which the latter agent was used, I have noted improvement even on untreated surfaces. The cases were very intractable ones, the lesions having failed to respond to numerous other therapeutic measures, and it is difficult to account for their sudden disappearance unless it was due to the action of the mineral.

In infectious eczematoid dermatitis, the lesions usually respond promptly and favorably to a 5 per cent. ammoniated mercury ointment. Dermatitis repens is much more rebellious, however, owing to the deep-seated character of the abscesses. The frayed and undermined corneous collar should be trimmed away, and Ruggles' mixture (salicylic acid 2 parts, tannic acid 10 parts, and alcohol 88 parts) applied freely several times daily. Occasionally a saturated aqueous solution of pyoktanin blue proves serviceable. In many instances it will be found necessary to resort to the use of autogenous vaccines before the progress of the disease is checked.

After a thorough trial of all the various methods that have been suggested for the eradication of the growths in granuloma pyogenicum, I believe thorough congelation with Pusey's carbon dioxid snow to be the best. The top of the lesion is clipped off, and the base frozen for a period of at least one minute. Afterward the part is painted with tincture of iodin, and a thymol iodid dressing applied.

Syphilitic eruptions of the palm generally require very little local treatment, although the liberal employment of a calomel (10 per cent.) or ammoniated mercury (10 per cent.) ointment will hasten

Digitized by Google

their disappearance. Of the various constitutional remedies, I have found injections of mercury salicylate, in the following mixture, superior to all others:

	Gm. or c.c.	
℞ Mercury salicylate.....	2	gr. xxx
Anesthesin	2	gr. xxx
Lanolin	4	ʒ i
Olive Oil.....q. s. ad	30	℥ i

M. Sig.: Shake and inject 10 or more drops into the gluteal muscles, twice weekly. The dose should be gradually increased until the physiologic effect is secured. Occasionally it is advisable to administer sodium iodid at the same time, but in the majority of instances the mercurial preparation is all that is required.

ABSTRACT OF DISCUSSION

Dr. A. Ravogli, Cincinnati: I congratulate Dr. Sutton on the beautiful demonstration he has given to us; and I can only say that some of his first cases in which he showed an eczematous condition of the hand, resembled some of my cases, which I found in my practice stubborn to treatment. I succeeded in finding the tricophyton, and by constant applications of Wilkinson's ointment I obtained results in about eight, ten or twelve days. From the frequency of these cases affecting mostly the palms, I concluded that inoculation could have occurred, the tricophyton being communicated by hanging on to the straps in a street car. Since then I consider dangerous taking hold of the straps in the street car, because of the possible presence of *Tricophyton tonsurans.*

Dr. W. A. Pusey, Chicago: Dr. Ravogli anticipated my thought on the subject of tricophyton of the palm. I have had it brought home to me that tricophyton palmus cannot be neglected by us; and in such a group of cases as this, I believe the occurrence of tricophyton or polycyclic patches on the hand, as determined by ringworm, must be thought of. I venture to call attention to the remedy I have been using in these cases: I have employed with great advantage 2 per cent. iodin in benzoin. It seemed to me to be a remedy of sufficient value to deserve attention. I got that from Dr. Politzer. I wondered why Dr. Sutton did not resort to cold in the treatment of this trouble with the hands, but I leave that to the discussion of our San Francisco colleague.

Dr. Howard Morrow, San Francisco: I would like to call attention to the importance of the clinical diagnosis of palmar syphilis. Dr. Sutton spoke of the advantage of the Wassermann reaction, but frequently we find cases of syphilis of the palms with characteristic location and color in which there is a negative Wassermann reaction. These must be put on specific treatment, notwithstanding the complement fixation.

Digitized by Google

Dr. Ernest Dwight Chipman, San Francisco: The set of photographs shown by Dr. Sutton, served to corroborate a pet theory of my own in establishing a differential diagnosis between an eczematous condition of the palm and late tubercular syphiloderms. It has been my observation that the latter nearly always begin in the very center of the palm and spread peripherally. Very frequently they are limited to the palm itself, and do not extend to the fingers, while eczematous lesions begin on any portion of the palm and are definitely inclined to spread to wrist or fingers.

Dr. Douglass W. Montgomery, San Francisco: Lesions of the palm are among the most stubborn we have to deal with, and yet we dermatologists have to proceed against them particularly, because they refuse to yield to the measures adopted by the general practitioner. The treatment of chronic eczema of the palms has recently been considered by Dr. Culver. We have found the Roentgen ray an admirable aid in the treatment, and we think, as Dr. Sutton says, that it tends to prevent recurrences. This is interesting as indicating a possible connection between hyperhidrosis and the persistence of inflammatory lesions of the palms. We are inclined to the belief that hyperhidrosis of the palms is present often when it does not appear as such, as in many cases the sweat may diffuse itself in the rough thickened horny layer before reaching the surface. The Roentgen ray we know controls sweating, and it may in this way influence the dependent lesion both as regards its cure and also in regard to the permanence of its cure.

Dr. Howard Fox, New York: I agree with Dr. Sutton in regard to psoriasis of the palms. I do not see how it is possible to make a diagnosis of psoriasis of the palms when there are no accompanying lesions on the rest of the body. I also do not see how psoriasis and eczema of the palms can be distinguished. Dr. Sutton spoke of the late syphilids on the right palm. They are not all on the right palm as the photographs exhibited will show. It is quite possible, of course, that some of these persons in whom the lesions occurred on the left palms, were left handed. The old rule that a squamous eruption on one palm is syphilitic, on both palms eczematous, holds good in about nine out of ten cases. One of the diseases of the palms in which serious mistakes in diagnosis are sometimes made, is a form of erythema multiforme. In this disease the eruption occasionally consists of discrete macular and maculopapular lesions on the palms which closely resemble a secondary syphilid. When such an eruption is also accompanied by lesions in the mouth of bullous erythema multiforme the similarity to syphilis is even more marked.

Dr. Everett S. Lain, Oklahoma City: I have met with some puzzling cases of sweating and disease of the palms.

Digitized by Google

Dr. Sutton has only touched on this subject, and yet he has given a rather elaborate review on this point. There are so many of these eruptions, and many different varieties, and we treat them differently. Some yield nicely to treatment and some do not. There are cases in which you feel that the diagnosis is the same and yet the same treatment does not apply. The same is true of all other forms of eczema. My experience in this class of cases with Roentgen ray coincides with the experience of Dr. Montgomery, namely, that in such eruptions as those in which we have hyperhidrosis, eczema will follow. In fact I have made a rule to predict an eczema of the palms when I have seen patients who have a continuously cold, sweaty hand. In this type the Roentgen ray has given very satisfactory results; also in the weeping or moist hands or palms. In the dry, squamous type, however, I have not found the Roentgen ray so successful. It perhaps serves as an aid, but I have learned to use it almost entirely now with the moist types of these eruptions. In the dry scaly types we depend more on the stimulating ointments such as Dr. Sutton mentions.

Dr. A. J. Markley, Denver: During the past few years I have been struck by the frequency with which the late lesions of syphilis occur on the palms alone. Within the past few months several cases have come under my notice in which there was no history of previous eruptions, and yet definite evidence of lues in the palms. This location furnishes frequent evidence of latent syphilis, and we should carefully examine the palms more often than we do.

Dr. J. C. Pickett, San Francisco: I wish to mention two cases of ringworm of the hand which I have seen in the last few months. One was on the hand of a woman. The lesions extended from the fingers to the palm and originated from scratching between the toes where the original lesion was found. In the second case the lesion began on the index finger and extended to the palm. In this case the infection was also transferred by scratching, the original lesion being around the anus.

Dr. George D. Culver, San Francisco: I should like to ask Dr. Sutton to elaborate on his preference for salicylate of mercury over salvarsan for palmar syphilids. I have been led to believe that the use of salvarsan in the cases of doubtful palmar lesions is of the greatest diagnostic value. In my experience many of the doubtful cases have cleared up after one dose of salvarsan even when there was a negative Wassermann. None of the palmar syphilids have failed to yield to this remedy.

Dr. Richard L. Sutton, Kansas City, Mo.: With regard to palmar tricophytosis, the condition must be a somewhat rare one. Up to the present I have never encountered a case in America or elsewhere. Dr. Morrow is undoubtedly correct

Digitized by Google

in regard to the fallibility of the serum test in some cases of palmar syphilis. In many instances both the histology and the laboratory findings are negative, and resort must be had to a so-called therapeutic test. In my experience salvarsan, even though administered intramuscularly (a method which is far superior to the intravenous), has proved inferior to the salicylate injections in eradicating tubercular syphilodermas of the palms. Dr. Montgomery's suggestion with respect to the occurrence of hyperhidrosis in the hyperkeratotic cases is illuminative and worthy of further study and investigation. I agree with Dr. Lain that the moist cases respond more satisfactorily to Roentgen therapy than do the dry types. I believe that the point made by Dr. Chipman is a valuable one, particularly with reference to the late, tubercular and gummatous varieties of syphilis. For further information on the histopathology of pompholyx, I would respectfully refer Dr. Pusey to a paper which was read before this section at the Minneapolis meeting in 1913.

Digitized by Google

LUPUS ERYTHEMATOSUS OF THE MUCOUS MEMBRANES

GEORGE D. CULVER, M.D.
SAN FRANCISCO

The cutaneous lesions of lupus erythematosus are so deforming that they occupy the attention of both the physician and the patient to the exclusion of the manifestations of the disease on the mucous membranes. Furthermore, the lesions on the mucous membranes, although generally erosions, and therefore raw surfaces, do not usually give the same discomfort as do, for instance, herpes or mucous patches, and the patient rarely draws the physician's attention to them. They are important, however, as giving one an insight into the nature of the disease as being something more than a mere local cutaneous affection, and they are also important because it is occasionally necessary to differentiate them from other affections of the mucous membranes, especially those occasioned by syphilis. The following eleven cases show lupus erythematosus in seventeen locations on the mucous membranes:

Case 1.—A woman, aged 38, consulted me, July 23, 1909, on account of a lupus erythematosus that had appeared three years previously over the right malar eminence, and that had disappeared, leaving only a slight capillary dilatation but no scar. Just below this, however, there was a scar, the result of another eruptive patch. Other patches had appeared over the frontal eminences and had vanished, leaving almost no trace.

When she consulted me there were six patches on the face, one on the vermilion border of each lip, and two in the right cheek pouch and one in the left. The lesion on the nose was fungating and bled easily; the others were bright red, of irregular shape, and were level with the surface. Besides

Digitized by Google

this the face was mottled with a dirty yellow pigmentation, and she looked in wretched health. The two red superficial erosions in the right cheek pouch and the one in the left were persistent, and at times they became very red and angry looking.

Two months before consulting me she had had a severe carbuncle on the right temple, showing she was subject to streptococcic invasion. Furthermore, shortly before, a baby had scratched her under the right eye, making a wound which was a number of months in healing. There was a history of much tuberculosis in the family, although her immediate relatives, such as her father, mother and sister, were not affected with this disease.

Her tongue had a thick, grayish-yellow coating, and there was some indican in the urine. She slept wretchedly and she suffered from cold hands and feet. For months before the eruption appeared and during pregnancy, she used to take milk excessively: two quarts at night, and large quantities during the day, to the exclusion of almost all other food.

Case 2.—A religieuse, aged 26, consulted me, May 8, 1912, on account of a most extensive and severe lupus erythematosus of the sides of the nose and of the cheeks. The scarring was typical. She said that three and one-half years previously two scaly spots had appeared, one on each side of the cutaneous surface of the upper lip. After this an eruption broke out on the inside of the upper lip, forming a running sore. The lip was then so out of shape that she could not speak, and the gums had a white coating.

When she came in, the inside of the upper lip was red and inflamed, the gums were retracted in some situations, redundant in others, and gingivitis was present. The lower lip was prominent, bright red, injected, and frequently had the appearance described by William Dubreuilh[1] of being coated with collodion. During the exacerbations of the lupus erythematosus, of which she had many, the lips, especially the lower one, burned and became intensely inflamed. The exacerbations were intimately associated with disturbances in the general health. At such times the mucous glands emptying on the inner surface of the lower lip swelled and became prominent as rounded elevations. At times a herpetic eruption resembling "cold sores" appeared in this situation, and the gums would redden and feel "feverish." Occasionally raised red blotches appeared on the mucous membranes of the lips. When the blotches were examined with a lens they showed a beautifully characteristic structure. They were about 0.5 cm. in diameter and slightly raised in a pincushion form. There was a central erosion, and the rounded border was convergingly striped with bright red capillaries. The epithelium covering this border was faintly

1. Dubreuilh, William: Ann. de dermat. et de syph., 1901, ii, 231.

Digitized by Google

opalescent. At one time, Feb. 19, 1914, there were three such lesions, each about 0.5 cm. in diameter, on the red of the upper lip, and one on the lower.

This patient was an irregular, rapid eater. She took much sweet food, potato and cheese. She had a heavily coated tongue and suffered from marked gastro-intestinal symptoms, such as flatulence and distention after eating, sour stomach and constipation. At times she had a ravenous appetite. She also had occasional right-sided headache. The conjunctivae were frequently yellow. As is common in gastro-intestinal intoxication, the whole cutaneous surface was congested with blood. Whenever the general health deteriorated the lesions became much worse. For instance, when she tried to keep Lent, it reacted very badly on her general health and on the lupus erythematosus. The edges of the eyelids were red and sore, resembling blepharitis marginalis.

April 14, 1914, on being examined the mouth revealed three lesions in the right cheek pouch, and one in the left. These did not cause discomfort. In each of them there was a bright red central line, surrounded by an opalescent area, which in turn was situated in a bright red field. All these lesions were above the interdental lines and were not near any roughened harsh surface, as roughened or sharp-edged teeth, such as might have caused an erosion.

The patient told me that at one time it was thought she had tuberculosis. I never found evidence to that effect while she was under my observation.

Case 3.—An unmarried nurse, aged 42, consulted me, Jan. 29, 1914, for an eruption which had appeared one year before, following sunburn at the seashore at Santa Cruz. There was an irregular light red telangiectatic patch on the left cheek; an irregularly contoured, light red desquamative patch that included the chin and lips and that contained many milia-like bodies; some irregularly contoured, light red, desquamative patches on the right cheek near the eye, and two patches near the right angle of the jaw that were doughy, telangiectatic and simulated an eczema.

There was a red patch with a central erosion, and a surrounding opalescent color in the left cheek pouch. This patch was not circular, but stretched forward along the interdental line. Below this there was an opalescent patch without erosion.

A diagnosis of syphilis had been made on the evidence of the lesions themselves, without any other evidence whatever, and the patient had received two intravenous injections of salvarsan in the previous May and June, followed by hypodermics of sublimate and inunctions of unguentum hydrargyri, with, of course, no result.

She suffered from quite marked gastro-intestinal disturbances, had flatulent dyspepsia, and there was dilatation

Digitized by Google

of the stomach and clapotage. She also suffered from constipation, and much gas in the bowels, and the physical examination of the abdomen showed the intestines markedly dilated with gas.

CASE 4.—June 4, 1908, a girl, aged 17, consulted me on account of a "bat wing" lupus erythematosus of the face and reddened bald patches in the scalp. She said the first appearance of the disease was on the left index finger the previous December. The eruption was preceded by a few months of irregular menstruation.

She had erythematous blotches on the roof of the mouth, and there was roughening of the upper gums far back on their inner sides, that is, the sides facing the mouth cavity.

It cannot be asserted unequivocally that the lesions in the mouth in this case were those of lupus erythematosus. It can only be said that they occurred in a patient having this disease, and that they were not herpetic or luetic, or the lesions of lichen planus or of erythema multiforme.

Her general condition was not good. She was markedly anemic, and the skin around the mouth was a dirty yellow. When she first came in her hemoglobin was 49 on the Dare instrument. She had a coated tongue, a heavy breath, and frequently a feeling as of a lump in the stomach. She was constipated.

CASE 5.—A married woman, aged 26, consulted me, April 17, 1909, on account of a raised, light red, desquamating, well-circumscribed lesion that formed a segment of a ring, and was situated on the upper portion of the bridge of the nose and extended to the right. This eruption had begun two years before, when she was suffering from pains and gas in the stomach and abdomen, and when her baby was 6 months old.

On her second visit, May 1, 1909, I became aware of a right-sided rhinitis, best marked on the right side of the septum nasi. The reddened surface was sharply bounded at its lower edge, and below this sharp boundary the epithelial surface was thickened and sodden looking. There was a marked tendency for this surface to crust.

The skin over the elbows was rough, she had seborrhea sicca of the scalp, her nails were slightly brittle, and she had some acne of the chin. The patient was in fairly good health, but she suffered from flatulent dyspepsia, constipation and mucous discharges from the bowels. Her conjunctivae were tinged slightly yellow as with bile. She suffered from muscular pains in the shoulders and arms, and occasionally had temporofrontal headaches. She was anemic.

During the succeeding winter there was an exacerbation of the lupus erythematosus lesions. About some of them there appeared a bright red margin. At the same time there

Digitized by Google

occurred a scattered papular eruption of the left ear shell, and some pernio-like lesions of the fingers; one of them on the back of the first knuckle of the left index finger was disk shaped. Toward spring all these manifestations either quieted down or entirely disappeared.

CASE 6.—A single woman, aged 30, consulted me, Feb. 25, 1913, on account of lupus erythematosus of the left cheek and of the bridge of the nose. The patch on the left cheek had a bright red border about 2 mm. in width. Within this border the center was scaly and lighter red. The patch had been present for some months, but within the last two or three weeks a red crusted lesion had appeared on the bridge of the nose.

During the preceding summer, and previous to the appearance of the eruption on the face, she had remarked a redness of the lower lids. There was redness and thickening and some crusting of the middle two thirds of the free edge of each lower lid. This was pronounced enough to give her a peculiar expression.

Both lips were dry and scaly, and the lower lip was irritated along the mucocutaneous border. The gums were a little redundant, but otherwise in very good condition.

The symmetrically patchy circumscribed character of the lesions on the lids, together with their permanency, would be enough to permit them to be classed as lupus erythematosus patches. The condition of the lower lip was not characteristic enough to allow making such a strong inferential diagnosis.

The patient did not complain of any trouble in the stomach at all. Her tongue was coated, and she had been constipated, but at the time of her visit the bowels were regular. There was, however, splashing in the stomach and very extensive hypertympany over the bowels. She slept well, but she had spent three weeks of the previous month in a hospital on account of nervousness.

CASE 7.—A man, aged 40, consulted me, Dec. 29, 1913, for lupus erythematosus lesions of the left side of the upper lip, left cheek, left wing of the nose extending into the nostril, left parotid region and of the inner surface of the right ear shell. The mucous membrane in both cheek pouches far back, opposite the last molars, was affected.

The affection had begun three years previously on the outer surface of the upper lip as a papule, and had gradually spread out over the left cheek and up on the left wing of the nose and into the left nostril. The advancing border of this lesion was so prominent, indurated and of such a deep red as to cause it to be mistaken for many other diseases, especially syphilis. That part of the border which ran along the mucous surface of the left side of the upper lip was quite characteristic. It was a narrow line covered with white,

Digitized by Google

tightly adherent, hyperkeratotic epithelium. The area on the lip and cheek, enclosed by the border, was thickened, rough and scarred, and the upper portion was a dirty buff color. The scarring appeared to be partly due to the disease and partly due to wounds made in extirpating pieces of skin for microscopic examination. The lesion over the left cheek was a large dusky red raised papule with a depressed center. The lesion in the hollow of the left ear shell was covered by a hard, horny, yellowish plate of thickened epithelium, with a pitted surface. All the skin lesions were very tender.

The lesion in the right cheek pouch opposite the last lower molar consisted of a number of soft, smooth, rounded elevations which were not indurated. This field was sharply bounded above by a white line where it came against the healthy mucous membrane. The patch in the left cheek pouch was slightly reddened with no definite border, and there was frequently in this situation, where the mucous membrane was reflected on the gums, a leukoplasia-like whitening of the surface and occasional cracking.

At one time during my observation of this patient he got a red erosion of the mucous membrane of the gums below the lower right bicuspids. This lasted only a couple of weeks, but may have been a lupus erythematosus lesion.

The patient suffered from retracted, easily bleeding gums, a heavily coated tongue, a splashing, dilated stomach and an overloaded lower bowel with very offensively smelling evacuations. The colon in the left inguinal region felt like a thick caoutchouc bar.

The whole integument was passively congested, and the patient's hands were markedly tremulous.

Case 8.—A woman consulted me, March 14, 1908, on account of a red scaly lesion occupying a large part of the left cheek, and other lesions in the left ear shell, on the tip of the nose, on the right cheek, on the right ear, on the forehead and one below the internal canthus of the right eye that involved the mucous membrane of the lower lid. There was also a split-pea-sized lesion on the vermilion of the upper lip. Although none of these lesions were of a classic type, they were characteristic enough both in their appearance and in their course to permit of a diagnosis being made.

The patient's general nutrition was anything but satisfactory. She was large and fat, and the fat was soft and pulpy. She had a bad breath, heavily coated tongue, and suffered from severe headaches attributable to the condition of the stomach. She had had the fallopian tubes removed, April 14, 1906, and up to one year before she had some undetermined trouble in the lungs. Her father, her eldest brother and her cousin had died of pulmonary tuberculosis. Her temperature was generally slightly subnormal, and tuber-

Digitized by Google

culin, which was given to her as a treatment, caused no febrile reactions.

The patient's face had always flushed easily from early girlhood, and her present malady had appeared first one year before, as a red lesion on the left cheek. She exhibited still other symptoms of a too mobile vascular system, as whiteness and coldness of the fingers, and coldness of the feet. The eruption improved gradually under a treatment directed to clearing up the gastro-intestinal symptoms. Many of the patches, however, left scars, as is characteristic of lupus erythematosus. New patches of small size and of little induration still appear.

In the spring of 1909 a patch occurred, invading the mucous membrane. This was treated with solid carbon dioxid and disappeared, leaving a slight scar.

Case 9.—A girl, aged 16, applied for treatment, May 6, 1913. A small red spot had broken out on the external surface of the left lower eyelid one year before, and it began to spread decidedly in October, 1912. When she applied for treatment in May it had invaded the mucous surface of the lid. She also had a patch on the edge of the shell of the left ear. The patches spread as a ring, clearing in the center.

She had a coated tongue with a bright red tip. She had suffered recently from frequent dizzy spells and headache, and occasionally she had wind on the stomach. The stomach was dilated and she had marked splashing. She was constipated. Her feet were always cold.

In the fall of 1913 she had an acute exacerbation in which the eyes were almost closed.

Case 10.—A woman, aged 30, consulted me, Sept. 13, 1913, for lupus erythematosus which had begun three years previously on the skin at the outer angle of the right eye. The eruption remained confined to this locality for more than one year. Nearly two years after this, a lesion appeared on the right cheek, and a few months afterward another one on the left cheek.

The patient's history previous to the appearance of the eruption was interesting. Just one week before the first occurrence of the lupus erythematosus, she had been operated on for tubal pregnancy. Previous to that she had had an operation for appendicitis; just previous to that for floating kidney, and previous to that she had a curettement. She was subject to migraine that centered particularly in a nerve at the inner canthus of the right eye.

She had a poor appetite. Her tongue was coated, she had a burning pain and much wind in the stomach. She suffered from dizziness and muscae volitantes, and she had a tendency to be constipated. She was a poor sleeper.

When she first consulted me, the lesions were light red, markedly keratotic and circinate, and occupied both cheeks

Digitized by Google

and the right upper eyelid, the edge of this constituting in this case the involvement of the mucous membrane. The mucous membrane of the lower lip was very red and frequently cracked, but the condition was not characteristic enough to say that it was part of the lupus erythematosus process.

The patient's general health was wretched, and she frequently had angioneurotic symptoms of the extremities. One morning during the cool weather in March she came to the office with dead fingers, local syncope. A few minutes later some of the fingers, especially the left annularis, assumed the beautiful transparent pale blue color seen in Raynaud's disease. The hands and forearms were violet blue. On this occasion the lupus erythematosus lesions were light red and desquamating, and one of them, situated outward from the left eye, had an active red border.

Case 11.—A man, aged 67, and of a particularly robust appearance, called on me on account of lesions in the cheek pouches.

The affection began two and a half years previously as a lesion on the left side of the dorsum of the tongue, where there was still a delicate opalescent shade of color. In the right cheek pouch there was localized superficial desquamative inflammation with white patches of sodden epithelium scattered over the reddened surface. There was a similar, but much less marked, lesion in the left cheek pouch. The lesions were permanent, but subject to acute exacerbations, during which they became extremely annoying from their painful rawness. During an acute attack there was drooling of a brown fluid.

Besides the foregoing, the patient had vitiligo of the back of the hands, prurigenous eczema of the anus and acne of the buttocks. He also suffered from sharp attacks of pain in the cardiac region, which had been diagnosed as angina pectoris, but which were probably due to an immensely distended colon.

There was no history of syphilis; none of the lesions present resembled syphilis, and the blood gave a negative Wassermann reaction.

Under general treatment and diet directed to correcting the bacterial fermentative processes in the alimentary canal, the lesions in the cheek pouches, the drooling and the eczema ani were reduced to insignificant manifestations. The lesion in the right cheek pouch resulted in a superficial but distinct scarring, and the delicate opalescence on the dorsum of the tongue was also probably due to a fine scarring of the papillary layer. This scarring was of great importance from a diagnostic standpoint.

Syphilis, lichen planus, herpes simplex and lupus erythematosus had to be considered in the diagnosis. Syphilis was

Digitized by Google

excluded because of the appearance of the lesions themselves, the absence of any syphilitic history and the negative Wassermann. Lichen planus of the cheek pouches shows a characteristic fine white lacework and white-topped papules that were never present in this case. Besides the characteristic local appearance of lichen planus, there is usually a lichen planus eruption of the skin. None of these appearances were present in this case. Herpes simplex rarely forms a continuous eruption. It usually appears in outbursts more or less widely separated in time. The individual lesions are usually small and cup shaped with a yellow floor, and if they occur in groups, each group will have a microcyclic polycyclic edge.

The persistency of the lesions, the absence of symptoms pertaining to affections for which they might be mistaken, and the production of superficial scarring lead to the belief that this was a case of lupus erythematosus of the mucous membranes alone.

The eleven cases herein reported show lupus erythematosus in nineteen locations on the mucous membranes. The locations were as follows: cheek pouches, five; gums, three; roof of mouth, one; lips, four; nose, two, and edges of eyelids, four.

Nine of these eleven patients were females, a ratio of more than four to one male. They ranged in age from 16 to 67, two being under 20 and two over 40 years of age, leaving seven, a large majority, between the age limits of 20 and 40. These eleven cases were among thirty-eight instances of the disease seen in private practice since April, 1906. All but one of the eleven had typical lesions on the external surface, while in the one exception, Case 11, the mucous membrane alone was affected, the lesions being in the cheek pouches and on the left side of the dorsum of the tongue. The diagnosis in Case 11 may be questioned, though I believe it to be lupus erythematosus for reasons given in the differential diagnosis in the case report.

Excluding Case 11 for the purpose of determining in how large a percentage of typical cases there was mucous membrane involvement, I found over 27 per cent. It is interesting here to note that Thomas Smith[2]

2. Smith, Thomas: Mucous Membrane Lesions in Lupus Erythematosus, Brit. Jour. Dermat., February, 1906, p. 59.

Digitized by Google

observed sixteen cases with mucous membrane involvement among fifty-six consecutive cases, more than 28 per cent. All were females. This indicates a distinct tendency for the disease to affect the mucous membranes, and this fact may be of the greatest importance from the standpoint of etiology.

One of the characteristics of lupus erythematosus of the mucous membranes is its persistency. As stated before, the hidden lesions, those of the moist surfaces, are usually erosions which, when not acutely inflamed, are covered with sodden epithelium and bordered by an irregular edge that is but slightly raised and without much character. The patch may have a yellow coating or may be leukoplasic. When leukoplasic it has less character than the leukoplasia of lichen planus, syphilis or that resulting from irritants, such as tobacco smoke. It is definitely patchy without papules, and is unlike lichen planus of the mucous membranes, which is papular, the papules being white topped and grouped if multiple, giving a characteristic fine, white, lace-work appearance. Though of long standing, it is less thickened than leukoplasic areas of syphilis or those resulting from irritants, and it has not the corrugated surface often seen in such white areas. The lupus erythematosus erosion is not all leukoplasic nor always leukoplasic in part. It may be opalescent and not eroded, or may have the appearance of a recent erosion produced by cauterization or other traumatism, except that the edge is more distinct in the acute erosion. It may have a most innocent appearance and not cause any disturbance aside from its constant presence.

Mucous patches of syphilis have bases which are covered with more sodden epithelium and have a dirtier appearance. Other signs may or may not be present. As with any of the persistent mucosa lesions, one has to resort to every means to reach a positive conclusion. Some of the late opalescent spe-

Digitized by Google

cific lesions of the tongue may be closely simulated by lupus lesions. The specific lesions here are usually more thickened and are often fissured. They, too, are persistent, remaining for years without treatment, and even in spite of the old methods of medication, though they will yield delightfully to salvarsan. If there is sufficient doubt in favor of a syphilitic nature, even though laboratory findings may be negative, salvarsan should be administered. Mouth lesions may be especially puzzling when the external lesions closely simulate squamous syphilids, as did those in Cases 3 and 7.

While stubbornly resisting treatment, the condition often shows acute exacerbations. These exacerbations are so definitely associated with disturbances in the general health, particularly derangements of the gastro-intestinal system, that one must carefully consider the importance of this in the etiology of the disease. A small area of affected mucous membrane may persist for months without treatment, and even with treatment, both local and internal, may be as unyielding as are some of the external manifestations of the disease. Often when the lesion is nearly healed and all is progressing favorably, some constitutional disturbance will supervene with a coincident sudden reversion. In this respect, these exacerbations bear a close resemblance to herpes simplex with this notable difference, that the individual lesions in herpes quickly and completely disappear, even in those cases in which the attacks are subintrant and therefore continuous, whereas those of lupus erythematosus improve more slowly, and tend not to disappear, or do so with the utmost deliberation. It is not uncommon to observe the occurrence of herpes simplex affecting the mucous membranes of patients under treatment for lupus erythematosus of the skin or of both the skin and mucous membranes. The lesions of herpes are usually easily distinguishable from the older disease, as the

Digitized by Google

edges show a more acute inflammation, the borders being congested and reddened; and though in acute exacerbations of lupus erythematosus the lesions may have as deeply reddened and prominent borders, there will not be the cup shape, nor will groups have the microcyclic polycyclic edges such as are seen in herpes. In healing, herpes lesions do not leave scars, whereas one of the characteristics of the other disease on the mucous membranes as well as on the skin is its scarring.

When on the vermilion of the lips the lesions are painful, especially during an acute exacerbation. W. K. Sibley[3] mentions this in reporting a case with an active lesion present on the vermilion of the upper lip, which was very painful, whereas the condition inside the mouth had not caused much discomfort. In the four instances mentioned in the case reports of this paper in which the vermilion of the lip was affected, there was an appearance of being coated with collodion, as mentioned in Case 2. This was the best example of this phenomenon in this group of cases, and was accompanied by the greatest discomfort.

Since having attention drawn to the gums of patients with lupus erythematosus, I have observed that only exceptionally are the gums in good condition. A history of easily bleeding gums is common. Gingivitis is almost constantly found. Redundancy or retraction is often marked, and the teeth are usually bad. The conditions are so constant as to point definitely to long-continued antecedent gastro-intestinal derangements which have reacted on the gums and teeth. This would seem to be a point of some importance, which, associated with the not infrequent presence of more characteristic affections of the mucous membranes, should direct the attention of the observer to digestive and assimilative faults of long standing as

3. Sibley, W. Knowsley: Brit. Jour. Dermat., March, 1914, p. 101. In connection with this case report a complete bibliography is given.

Digitized by Google

most probable causative factors. The fact that acute exacerbations frequently occur associated with acute or subacute digestive disturbances would also point to an intimate dependence of the disease on toxemias of gastro-intestinal origin.

One of the most interesting conclusions reached by a careful observation of all the phases of lupus erythematosus of the mucous membranes is that the lesions are the result of a general disease. The manifestations on the mucous membranes and on the skin as well are only symptoms of a deeper pathologic condition. The foundational disturbances undoubtedly vary in different individuals, but, with the cases considered in this article, the evidence pointing to digestive and assimilative faults is weightiest of all. These faults are such long-standing ones, having become so thoroughly habitual, that their eradication is accomplished only after long and persistent efforts. The difficulties encountered in correcting the faulty conditions would partly explain the stubbornness which is characteristic of the disease in yielding to treatment. Not only the resistance to local treatment, but also the recurrences and the appearance of new lesions for a long time while treatment is in progress, can be more easily understood with this point in view. Furthermore, as important as any conclusion is the one that internal treatment and a proper regimen are as necessary as is local treatment for the cure of the patient.

323 Geary Street.

ABSTRACT OF DISCUSSION

Dr. Joseph Zeisler, Chicago: For many years I have been not only embarrassed but severely mortified by the rebelliousness of cases of lupus erythematosus against all of our therapeutic efforts. I say "all" because if we are enthusiastic about one or the other of modern treatments, sooner or later we will find it will fail. We must still admire the wisdom of Kaposi, who said that cases of lupus erythematosus will get well in spite of the worst treatment, and again they will resist our best treatment. Freezing, which

Digitized by Google

we thought for a time was not only the newest but the best method, will sometimes fail us. The beneficial effect is sometimes temporary.

Radium, in favor of which much is said, may cause violent reactions. It is in this sense that I look on Dr. Culver's treatment as an important contribution, in bringing out the internal aspects and treatment of these cases. I believe we must make as careful a study of each case as we can from a symptomatic point of view, and try to find a course of treatment congenial to that. It will not, therefore, always be the same treatment which we should use.

I believe we shall have to include lupus erythematosus with those diseases which perhaps are produced by a disturbance of the internal secretions. That does not militate against the view just expressed by Dr. Culver, as we know there are some secretions eliminated from the intestinal wall which have a bearing. I will try in future to treat my cases on the idea that there is some disturbance of the internal secretions which we must try to overcome by employing various organotherapeutic methods.

Dr. Everett S. Lain, Oklahoma City: My experience in roentgenology has been a valuable aid in the diagnosis of many skin eruptions. My curiosity or interest was excited in this subject, first, by empirically treating urticaria with the vaccine of the *Bacillus coli communis* and noting the prompt response, sometimes in one or two hours, in cases which had been resisting all treatment for a week or several days previously. Next, when I heard a most interesting discussion by Dr. Rosenow last May in Chicago, I came home and began treating by Roentgen ray the teeth in cases of erythema multiforme and other diseases which have been classified as having an idiopathic etiology. I have now, to my mind, some very interesting observations, which, if borne out in a sufficient number of cases, I believe will throw further light on this subject. I believe when we begin to study more closely the focal or internal infections, the same as is being done by the internists with rheumatism, we, too, shall be wiser. The dentists are curing many things by treating the teeth. They are really curing some cases of so-called rheumatism.

Dr. J. B. Kessler, Iowa City, Iowa: Some of the cases of mucous membrane eruptions are difficult to diagnose. A recent case was that of a woman, probably 21 or 22 years of age, who had a pustule on the under lip, extending over on to the vermilion border of the mucous membrane. I examined my patient and did not find any enlarged glands, although this was important. A histologic biopsy was made, and our microscopist thought it was more like tuberculosis. The first Wassermann test was one plus, and the second was two plus. That did not help me. I could not make

Digitized by Google

up my mind that it was syphilitic. In the past we worked without Wassermann examinations to help us out, and so we treated our patients on the line of the textbook teaching of the past, namely, to give a trial of mercury when you do not know what else to do. We started first with hypodermic injections of mercuric chlorid. Giving her a rest from those injections, I employed increasing doses of mercury protiodid. I thought I would return then to the other and the local applications of mercury ointment. To my surprise, before I could get back to the hypodermic injections my patient's lip had improved, and in a couple of weeks it had recovered. I am still at a loss to know whether I had a syphilitic case or not. This was a married woman, with no history of syphilis on either side, but she had worked in a button factory, and there many of the people had sores on their mouths and on their fingers. Now, the point is, could there be syphilitic eruptions without enlarged glands?

Dr. W. A. Pusey, Chicago: If I followed Dr. Culver correctly, he said only one of his cases was practically confined to the mucous membrane of the mouth and lips, and in that case he modestly left the diagnosis open. I have seen several cases of erythematous lupus in which I had no doubt of the diagnosis and which did not spread outwardly to any considerable degree beyond the vermilion surface of the lips. I believe Dr. Culver has done well to call attention to the occurrence of these cases of erythematous lupus on mucous surfaces, and to the possibility of the disease being confined entirely to the buccal mucous membrane. I value highly his comments on the internal factors on the causation of erythematous lupus. To my mind erythematous lupus belongs in the group of toxic dermatoses—in the erythema multiforme group. I have seen erythematous lupus lesions on the face in association with erythema multiforme on other parts of the body, particularly on the hands and forearms. I recall one case of a tuberculous woman with typical erythematous lupus on the face who had lesions on the hands strikingly suggestive of Raynaud's disease. To my mind erythematous lupus is not the expression of a specific intoxication, but runs the whole gamut of intoxications from chronic infections like tuberculosis to such intoxications as come from intestinal absorption. And in searching for the cause of the cases we have to take into consideration all the possibilities of internal intoxication. I would like to emphasize what Dr. Zeisler said about the futility of any single local application in erythematous lupus. We can get benefit from many of them, but we cannot be sure in a given case of benefit from any of them. I do not use radium in erythematous lupus, and very rarely now do I use the Roentgen ray. I have been disappointed, like Dr.

Digitized by Google

Culver, in carbon dioxid snow in erythematous lupus, and I have in a few cases seen it much abused by overfreezing with it. At the present moment I am inclined to believe that vigorous treatment with ultraviolet light is giving me better results in erythematous lupus than anything else I have used. It is a method causing some temporary discomfort, but free from danger.

Dr. Douglass W. Montgomery, San Francisco: It is of course admitted that the etiology of these cases is obscure; although we think we have a right to assume that the disease is due to a toxin located in the gastro-intestinal canal, we know neither the toxin nor the exact place of its origin. The improvement in almost any case is slow. There are two situations in the alimentary canal particularly liable to infection: one the stomach, which is a sac; and the other the second stomach, the cecum, which is also a sac. When the eruption slows down to the very chronic state, then we do get good results from the use of carbon dioxid snow. It acts as a strong revulsive, and gives the eruption the last kick to kick it out. We have, however, given up the use of the carbon dioxid snow during the acute stage.

Dr. A. Ravogli, Cincinnati: I have spoken already in other meetings on the etiology of lupus erythematosus. For me, from the clinical observation and the reaction to the tuberculin, there is no doubt whatever of its tubercular origin. I have seen lupus erythematosus limited to the mucous membranes, and I have seen lupus erythematosus of the mucous membrane associated with lupus erythematosus of the skin, and some of the cases ended with general tuberculosis. I am now using as treatment—and with very satisfactory results—the cataphoresis method. Take the negative pole of a galvanic current and attach it to a little tampon saturated in 10 per cent. solution of zinc chlorid and apply this on the patch of lupus erythematosus, placing the other pole in the hand of the patient, for ten or fifteen minutes of current. The zinc chlorid, together with the action of the cataphoresis of the electrical current, produces an induration of the patch which lasts for something like twenty-four hours, and then gradually disappears. From that method I have seen very beautiful results. Together with this application, sometimes, when the little nodules begin to break down, I touch them with compound solution of cresol; and in four or five weeks I have seen satisfactory results. A case of lupus erythematosus of the tongue in the form of rings, without a manifestation of the lupus erythematosus of the skin, associated with hypertrophy of the submaxillary glands, healed up by touching it twice a week with compound solution of cresol. This application produces some temporary pain, but this is relieved immediately by touching with alcohol; touch

Digitized by Google

it with compound solution of cresol, keeping it there as long as the patient can stand it, and then wash it with alcohol.

Dr. A. J. Markley, Denver: I have had the opportunity of observing a large number of patients in the sanatoriums about Denver and Colorado Springs during the past six years and I can say that in these institutions lupus erythematosus is a rare disease. These cases represent all types of tuberculosis in not only the incipient but the most advanced stages, yet lupus erythematosus occurs most infrequently in Colorado and such an experience, if it means anything, points against any direct connection between the two diseases. I have, however, seen one brilliant result from tuberculin in a case of rapidly developing lupus erythematosus in a woman with no physical manifestations of tuberculosis; the condition cleared up rapidly under injections of tuberculin.

Dr. H. H. Hazen, Washington, D. C.: I think we must be careful in our cases, for with a very large percentage of all adults we find there a strong positive reaction to the tuberculin. I think the Austrian army people found that 60 or 70 per cent. of all the men who came up for examination gave a positive reaction. A number of years ago at the Phipps Clinic at Johns Hopkins we found that all the adults connected gave a very strong positive von Pirquet reaction. I do not think we can say that the cutaneous test means anything in adults. Even von Pirquet himself admits that it is too delicate.

Dr. Ernest Dwight Chipman, San Francisco: The point emphasized in the discussion, that in lupus erythematosus the infection is not necessarily constant and specific, appeals to me strongly. It seems probable that we shall trace the origin of obscure dermatoses more and more to various infections. I recall a case of lupus vulgaris in which I was persuaded to inject a substance of rather uncertain composition, now called a phylacogen. Within forty-eight hours there appeared a typical zoster reaction along the course of the neighboring nerve. Some time ago, in dealing with an herpes progenitalis, I sought in vain a focal infection along the urethra. Later the same individual was found to be suffering with chronic appendicitis, a source which I had neglected to explore. This man has had no recurrence of his herpes since the removal of the appendix.

Digitized by Google

ILLUSTRATIONS OF THE HISTORY OF LEPROSY

DOUGLASS W. MONTGOMERY, M.D.
SAN FRANCISCO

The term "leprosy" is now restricted to a chronic infectious disease caused by Hansen's bacillus, which has a special tendency to involve the skin and the peripheral nerves. This special involvement of the skin and the peripheral nerves produces external symptoms of a coarsely repulsive character, in the main easy of recognition. This is one of the peculiarities that renders leprosy so interesting historically, as even imperfect descriptions by men untrained in clinical observation enable it to be traced back through the ages.

Leprosy, as we now know it, is a well-defined disease with definite and marked symptoms, and a precisely determined cause. This precision, however, is an acquisition of recent years. Previous to the work of Danielssen and the elder Boeck in 1842, the symptomatology of leprosy was not at all fully known. The hazy ideas of the middle ages, and in fact of all previous ages, still persisted. This late clinical study of the disease was a natural historical sequence. Almost all disease, especially that running a chronic course, constituted, up to the end of the eighteenth century, an inextricable jumble. Then began the segregation into groups.

Bichat (1771-1802), by his investigations in pathologic anatomy and in physiology, may be considered the founder of modern medicine. Quickly following him came Laënnec (1781-1826) with his studies in the auscultation of the chest. Ever since, there have not been wanting brilliant men throughout the centers of

Digitized by Google

Western civilization who, by clinical observation, by necropsies and by the shrewd application of the natural sciences, have gone on deepening and broadening our knowledge of life both in health and in disease. At first these observers did not study leprosy, because other material, under their hand, requiring investigation, was abundant, and no leprosy was then present in those cities in which the study of medicine was most active. Students, however, were being continually drilled in the habit of clinical observation and pathologic investigation, and when Danielssen and Boeck, so disciplined, undertook the delineation of a group of lepers in Norway which constituted the chief focus remaining in civilized Europe from the great epidemic of the middle ages, they, in 1842, were enabled to give the disease a well-rounded, satisfactory, scientific standing, as an independent morbid entity.

Shortly after Koch's discovery of the tubercle bacillus (1882), Armauer Hansen discovered the presence of an acid-fast bacillus in the lesions of the above-mentioned group of cases in Norway. This bacillus has been demonstrated as present so constantly and so abundantly in most of the lesions of leprosy that it now constitutes one of the best examples of this kind of parasitism in the tissues.

It is clear that the conceptions of this disease by a well-educated physician of the present day, having at his hand all the correlated knowledge represented by the work of Danielssen and Boeck and their successors, is very different from the hazy ideas previously existing. Hazy and indefinite as the ideas of the older physicians and laity were, they are none the less interesting both in regard to what was true and what was false or faulty.

THE GREEK AND ARAB CONCEPTION OF THE WORD "ELEPHANTIASIS"

In history, each age has its own way of regarding every question, and leprosy is no exception to this

Digitized by Google

rule. The Greeks had a fine plastic imagination, and the human form and its grace either at rest or in motion interested them mightily, as they there saw the highest expression of beauty. Beauty and ugliness, however, are two aspects of the same subject, and naturally, therefore, the Greeks were interested in leprosy, the most deforming of diseases, and it was quite characteristic of them, as we shall see later, to give it the name "elephantiasis."

ELEPHANTIASIS

The word "elephantiasis" with us at the present day means an overgrowth of the skin and the subjacent connective tissues, principally affecting the lower extremities, and due to inflammatory engorgement and blocking of the lymphatic system. Its dominating clinical idea is pillowlike, gigantic enlargement, usually of one lower limb, making it resemble that of an elephant. This kind of enlargement may be due to a number of different causes. In this country it usually occurs as a consequence of chronic streptococcic infection, that gives rise to repeated attacks of erysipelas. This is generally associated with ulcus cruris but not necessarily so. In some tropical countries, an endemic disease, filaria, causes enormous enlargements of the legs or of the scrotum. Elephantiasic enlargement may also be due to direct blocking of the lymphatic circulation, as by tumors, or by cicatricial bands. For instance, immense enlargement of the pudenda may be occasioned by ulcers and cicatricial contractions, usually syphilitic, in the rectum.[1]

ELEPHANTIASIS OF THE ARABS

As a consequence of the conquests of Mohammed and his followers, the Arabs grew to be a wealthy and highly cultivated people, and as one of the expressions of this cultivation, became interested in medicine. As

1. Tomasczewski: Elephantiasis, Lehrbuch der Haut- und Geschlechtskrankheiten, E. Riecke, 1914, p. 425. Verlag von Gustav Fischer, Jena, Germany.

Digitized by Google

they lived in a country in which filaria was prevalent, they saw much of the enormous enlargement of the lower extremities and scrotum due to this infection. These enlargements, together with any others that might occur, they assembled under one name, *da al-fil,* elephant foot. Their conception of elephantiasis included about what we accept under the same term, the only difference being, and it is a great one, that the Arabs grouped all the cases together under their gross external appearances, whereas we classify them as far as possible, under their etiologic heads.

ELEPHANTIASIS OF THE GREEKS

The Greek conception of the term "elephantiasis" as applied to leprosy was quite different from that of the Arabs and of ourselves, and took up a phase of leprosy little regarded in modern medicine.

As mentioned before, the infection in leprosy is a peripheral one, and attacks the skin and creeps along the nerves. As it invades the nerves it causes paralyses, sensory disturbances and atrophies in the regions supplied by those nerves. For instance, ulcers, principally of the foot, are a frequent accompaniment of leprosy. Some of these are perforating ulcers due to interference with the trophic nerve supply. Others are from burns or other injuries. Those from burns are particularly frequent, because of the loss of temperature sense, that occurs so early in leprous neuritis. These ulcers often become the seat of streptococcic infection, and consequently there supervene more or less severe attacks of erysipelas, with integumentary thickening and deformity of the foot. In addition to the foregoing, the trophic disturbances of leprosy often involve the deeper structures, and cause shortening of the toes and of the foot owing to absorption of the bones.[2] As the leprous neuritis advances upward, it

2. W. Dubreuilh and A. Bargues say that the Greeks gave this disease the name "elephantiasis" because of the stump foot that is so frequently present (La Lepra de la Bible, Lepra, Nov. 1914, p. 14). A German author, whose name just now escapes me, speaks in the same connection of "Der schleppende Gang." Undoubtedly both considerations entered into the conception.

Digitized by Google

causes paralysis and shrinking of the great muscles of the calf that move the foot. There consequently is often produced a clumped stumplike foot and a thin leg. The loss of flexibility of the foot and leg causes a rolling heel and toe walk, and the paralyses occasion a loose fling at the knee and hip, which in a measure resembles the trailing gait of an elephant.

The Greeks and Arabs, dwelling in warm countries, and wearing scanty clothing, saw these deformities much more frequently than we of the temperate and colder climates would. In fact, the lepers themselves would attend to the exposure of their own limbs, as almost all lepers are poor, and a poor lame leper would naturally be a beggar, who would expose his deformities in order to excite pity.

It can therefore be readily seen that two conceptions of the word "elephantiasis" arose in neighboring peoples. The one conception, prevalent among the Greeks, referred principally to the deportment, and included leprosy and doubtless many other affections having a clump foot and trailing, awkward gait. It was just such a metaphor as the Greeks with their fine plastic imagination would appreciate. The other conception of the term "elephantiasis," prevalent among the Arabs, referred principally to gigantic and deformed overgrowth, and included, among other diseases, the affection that we now know to be occasioned by the *Filaria sanguinis hominis*. It referred to the gross enlargement of the leg, and was appropriate. It had none of the fine perspicacity of the Greeks, but it was just such a metaphor as a people who forbade all plastic art would make. Neither term was precisely defined, but precise definition was not a characteristic of those times.

THE ERA OF THE CRUSADES

At the time of the crusades (1095-1270), and under the influence of religious fervor, any evident bodily affliction, such as lameness, was considered conducive

Digitized by Google

to the soul's salvation; and as spiritual elevation, as contrasted with carnal corruption, was then the serious business of life, one can see what a treasure such a deforming ailment as leprosy became. St. Giles, after whom so many leper houses in England were named, was crippled.[3] His infirmity was due to a wound, not to leprosy, but he did not wish to be cured because of the virtue accruing from the maceration of the flesh, and this illustrates the attitude of the age in regard to such afflictions. The Knights Templar was the most powerful monastic military organization that arose under the influence of the crusades. It became so rich and powerful as to constitute a threat to more than one throne in Europe. It has been said that in order to become a candidate for the Grand Mastership of this organization, it, at one time, was necessary to be a leper.

If it is desired to obtain an idea of how people thought in the middle ages, apply to Rabelais, the Great Mocker, who lived and wrote when the spirit that animated that period was declining, and the brilliant renaissance was dawning. He describes a renowned disputation between an Englishman, Thaumaste, and Panurge. This disputation was carried on wholly without words and entirely in the sign language. During its course Panurge drew from a pocket a piece of white ox rib and two sticks, the one black, the other red, which he struck together, making a sound like the lepers of Brittany, but clearer and more harmonious. The physicians and surgeons in the audience thought this sign to indicate that Panurge considered Thaumaste a leper, while the councilors, legists and decretalists interpreted the action to mean that leprosy, as the Lord had formerly held, was a kind of human felicity.[4] This shows that when Rabelais wrote this chapter, forty-six years after the discovery of America,

3. Fletcher, W. G. D.: The Lepers of Shrewsbury, Without the Camp, January, 1912; abstr., Lepra, June, 1912, p. 222.
4. Pantagruel, Bk. ii, Ch. xviii.

Digitized by Google

this way of regarding disease as a distinct moral and spiritual advantage still persisted, but was old fashioned, and was a subject for mocking laughter. Under such a favoring attitude of mind as existed at the time of the Crusades, assisted by the general lack of hygiene of a low form of civilization, it is no wonder that leprosy increased mightily in Europe.

ERA OF THE REFORMATION AND OF THE RENAISSANCE

This era is most attractive in regard to leprosy. It was a time when the Bible excited universal interest, and when vast numbers of people accepted what was written in it with unquestioning faith. By a curious combination of circumstances, it became the principal political document in one of the bitterest political fights ever experienced, which culminated in the Thirty Years' War. During all this time and for long afterward, the Bible was studied with a fanatical bias that we can hardly appreciate. Because of the mistake in the translation of a word in it, and a further mistake in applying Biblical precepts to the chronic infectious disease of which we are speaking, leprosy came to be regarded as a highly infectious malady. In order to understand just what happened, it is necessary to hark back to a time when the Jews lived under a theocratic government, and so to ascertain the true meaning of the Hebrew word *Zaarath,* that was translated by the Alexandrian Jews as the Greek word lepra.

THE HEBREW WORD "ZAARATH"

Under Moses and his followers, the Hebrew theocracy ruled the people as only a theocracy can. Under this curious government, a tribesman could be arbitrarily called before a priestly tribunal to undergo an examination as to whether he was Zaarath, or as McEwen has translated it, "taboo." [5] This tribunal was uncontrolled, it passed on the evidence and issued

5. McEwen, E. L.: The Leprosy of the Bible; Its Religious Aspect, Biblical World, October, 1911.

Digitized by Google

the sentence, and if the defendant was declared taboo, he had no recourse but to submit. Under such circumstances, the evidence was sought in minute trivial appearances on the skin, the presence of which was largely a matter for the observers to decide, and had no relationship whatever to any definite disease process. As Unna has pointed out,[6] Zaarath had a theological, not a medical meaning, and it is time wasted to try to define the word as appertaining to any one disease or group of diseases. Zaarath remained, as it was intended it should, a vague indefinite something, usually connected with an assumed external bodily defect, the possession of which entailed the banishment of the afflicted person from the community. An appreciation of the utter hopelessness and abandonment of such exile can only be acquired on realizing that in uncivilized life everything outside of the community is strange and inimical.

This word, Zaarath, naturally was embodied in the Jewish religious writings.

On the founding of Alexandria, many Jews settled in that city, and they took with them their religious writings. As time passed, Greek became their everyday language, and the religious writings were translated into that tongue, forming the Septuagint translation of the Old Testament.[7] In this the Hebrew word Zaarath was rendered into the Greek word lepra, meaning literally a scale, and no doubt having a signification as wide and loose as the English expression "dry tetter." It principally included psoriasis, and indeed into the last quarter of the eighteenth century lepra was one of the synonyms of psoriasis. Later the writings called the Septuagint, together with others of Jewish origin, formed the collection called the Bible, that still later assumed a world importance as the

6. Unna, P. G.: Ein typisher Fall von Papierwissenschaft, Lepra, February, 1913.

7. This translation was made under Ptolemy Philadelphus, 284-246 B. C., and later, down to 150 B. C.

Digitized by Google

principal book appertaining to Christianity, and incidentally, as before mentioned, these writings had a great influence on the European attitude toward leprosy. It was the Septuagint that formed the basis of part of the Latin Vulgate, just as the latter formed the medium for the rendering of the Scriptures into the various European languages. In all of these, the word lepra was carried along.

During the first centuries of the Christian era the influence of these writings must not have been nearly so great as they afterwards became, because only the learned, and they were few, could read them. The spiritual life of the Church was carried on by tradition, and by those few who could read, so that the translation of the Israelitish word Zaarath, taboo, into the Greek word lepra, dry tetter, must not then have done much harm. Its day was approaching, but it was not yet.

The Arab civilization has been already mentioned, and the attention paid in it to the study of medicine. The Arabs, however, were not investigators, they were translators and imitators, and they translated the works of the ancient Greek and Latin authors into their own tongue. Constantin of Carthage, who died in 1087, retranslated these works from Arabic into Latin, and instead of employing the word elephantiasis for the Arabic word *djudsam,* which signified the disease we now call leprosy, he chose the word lepra, the very word the translators of the Septuagint had used to translate the Hebrew word Zaarath or taboo. This is, indeed, the first appearance of the word lepra as indicating the disease we now know as leprosy. These translations of Constantin had a great vogue in the middle ages. In fact, the smashup of the Roman Empire had been so thorough that it was through the Arabs alone and largely through this Constantin that the people of Western Europe became acquainted with the Ancient Greek and Latin authors.

Digitized by Google

Fig. 1.—Tubercular leprosy in a Chinaman. The disease has caused blindness, and the eyebrows and eyelashes have fallen out. Quite characteristically the hair of the scalp has not been affected.

Digitized by Google

Fig. 2.—Alligator-leather appearance of the posterior surface of the leg in a leprous Chinaman. Below are seen some white epithelial disks covering lepra tubercles.

Digitized by Google

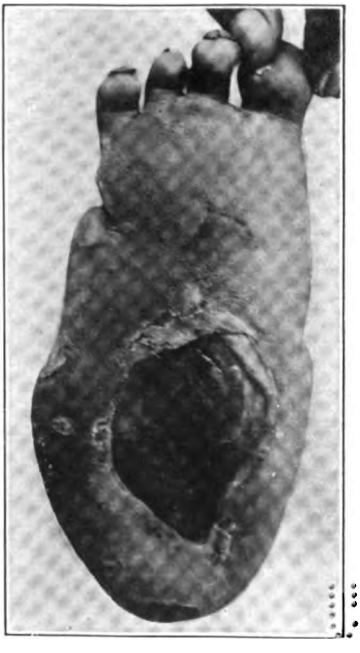

Fig. 3.—Ulceration of the sole in leprosy. From a photograph received through the courtesy of Dr. J. S. B. Pratt, President Territorial Board of Health, Honolulu, Hawaii, H. I.

Digitized by Google

Digitized by Google

The year of the discovery of America by Columbus, 1492, is now accepted as the year when syphilis was imported into Europe by Columbus' sailors. This date is also accepted as the close of the middle ages. For years previous to this, leprosy had been gradually disappearing from Europe, and its diminution and gradual extinction may be ascribed, at any rate in part, to the erroneous views of the disease drawn from the Bible.

For years before the actual Reformation, the Bible was becoming more and more read, and by a people uncritical in medical matters. It was perfectly natural, therefore, for them to infer that what was said of Zaarath, or as the translation ran, lepra, was said of the hideously ostentatious disease so prevalent in their midst. And besides this, as we have seen, Constantin, in his translations, had designated true leprosy as lepra. The most rigorous segregation, facilitated by the existence of numerous leper houses, and backed by unquestioned scriptural authority, was instituted against what they considered this very contagious disease. This segregation, together with the increased cleanliness incident to an advancing civilization, was so successful that by the time usually set by historians as the beginning of the Reformation (1517), leprosy was well on the way to extinction in central Europe.

THE ATTITUDE TOWARD LEPROSY IN MODERN LIFE

Much of the kindliness and welcome we receive in this world is due to the pleasantness we radiate from our own person. A benevolent or genial face is an asset, and frequently gives a just reflection of the mind within. Two of the most selfish, ruthless persons I have ever met were, however, provided with benevolent features. In the same way a scowling, hard visage may hide a heart of gold. One of the most sad features of leprosy is the distortion and disfigurement of the features. In tubercular leprosy the eyebrows are changed into two irregular, prominent hairless rolls,

Digitized by Google

the nose is disfigured with nubs, and in the glabella there form nodules separated by deep furrows, the lips are thickened and deformed, and the cheeks are irregularly indurated and discolored. All this gives a threatening, scowling aspect to the deeply sunken eyes. In leprosy of the nerves of the face, the features are twisted out of shape as a result of paralysis and muscular atrophy. Under no circumstances is such a visage pleasant to look upon, and in superstitious communities, imbued with mysticism, such as were the European countries of the middle ages, it is no wonder that the victims of leprosy were regarded with the greatest horror.

The poor lepers have still another unamiable characteristic. They are particularly thankless for any attention shown them, and they are stupidly indifferent to the horror they excite. When a person is disagreeable and unaware of the fact, it impels many of his neighbors to active aggression. I have often thought that this stupid indifference is possibly the result of a toxin, the same one that possibly causes loss of sensibility of the peripheral nerves. These are only a few of the repulsive features of this repulsive disease, and yet, in my experience, suicide is infrequent among them.

Just the attitude the public of today assumes toward leprosy is difficult to determine. Individual tendencies are so varied that it is hard for one in the midst of a movement to get the general drift. It seems, however, to partake of the general altruism toward the unfortunate. On the part of those scientifically trained, the disease has excited a lively curiosity as to its nature, and especially as to its mode of transmission. Among the general public there still remains a great fear of the contagiousness of leprosy, evidently issuing from the erroneous interpretation of certain passages of the Old Testament, and the natural repulsion toward the disease. There is an evident desire to

Digitized by Google

get them quickly gone to a remote place with a wish that they may not be overhasty in their return. As a matter of fact, leprosy is very reluctantly contagious, and must require very special favoring circumstances in order for it "to take." A very modest degree of cleanliness hinders its transmission. As soon as a country becomes well to do and adopts the daily tidiness incident to modern civilized life, leprosy dies out. Although, therefore, the Biblical view of the highly contagious nature of leprosy undoubtedly aided in stamping out the epidemic of the middle ages, in modern life it works an unnecessary hardship on the afflicted, and should give place to a more reasonable attitude, agreeing with the real facts in the case.

323 Geary Street.

Digitized by Google

SYMPTOMS AND DIAGNOSIS OF LEPROSY

WITH REPORT OF CASES

HOWARD MORROW, M.D.
AND
A. W. LEE, M.D.
SAN FRANCISCO

The compilation of notes in this paper is the result of study of the lepers in the Isolation Hospital of San Francisco, of private cases and of observation of patients in the University of California Hospital. The thirteen cases of leprosy in the Isolation Hospital are all chronic, and most of them show evidences of all stages of the disease.

Leprosy is a chronic infectious disease that is produced by a semiacid-fast micro-organism which, morphologically, somewhat resembles the tubercle bacillus. After invasion into the human body this bacillus effects changes in it which are of apparent diagnostic significance.

Leprosy must be regarded as a systemic disease, and may, at some period of its case history, implicate any or all of the units of the human body. This statement can be verified by a direct or indirect manifestation of the malady. By an indirect manifestation of leprosy we mean that, in consequence of the long-continued loss of bodily resistance, an intercurrent infection is very likely to occur. By a direct manifestation we refer to those instances in which either subjective or objective variations from the normal condition of the body have resulted from the presence of the lepra bacillus in the various organs, as has been proved by laboratory methods of investigation.

Digitized by Google

As has been stated, while any part of the body may be involved at some epoch in the course of an average leprosy infection, we feel that it is proper to devote most of the detailed division of this paper to those pathologic changes in the integument which may result from it, and particularly are we of this opinion since the great percentage of lepers is recognized by skin lesions. These cutaneous evidences of leprosy can be grouped under more or less definite clinical types, but it is quite possible for one variety to merge into another, or to be simultaneously accompanied by every form of integumentary lepra. Evidences of leprosy that appear in the skin may assume the form of a macular eruption, trophic changes following nerve involvement, areas of pigment increase or decrease, and hypertrophic process located in the corium and superimposed structures.

In macular leprosy the lesions may be few or numerous, the affected areas may be large or small, their periphery is usually round or ovoid, their margins as a rule are sharply defined and sometimes elevated. In the beginning these macules are bright red, soon changing to reddish brown. With chronicity they tend to pale in the center, and, by coalescence of their outlines, to form gyrating figures. The margins of such lesions may have a purplish tinge, suggesting a certain form of erythema multiforme of the skin, and at times deep pigmentation occurs in their outermost limits. When central clearing does take place in the macular eruptions of leprosy it assumes a fawn-like color or that of the infected persons' normal integument. Where leprous macules have appeared there is a local decrease of perspiration, a crapelike irregularity of the skin surface and the presence of scales. So far as changes in sensation are concerned, macular leprosy may be entirely free of them during the first few months of its development, or the affected areas may be hyperesthetic. In

Digitized by Google

the later stages, however, these macules are usually anesthetic. When a long-standing macular eruption of leprosy acutely exacerbates, its color flames into a bright red as in its earliest form.

Pigmentary macules are occasionally observed which have not been preceded by any other leprous eruption. And again, areas of depigmentation appear, which, likewise, develop independently of the foregoing manifestations of the disease.

The macular and pigmented varieties of leprosy cause a very inconsiderable interference with the normal functions of the body, and yet in another phase of the infection the pitiable sufferer becomes totally incapacitated for even the simplest employments, and passes into a condition which is as repugnant as that of the most distorted mummy of Egypt or Peru. At this time the nervous system has been directly attacked, and since the ulnar and peroneal nerves are most frequently involved, the greatest deformity results in the hands and feet. Now and then these nerves are so enlarged that they are easily palpable, and in some cases the small cutaneous nerves are so tumefied that they can not only be felt but actually seen. As these pathologic nerve changes go on, contractions occur in the flexor muscles of the hands until the fingers have become so folded on themselves that the condition is commonly termed "the leper claw." The bones of the fingers and toes may be absorbed, in this stage of leprosy, without ulceration, being the result of a rarefying osteitis. This leads to the formation of the so-called "stump" and produces the clinical condition of lepra mutilans. In this variety of nerve leprosy ulcers may be numerous and large, the eyes may be destroyed, the nasal bones absorbed, and the nostrils closed. Fingers and toes are occasionally amputated in a spontaneous manner at this period of the infection. One of the rarer manifestations of leprosy associated with the

Digitized by Google

nerve type is the appearance of bullae. These may be seen on any part of the body, but they are generally found on the hands and feet.

Leprosy may announce its presence in other ways from those previously outlined, such as nodular eruptions on the face, limbs and trunk, and clinically this is spoken of as "nodular leprosy." Hoarseness is an early manifestation of the nodular type, due to the presence of lesions in the larynx and pharynx. These submucous nodules have a tendency to ulcerate, but they usually heal during remissions of exacerbations. The lesions can be either large or small, and the face is the part of the body which is as a rule most extensively affected. When the face does show the greater amount of involvement, the nodules are commonly of the large variety; when the body is the site of nodular formations, the smaller type is the usual finding. Every now and then a case will be observed in which the nodules are not located in the skin proper but occupy a subcutaneous position; in such instances it might be almost impossible to catch the lesions between the examining fingers, as they have formed attachments to the underlying tissues. The nodules of the usual type are frequently elastic to the touch, corresponding to that palpable sensation experienced on manual examination of miliary gummas. It is not unusual to see large comedones in nodular leprosy of the face and trunk. Aside from the distinct lesions in nodular leprosy of the face there is a deep wrinkling of the forehead, a broadening of the nose, a thickening of the lips, a tumefaction of the skin of the outer part of the eyebrows, all of which go to contribute to the well-known "leonine expression" of chronic leprosy. The hair of the eyebrows usually falls out, and that of the scalp becomes dry and tends to a premature graying. In cases of well-marked nodular leprosy the lesions are usually grouped, they are reddish brown, but they assume a brighter hue during

Digitized by Google

exacerbations. They become anesthetic quite early. The nodules might disappear in a few months or persist for years, with or without ulceration. When ulceration does occur healing is followed by cicatrization. When absorption of the nodules takes place without ulceration, areas of cicatricial atrophy or deep pigmentation mark the location of the vanished lesions.

With or without the presence of active leprosy, particularly in the later stages, a marked desquamation of the skin may occur and usually on the lower limbs; this might be so excessive as to resemble a case of severe ichthyosis.

The subjective disturbances of leprosy are malaise, migratory neuralgic pains, anorexia and depression of both the mental and physical faculties. General hyperhidrosis occurs at times as well as fever, the latter resembling various forms of malaria. All of these symptoms are exaggerated during an exacerbation. Paresthesia and neuralgic pains are associated with the nerve form.

Leprosy of the eyes is such an important subject that a short description should be given of the usual clinical manifestations. In all types of leprosy the eye is frequently involved and occasionally quite early in the disease.

In the nerve type of leprosy we frequently get excessive lacrimation. This is followed by a marked xerosis causing atrophic shrinking of the mucous membrane and various distortions of the lids. Through paralysis of the lid muscles and inability to close the lids drying of the cornea follows, with exfoliation of the epithelium, deep infiltrates in the parenchyma and involvement of the interior of the globe. Surgical intervention is frequently necessary. In the nodular type of leprosy we find nodules developing in the conjunctiva, in the cornea and in the iris. Iritis is common in the later stages. The deeper nodules in

Digitized by Google

the cornea have a tendency to ulcerate and frequently we find involvement of the entire uveal tract. This ends in shrunken, painful globes which requires enucleation.

DIAGNOSIS

Well-advanced cases of nodular leprosy are easily diagnosed. The characteristic leonine expression can seldom be confused with anything else. On the other hand, however, early stages of nodular leprosy may somewhat resemble syphilis or lupus. Both the large and small forms of nodular leprosy occasionally simulate multiple benign cystic epithelioma and xanthoma tuberosum multiplex.

When only erythematous or pigmentary changes are present a positive diagnosis must be made by the course of the disease and the observation of sensory changes. This is particularly exemplified in the generalized evanescent type which very closely resembles certain manifestations of erythema multiforme. Only careful investigation of the sensory disturbances will be of value in differentiating ringed leprous lesions from other ringlike cutaneous eruptions; this also applies to the hyperpigmentary and depigmentary forms.

The condition known as lepra mutilans must be distinguished from syringomyelia. In the latter disease there is a dissociation of sensation, and other evidences of leprosy are wanting. In doubtful cases, a portion of the involved nerve may be removed for the purpose of demonstrating the presence of the bacilli; this diagnostic measure has frequently proved to be quite unsatisfactory.

In obtaining material in cases of nodular leprosy to serve the demands of laboratory measures of investigation, a nodule may be excised or a portion of it removed with a biopsy punch. The method which has given us the best service is as follows: The nodule is first incised with a cataract knife and through the opening a small curet is passed deep into

Digitized by Google

the affected area. The material thus removed is smeared over the usual glass slide and stained by the customary acid-fast method. Should the bacilli be present in large numbers, further work is unnecessary; but in those instances in which only a few organisms can be found, cultural procedures and animal inoculation may be resorted to in order to distinguish them from the tubercle bacillus.

In the nodular and mixed type of leprosy, even when syphilis is excluded, the Wassermann reaction is frequently positive. It is positive in almost all cases with leprous antigen. In the anesthetic type it is usually negative, and in those cases in which the reaction is positive it is much weaker than in the other forms. In all types of the disease the luetin reaction is negative unless the condition is complicated by syphilis.

REPORT OF CASES

Case 1.—Jim, aged 34, born in Honolulu, has been in the Isolation Hospital for seven years. He is married, his wife is in good health. His three children all died in infancy. His wife's uncle had leprosy. He came to California from the Hawaiian Islands nine years ago, and at that time had one perforating ulcer on the sole. Nodules developed soon after. He now has an unusually severe type of nodular lepra of the face, body and limbs. No hair appears on the face; the hair on his scalp is thick, dry and prematurely gray. Leprous nodules are on the hard palate. On the body the eruption consists of grouped lenticular papules, a few tuberous growths and some ulcers. The ulcers are most numerous on the hands, where they are the result of burns. There is atrophy of the testes. Atrophy of the limbs is beginning and anesthesia of the limbs is progressing. There are distinct leprous nodules in the left palm and many pigmented spots. Many perforating ulcers are on the feet. The right eye shows infiltration and edema of the temporal side of the ocular conjunctiva with a small patch of whitish infiltration of the contiguous portion of the cornea. There is no involvement of the pupillary area of cornea and the sight is good. The left eye shows similar involvement of the ocular conjunctiva, most marked at the lower temporal border of the limbus. The cornea is clear and sight is good. Wassermann negative with syphilitic antigen and positive with leprous antigen.

Digitized by Google

CASE 2.—James, a colored man, aged 63, was born in Maryland. He went as cook with the Army to the Philippines and returned to California in 1899. The eruption appeared in 1908 as miliary nodules over his face. Later nodules developed in the eyes. There is still hair on brows and lids. The nodules on the face have been absorbed. His body is clear. The skin on the backs of his hands is shiny, thickened and there is much of the usual tumefaction with some scattered nodules. There is some muscular atrophy, but sensation is still good. The skin of the legs is dry, shiny, scaly and darker than the rest of the body. His right eye was enucleated three years ago to relieve the pain which resulted from the presence of leprous nodules in the cornea. His left eye shows nodular thickening on the center of the upper lid. There is a grayish white ring of opacity surrounding the cornea which is broadest at the superior aspect and is similar to an arcus senilis. Punctate gray opaque spots appear through the center of the cornea. The sclera shows the irregular pigment of the African races. Wassermann negative with syphilitic antigen; positive with leprous antigen.

CASE 3.—Fong Gong, a Chinese, aged 47, shows the nodular type. On the face the nodules are very large and are most numerous on chin, cheeks and brows. He has the saddle nose and leonine expression. The hair on his scalp is normal, but has disappeared from his brows and lids. His ears are enlarged and anesthetic. Many large comedones are in the nodules on the nose and cheeks. His hands show much tumefaction, with the characteristic dark brown skin with a bluish tinge. His palms show the characteristic dryness. There is partial anesthesia of the hands, but muscular atrophy is not marked. The skin of his trunk, particularly of the back, shows a diffuse thickening, with exaggeration of the normal markings and a diffuse confluent macular fawn-colored eruption. Scattered nodules of a deeper brown hue can be seen over the affected area. This condition was much more marked a few years ago and is an excellent example of elephant skin. Anesthetic areas are scattered over the body and some of the nodules are anesthetic. There is a diffuse thickening of the skin of the legs, with dark brownish discoloration and wrinkling, and a nodular eruption on the sole. Complete anesthesia of the feet exists. A perforating ulcer is on the ball of the right big toe. Nodules on the right eyelids are so large as to mechanically hinder their opening. The right eye shows quadrilateral atrophy of the globe. There is applantation of the cornea with numerous grayish cicatrices. Even light perception is gone. The left eye shows grayish white infiltrates of the cornea in various stages of activity. There is photophobia. Partial sight remains.

Digitized by Google

Case 4.—Bill, aged 34, a sailor, born in Honolulu of English parents, has been in the Isolation Hospital for three years. The trouble started four years ago as a thickening of the nose and ears. The skin on his face is crapelike and yellowish gray. The normal markings are exaggerated. There is xanthelasma and right facial palsy, with a constant rhythmical contraction of the muscles about the right eye. The lids are normal except for the right palsy. The conjunctiva of the globes is injected. The hair in the brows is greatly diminished. The ears are enlarged and the skin over them is shriveled. Sensation on the face is delayed and decreased. There is also decreased sensation on the forearms and hands, mostly in distribution of the ulnar nerves. Thenar and hypothenar eminences are atrophied. The palms are dry and the normal markings accentuated. The fingers are thickened and clubbed and the skin is shiny. The color here is browner than that of the rest of the body. The skin of the feet is brown and shiny and the soles are deeply pigmented in places. There are no sensory changes. On the forearms and legs are a dozen subcutaneous nodules, rather poorly defined, the skin over them being a bit elevated, and over some there is slight redness. These last a few weeks, disappear, and are then followed by others. These are anesthetic, and leprous bacilli are present in them.

Case 5.—Dan, aged 30, born in Greece, came to America thirteen years ago and has been in the Isolation Hospital for four years. Symptoms were first noticed in 1910 as lesions in the eyes. Later he had papules on cheeks and thighs, and excision of one of these papules showed numerous acid-fast bacilli. Later he developed muscular atrophy of the hands. He now has lepra nodules sparingly distributed over his face. The hair has fallen from the cheeks and entirely from the brows. Nodules appear on the soft and hard palate. There are a few nodules on the backs of his hands on a skin which is reddish brown, dry, shiny and crapelike. His palms are dry. Atrophy of the thenar and hypothenar eminences exists, but there is still much muscular power and sensation in the hands is still good. The center of the cornea in the right eye is the site of an ectatic scar with many long blood vessels from the surrounding sclera. The anterior chamber is deep. The pupil is irregular from an old iritis. The left eye is similar to the right. He counts fingers with the right eye and light perception with the left. Wassermann was negative with syphilitic antigen and positive with leprous antigen.

Case 6.—Ah Fong, aged 33, born in Canton, has been at the Isolation Hospital for four years. Dull reddish-brown macules appear on face. These are fading. Areas of dark brown pigmentation are on the thighs; the skin of thighs,

Digitized by Google

legs and feet is scaly and dark brown. Sensation is diminished, especially on the lower limbs.

CASE 7.—Yee Foo, aged 57, has been in the Isolation Hospital for twelve years. For five years before his entrance the patient had an eruption on his face of the nodular type of leprosy. The nodules have been large and numerous on the face, but nearly all have resoluted, leaving a dark brown pigmentation, especially on the cheeks. The hair is still in brows and lids; the ears are normal. No marked change in sensation exists on the face. It is many years since these nodules have shown active signs. The skin on the body is dry, wrinkled, shiny and with little change in color. The palms are dry. There is some contraction of the little fingers and some muscular atrophy. There is also delayed and decreased sensation. These changes in the hands are recent, showing the condition to be active in the nerves and thus producing a mixed type of leprosy. The right eye is negative except for a few old scars. The left eye shows injection of sclera, most marked above and below. A grayish-white infiltrate of the cornea extends 4 mm. from the upper limbus. The lower portion of the cornea shows a few whitish spots of infiltrate. The iris is thickened and discolored; sight is diminished.

CASE 8.—Frank, a Chinese, born in Canton, aged 32, has been in the Isolation Hospital for one and one-half years. The trouble began three years ago with loss of feeling in the hands; then macules appeared on the face. Since that time these have cleared. Some areas of anesthesia are on his face and remains of an indistinct macular eruption appear on the lower part of his back. These areas are hyperesthetic. A fading erythema is on the thighs and legs. These lesions are indistinct, browner than the normal skin, a bit crapelike and very dry. There is decreased and delayed sensation. The ulnar nerves are enlarged. The fingers are contracted and clubbed; the palms are dry and the thenar eminences are atrophied. The interossei are markedly atrophied. The hands are anesthetic, eyes negative. No lesions appear in his mouth.

CASE 9.—Pedro, aged 40, born in Alcapulco, Mexico, has been in the Isolation Hospital for twenty-five years. Both ocular globes were enucleated three years ago. The right lower lid shows marked ectropion; the upper lid is normal. The conjunctiva of the lids is smooth, dark red and without nodules; the left lids are similar. There is short, sharp, nonrhythmical contraction of the muscles about the mouth, and shriveling of the skin over both cheeks, about the angles of the mouth and of the chin. The patient has claw hands and the muscles are markedly atrophied, but there is very little change in the nails. The legs are

Digitized by Google

atrophied. The skin is scaly and dark reddish brown. The patient has foot-drop from paralysis of the peroneal and tibialis anticus. The toenails are somewhat atrophied.

CASE 10.—Lem Him, aged 50, born near Canton, has been in the Isolation Hospital for eight years. The disease is of the nerve type. His face looks normal, but the skin is almost completely anesthetic. The brows are normal. There are pigmented spots over the trunk. His hands show marked muscular atrophy and the skin is completely anesthetic. Many digits have been absorbed. Three contractured fingers remain on the right hand. All phalanges on the left hand are more or less absorbed. The skin is wrinkled on the back of the hands and somewhat reddened. The ulnar nerves are enlarged. The legs are atrophied and the skin in places is pigmented. The right foot is clubbed. The feet and legs are anesthetic. The testes are atrophied. The right eye shows an arcus senilis and a small pterygium from the nasal side.

CASE 11.—How King, aged 54, born in Canton, has lepra mutilans. As an example of the mummifying type of the lepra, the following case serves as an example. Both eyes are blind from atrophy of globes. The nose is flat from destruction of the cartilaginous and bony structures and partial closure of the nostrils. The skin of the body is brown and wrinkled. The thighs and legs are very dark and scales are large, the condition simulating a severe type of ichthyosis. The hands are badly deformed, the fingers contracted into the palms and wrists flexed. There is very little absorption of the phalanges. The fingernails are atrophied. The toes are contracted and feet are clubbed. Some of the toenails are hypertrophied, some are atrophied and some are absent. This man is helpless, has been confined to his room for many months, and yet seems no nearer death than a year ago.

CASE 12.—P. P., an old railroad employee, aged 40, born in Greece, has been in America for thirteen years and in the Isolation Hospital for seven years. This is an example of mixed leprosy. Large flat pale nodules are scattered over the face, particularly on the forehead. This man is blind. The palpebral apertures on the right side are smaller than on the left. The skin of the lids is thickened and pale and cilia are missing in places. No hair is in the brows. There is a quick, jerky, horizontal nystagmus. The globes show quadrilateral atrophy with applantation of the corneas, which are opaque, and the anterior chambers are abolished. Light perception is present. The skin of the entire body is dry and a bit scaly. There are nodules and resoluted nodules on the forearms as well as scars from old ulcers. The hands show the nerve type of the disease, with atrophy of muscles and

Digitized by Google

contractured little fingers. The hands and forearms are anesthetic and tactile sensation is gone. The nodules on the face are not anesthetic.

CASE 13.—Mike, aged 34, born in Greece, has been in America for six years and in the Isolation Hospital for two and one-half years. He gives a history of fever for a year. Then he noticed an eruption of the nodular type on his forehead. Large, bright red nodules are on the face, especially on the forehead and cheeks. No lesions appear on the nose and some hair is still present in the brows. There is no change in sensation of skin of face. This man has had several exacerbations, and during the attacks the nodules are much larger and the color is much brighter. Dark reddish-brown nodules appear on the forearms, wrists and backs of the hands; also atrophic scars and stains from absorbed nodules. There is no muscular atrophy in the hands, but there is delayed sensation. The ulnar nerves feel quite large. On the body nodules are scattered over the back. On the anterior surfaces of the thighs there are scattered pigmented and atrophic areas. Over the buttocks and posterior surfaces of the thighs are grouped nodules and deep stains. On the legs, particularly the lower third, are large and small nodules and a few small nodules appear on the soles. The larger nodules are anesthetic. The right eye shows at the temporal side of the cornea a few injected blood vessels. The left eye shows edema of the cornea, pericorneal injection and a pinguecula at the nasal side. There is some pain in the eyes and photophobia. The edema of the cornea is an early symptom of subsequent ulceration.

135 Stockton Street—1107 Stanyan Street.

Digitized by Google

THE ETIOLOGY AND TREATMENT OF LEPROSY

ERNEST DWIGHT CHIPMAN, M.D.
SAN FRANCISCO

It may be granted to be axiomatic that the more complete our knowledge of the cause of a disease the more perfect our prophylaxis and the more rational our treatment. The more we have to deal with conjecture concerning etiology the more uncertain our efforts at control and the more empiric our treatment.

A review of recent progress in the treatment of leprosy necessarily goes hand in hand with a recapitulation of advances made in the search for data relating to its propagation and transmission.

While the lepra bacillus of Hansen is generally conceded to be the specific cause of the disease, its route of entry is unknown, and many important questions concerning contagion remain unsettled.

The theory of direct hereditary transmission is practically disproved.

The precise manner in which leprosy is acquired is as yet unsettled. The theory that the disease is caused by the eating of decayed fish apparently has fewer and fewer adherents, although prior to the successful cultivation of the bacillus it was argued that the bacillus could not lead a saprophytic existence because no medium could be found on which it would grow.

That the disease is spread by direct inoculation would seem improbable from the uniformly negative results in numerous human and animal experiments.

The part played by insects in the dissemination of leprosy has received much attention of late.

Currie, working in the Hawaiian Islands, concluded that mosquitoes feeding under natural conditions on

Digitized by Google

patients with nodular leprosy so rarely, if ever, imbibe the lepra bacillus that we can exclude them as one of the ordinary means of transference of this bacillus from lepers to the skin of healthy persons. The reason for this is that the mosquito in biting goes directly to blood vessels and hence gets blood unmixed with lymph.

The same observer, in a study of flies in relation to the transmission of the disease, found that certain varieties of flies when given an opportunity to feed on leprous fluids will contain the bacilli in their intestinal tracts for several days, and concludes that while the present state of our knowledge does not permit us to determine whether such insect-borne bacilli are or are not capable of infecting persons whose skin and mucosa are thus contaminated, we are, until we have more accurate knowledge, justified in regarding these insects with grave suspicion.

At various times the gnat, the bedbug, the flea and other insects have been under suspicion. A significant circumstance in this connection is that 55 per cent. of the cases in Heiser's series (to be referred to later) had previously been infected with scabies.

While our judgment as to the rôle of insects in the transmission of the disease may be held in abeyance pending more conclusive results, it is fair to state that the experimental evidence to date squares perfectly with logical reasoning. If, for example, the mosquito were responsible for the spread of leprosy we should look for a much higher incidence. On the other hand, the disease has been associated from time immemorial with defective hygiene, bad surroundings, filth, crowding, etc., and this idea fits in more nearly with the suggestion that the fly, the bedbug, and possibly other agents, as the acarus of scabies, are the real carriers.

A striking fact in relation to contagion is that so often among individuals living in close proximity the

Digitized by Google

disease is not communicated from one to another as from husband to wife or from hospital patients to attendants, nurses and physicians. According to Manson,

> Probably intimate personal contact, and certain concurrences in the phases of the disease with special conditions which are as yet unknown, and which, for all we know, may concur only at long intervals in the intercourse of any two individuals, are necessary for the successful communication and acquisition of leprosy. The simple implantation of the bacillus does not suffice.

A point of major importance in connection with contagion is the determination of the period at which the disease is most readily transmitted. Campana contends strongly that contagiousness disappears with full development of the disease. Dyer corroborates this view to the extent of admitting that the virulence lessens with the duration of the disease and interprets the trophic type as evidence that the disease is more or less effete. In any scheme of national control and segregation of lepers it would seem only just that this fact be considered and segregation made more or less complete according to the degree of infectiousness manifested. Certainly many cases of nerve leprosy in which no organisms are demonstrable in the nasal secretion are not comparable with active nodular cases in infectivity.

We may summarize our etiologic findings as follows:

1. Leprosy is caused by the lepra bacillus though it does not fulfil the postulates of Koch.

2. The disease is not hereditary.

3. The ability of the leper to transmit the disease differs according to the various phases of the disease.

4. The receptivity of an exposed subject varies with diverse physiologic circumstances.

5. The rôle of insects as intermediaries is as yet unproved though certain of them must be regarded with suspicion.

Digitized by Google

6. The disease is most readily propagated where dirt prevails.

TREATMENT

There are two distinct aims in treatment; the first has to do with prophylaxis, the second with the relief of symptoms. Prophylaxis should be considered both in relation to the individual and the community. From the individual standpoint personal cleanliness and a condition of such good health that resistance in general is high would seem the best safeguards. From the community point of view, in addition to the maintenance of proper standards of sanitation, there at once arises the question of segregation. In those countries in which segregation has been enforced the number of lepers has steadily decreased.

Undoubtedly the greatest precautions should be observed in keeping lepers' quarters well screened as well as in adopting any measure designed to keep them free from contact with any of the insects under suspicion of acting as carriers.

The symptomatic treatment is naturally considered under such separate heads as general and local.

General Treatment: A review of the substances employed in the many century old search for a specific is not at all necessary. The efforts of recent years have had much to commend them in many cases from the standpoint of analogy. Curiously enough, however, the more plausible the analogy the less fruitful the results.

Reasoning by analogy, serums would seem promising although an immunizing serum has not yet been found. Carasquilla of Bogota prepared a serum by withdrawing blood from a leper's veins at the height of the febrile period when the blood was at its maximum toxicity. From this a leprous serum was separated and injected a few hours later into a horse, three injections being given at intervals of ten days. After another ten-day period a serum was obtained which was injected into the patients. Although he claimed

Digitized by Google

good results, other workers were unable to obtain anything more than transitory improvement and even this was ascribed to the reaction which can be obtained from normal serum. According to Crocker there has been, in some cases, a diminution of the infiltration after the use of leprous serum, but it has been transitory and the injections are not free from danger.

Of the vaccines employed those of Clegg and Duval are the best known. In spite of the fact that reaction followed their use the results of neither have been really curative.

Tuberculin also gives rise to a reaction in lepers and this fact was thought to be an indication for its use. It was found, however, that instead of destroying bacilli it liberated them. Coley's fluid has also been a disappointment.

Leprolin, a substance made from a bacillus which proved to be not the bacillus of leprosy, was speedily found wanting.

Nastin, to which Dyer aptly applies the term "near vaccin," was prepared by Deycke, who cultivated a streptothrix from cases of nodular leprosy. He did not consider this the lepra bacillus, but from it he extracted a well-defined neutral fat to which he gave the name nastin. This, when combined with benzoyl chlorid and injected into a leper, caused a bacteriolysis. Various results, some good and some negative, were obtained. In general, nothing conclusive came from it.

Salvarsan has had extensive trials, the results of which have apparently brought the unanimous conviction that it is of exactly the same service as arsenic.

Snake venom and antivenomous serum have both been used, but the basis of their employment was superstition and the results were what might have been expected.

Radiotherapy has influenced individual nodules favorably, but while doing this it has apparently aided

Digitized by Google

in the dissemination of the process, and its use is now deprecated by most writers in this field.

Of the purely medicinal remedies many have been proclaimed efficacious if not curative. A few may be mentioned, as mercuric chlorid, ichthyol, europhen, arsenic, strychnin, the salicylic group, creosote, sodium cacodylate, potassium chlorate, red mangrove bark, iodin salts, gurjun oil and tuatua, a Brazilian plant cultivated by the United States Department of Agriculture because of its repute in leprosy. These are but a few of the many remedies which have been tried, and while in many cases much amelioration of symptoms has been observed, none of these remedies has approached the position of a specific. It is moreover to be noted that they are not for the most part symptomatic remedies, in that a special indication exists for the use of any one. They are simply "good for leprosy." Potassium iodid apparently aggravates the disease.

From this list one remedy has been purposely omitted or rather set apart for consideration by itself. Chaulmoogra oil is the one substance which, while not perhaps specific, has best stood the test of time. The great difficulty has been that, to secure effects, large doses are required and few persons can tolerate the drug in sufficient quantity for an extended period. The stomach ultimately refuses to tolerate it in most cases in which it is administered in adequate dosage. To obviate this feature it has been tried hypodermically but it has been absorbed with difficulty and fat emboli have sometimes resulted.

Recently the injection of a mixture of chaulmoogra oil with camphorated oil and resorcin has been employed by Heiser in the Philippine Islands. The mixture consists of

Chaulmoogra oil	60 c.c.
Camphorated oil	60 c.c.
Resorcin	4 gm.

Digitized by Google

The camphorated oil was added to make a more readily absorbable substance and the resorcin was added because of the fact that Unna had reported excellent results from the chaulmoogra oil-resorcin combination.

In a series of twelve cases only nine patients took the treatment throughout the prescribed period. The net results in the series were as follows:

Apparent cures	11.44 per cent.
Apparent clinical recoveries....	44.44 per cent.
Showing marked improvement..	33.33 per cent.

The details of treatment, to quote from Heiser, are the following:

> The injections are usually made at weekly intervals in ascending doses. The initial dose is 1 c.c. and this is increased to the point of tolerance. Much difference exists among the cases as to the amount of the mixture which they are able to take. In some cases a few cubic centimeters produce marked reactions in the lesions, accompanied by fever and cardiac distress. Sometimes it is better to reduce the amount of the dose and inject at more frequent intervals. The object sought is so to regulate the dose as to prevent reactions of too violent a character. Quicker results are also apparently obtained when it is possible to inject the mixture into large leprous deposits or to divide the dose by injecting it into a number of smaller infiltrations. Attention is drawn to the fact that no strychnin was used. Many writers have regarded strychnin as an essential part of the chaulmoogra oil treatment. Saline purgatives are freely employed. Two per cent. hot sodium bicarbonate tub baths are prescribed every other day. Those who take prolonged baths regularly seem to improve more rapidly than those who do not.

Local Treatment: The importance of active local treatment must not be minimized. This is especially true in the early stages, in which, according to some authorities, the disease can be arrested by radical surgical treatment followed by cauterization.

Viñeta-Bellaserra affirms that the infiltration of lesions often coincides with febrile exacerbations, digestive disturbances, etc., and has found that the destruction of the lesions with thermocautery or

Digitized by Google

galvanocautery causes an immediate improvement in the adjacent lymphangitis as well as in the constitutional symptoms.

Combined general and local treatment: Unna claims several cures from a combination of local and constitutional measures. His treatment consists of the internal administration of ichthyol in ascending doses, while an ointment of 10 per cent. pyrogallic acid in lanolin is employed for inunction into arms and legs twice daily. At the same time a 10 per cent. chrysophanic acid ointment is rubbed into the cheeks and the trunk, while a plaster consisting of chrysophanic acid, salicylic acid and creosote is applied daily to the forehead and chin. This treatment is continued for one month and is followed by a course of warm baths before it is resumed.

Certainly the prompt, free excision of a single macule or tubercle of leprosy in the absence of any constitutional signs would seem to be definitely indicated, on the ground that it may be a primary focus from which the virus has not yet been disseminated.

The Treatment of Special Symptoms: For the restoration of sensibility and muscular power in the anesthetic forms, nerve stretching and nerve splitting has been practiced with success in some instances.

Perforating ulcers are treated on ordinary surgical lines. Treves has recommended a preliminary softening with a paring down of the thickened epidermis followed by a filling of the sinus with a cream of salicylic acid and glycerin to which 2 per cent. phenol (carbolic acid) is added. The dressing consists of a device rather like a corn plaster, which is designed to remove the pressure from the part.

Some cases of perforating ulcer have been healed by stretching the plantar nerves.

The question whether the existence of leprosy does or does not interfere with the success of surgical operations must be answered in the negative. As a

Digitized by Google

matter of fact not only in perforating ulcer but in various conditions, as laryngeal stenosis, tracheotomy, iridectomy and the removal of necrosed bone, surgical intervention has often been resorted to with no untoward results.

To recapitulate: Individual prophylaxis includes correct hygiene and close surveillance of possible insect carriers. Community prophylaxis demands segregation.

Medicinal treatment is altogether empiric though the future possibly holds some specific in store. At times cure is spontaneous.

At present the chaulmoogra oil-resorcin combination given subcutaneously promises best results. Climate, food and good hygienic conditions influence all cases favorably. The importance of hot baths must not be forgotten. Several baths daily are undoubtedly of value. An Old Testament writer records the cure of Naaman of his leprosy after seven dips in the Jordan. Whether we view this literally or as a bit of symbolism it nearly epitomizes our modern treatment.

240 Stockton Street.

REFERENCES

Crocker: Diseases of the Skin, Philadelphia, P. Blakiston's Son & Co., 1903.

Manson: Tropical Diseases, Chicago, Chicago Medical Book Co.

Heiser: Leprosy—Its Treatment in the Philippine Islands by the Hypodermic Use of Chaulmoogra Oil Mixture, Rep. U. S. P. H. S., 1914, Supplement 30.

McCoy: A Statistical Study of Leprosy in Hawaii, U. S. P. H. S. Bull., No. 66.

Currie: Mosquitoes in Relation to the Transmission of Leprosy, U. S. P. H. S. Bull., No. 39; Flies in Relation to the Transmission of Leprosy, U. S. P. H. S. Bull., No. 39.

Hollman: Heredity Versus Environment in Leprosy, U. S. P. H. S. Bull., No. 39.

Macleod: The Present State of Our Knowledge of the Bacteriology and Pathologic Anatomy of Leprosy, Brit. Jour. Dermat., October, 1909.

Dyer: Jour. Trop. Dis., Editorial, November, 1914; Discussion, Tr. Internat. Cong. Dermat., New York, 1907.

Campana: Proposals for Diminishing the Diffusion of Leprosy, Tr. Internat. Cong. Dermat., New York, 1907.

Viñeta-Bellaserra: Traitement du Léprome par la Perforation et la Cautérization Ignée, Tr. Internat. Cong. Dermat., New York, 1907.

Digitized by Google

ABSTRACT OF DISCUSSION

ON PAPERS OF DRS. MONTGOMERY, MORROW AND LEE, CHIPMAN AND O'NEILL

DR. A. A. O'NEILL, San Francisco: [Dr. O'Neill had no written paper. In part, he said:] In 1878 it became necessary to establish a place for lepers in this country, and there were eighty-two lepers in the institution over which I now have control. This number has been diminishing gradually, until we now have fifteen. The patients admitted to the institution have been brought to San Francisco from other places. Two factors are to be taken into consideration in this connection, and one of them is from the economical standpoint. It is said that if the British government took care of all the lepers in its possessions it would probably bankrupt the government. Then we have to combat medical superstition. The old idea is that diseases such as this were exhaled from the body of the patient, and only yesterday I heard of an instance in San Bernardino in which after a leper died and was removed they destroyed the house by fire. Such a sentiment as that in a community is very hard to meet and combat.

There are 238 known lepers in the United States, and I for one would strongly advocate placing these persons on one of the islands off the coast of California, and put that island under the control of the Public Health Service. There was an effort made to establish a leprosarium in the state of Washington, but local feeling was so strong they had to abandon the project. As I said before, it is a matter of education. Of ninety-five human beings who were inoculated with leprosy, or leprous material, one developed it. That means that we are unable to inoculate the ordinary laboratory animals with these diseases; and that would show there is little or no danger from the ordinary nerve type of leprosy. Where the leper has no open lesions, and no open organism is found, and no discharge from the nose, I think he should be allowed to pass around in the community. At the same time, in Norway, the humane method of segregating them in their own homes, does not result in the separation of the members of a family, and the patient is more content to be with his own family. The number of cases described as arising from contact are so few they can be neglected. In other words, a leper with no open lesions might be permitted to remain with his family, and those having open lesions should be segregated.

DR. JOSEPH ZEISLER, Chicago: Ever since our country acquired the Hawaiian Islands and the Philippines, I have felt that our interest in the subject of leprosy has increased. In this respect I have even felt that in the curriculum of the medical schools some instruction should be given in the subject of leprosy. I have omitted during no course I have

Digitized by Google

given in the Northwestern University, the presentation of this subject in one or two full lectures, but, unfortunately, merely in a didactic way.

Our great predecessor, Jonathan Hutchinson, tried to base a genealogical study of this subject among people living on the seashore. The famous fish theory started with Jonathan Hutchinson—and perhaps it has remained with him.

As long as our treatment of leprosy is the same as it is today, we shall have to continue to hammer at the general hygienic treatment of each case, and await the day when a specific treatment of leprosy may come. In the meantime, as long as our therapeutic efforts are so feeble, we must look to prophylactic measures, and I am in favor of isolation and colonization of lepers. Our laxness in handling leprosy is lulling the public at large into a false feeling of security. It is not in the same category as scarlet fever and smallpox. The incubation of leprosy is so long that we cannot tell when the disease may develop. It has been eliminated in certain lands by segregation. We have no means of stamping out leprosy by vaccination, as in smallpox. Then, too, it is a national affair, and our national government has not been asleep in this matter by any means. I believe we should also have state action; and there should be a leprosarium in every state where such cases could be collected and segregated.

We have in Chicago, I think, at all times at least a dozen cases; and when we meet with such cases we are absolutely helpless as regards the management. The health board does not know how to take care of them. Recently we had a sensational case in Chicago where a leper was discovered and imprisoned; he escaped from confinement and later was recaptured. I believe our present attitude on the subject of leprosy must be of interest, of necessity, to our national and our state governments, namely, that we advise isolation and care of every case in proper hospitals and sanatoriums.

Dr. George W. McCoy, Honolulu: In relation to the public control of leprosy through segregation, it may be largely a matter of geography. In certain communities leprosy does not spread. Judging by the reports of New York dermatological societies, there are from forty to fifty cases at all times in the city of New York; and unless I am mistaken, no case has been of local origin. They are all imported. Obviously measures different from those required in, for example, Hawaii, would suffice. Then we must consider the type of leprosy. In Hawaii, where we have considerable experience in segregation, in a general way we segregate the nodular type and the ulcerating nerve cases. Abroad that is the distinction made by law in some countries. The

Digitized by Google

pure nerve type cases are not usually segregated; we have a system of paroling those patients. The paroled leper is required to report to a government physician once every three months. He is at once recommitted to the leper hospital if he becomes a menace to the public health.

Dr. Morrow made no mention, in discussing the diagnosis of the disease, of the examination of smears from the nasal cavities. Ordinarily we do not find the bacilli early in the course of the disease in the nasal cavities; but occasionally you can find them when they cannot be detected elsewhere. Recently we had two cases of what appeared to be pure nerve leprosy in which a large number of bacilli were found in the nasal scrapings without difficulty.

Our method of making smears may be of interest. We grasp the nodule between thumb and index finger, squeeze the blood out of it, take a safety-razor blade, make a short incision in the bloodless nodule, and scrape out some of the nodule juice, in which the bacilli can be demonstrated if present. If that fails, we excise a piece of skin. Of course we throw away the blade after using once.

In connection with the treatment of leprosy I would like to emphasize the great help that may be given to lepers by surgical means. This refers to the work of Dr. Goodhue, medical superintendent of the Molokai Settlement, and Dr. Hollmann, in immediate charge of the patients at the Honolulu station. Amputation of hopelessly ulcerated fingers and toes is advisable in many instances.

Then there is the great frequency with which tracheotomy is required. I suppose I help Dr. Goodhue with at least twelve or fifteen tracheotomies in a year among a leper population of six hundred.

Dr. Zeisler spoke of incision. We had in Hawaii recently the youngest case of leprosy of which we could find any record. The patient was a child 19 months old, born of leper parents. A nodule appeared on the forearm and was excised by Dr. Goodhue; we are going to watch that case with much interest. We do not believe there is any good reason for believing that the child will be materially benefited by the removal of the lesion. I do not believe that there is any such thing as a recognizable "initial lesion" of leprosy.

Dr. A. Ravogli, Cincinnati: I agree with the views of Dr. McCoy on the possibility of initial lesion in leprosy, and I find this is validated by some findings, especially in Sardinia. Frequently it begins with an ulcerated wound of the foot. That the mucus of the nose is loaded with bacilli, lepra bacilli in the most of the cases, there is no doubt; and it is now claimed that a patient spitting in the streets or elsewhere, someone walking there without shoes (as many children do), with a lesion of the skin, is liable to be inoculated with lepra.

Digitized by Google

There is a custom in the Philippines of having a very large cigar hanging from the ceiling; and every member of the family takes a few puffs at it in passing. Very likely this custom has been indicted as one of the methods of spreading leprosy.

Leprosy is very slightly contagious, yet is growing by contagium. Colombini in his work, "Leprosy in Sardinia," refers to a woman who had been suffering from leprosy for twenty-two or twenty-three years, living and working all the time in the same house with two brothers. She was taken to the leprosarium and so far her brothers had not shown signs of leprosy. On the other hand, there is no doubt that leprosy shows its contagious nature. In New York at a meeting of the American Dermatological Association we were shown a case of an Italian with tubercular lepra. I asked him where he had taken leprosy. He said that four or five years previously he had come to New York perfectly well. In New York he had got the disease, and his brother living with him was infected in the same way. This shows beyond doubt that leprosy is contagious; and for this reason the patient must be isolated.

Lama contends that the *pulex penetrans* (a flea) is the insect that carries leprosy. He claims to have found the first lesions of lepra as diffuse red patches in the limbs, or a tubercle, or ulcerated nodule.

In my opinion lepers must be segregated and left together, and not be in contact with others, because of the dangers obviously present for the propagation of this disease.

Dr. Richard L. Sutton, Kansas City, Mo.: I should like to ask Dr. McCoy and Dr. Schmidt a question regarding the status of the bacilli which give rise to the nerve and cutaneous lesions. Charles J. White's statistics, and the results of Nichol's investigations would indicate that some particular strain of the *Spirochaeta pallida* is responsible for syphilis of the nervous system. Is it probable that some certain strain of the bacillus of leprosy also exhibits a predilection for nervous tissues?

Dr. Schmidt: I might say in answer to the question of Dr. Sutton that the serologic examination of leprosy is not of great value. It is quantitative rather than diagnostic. Some years ago some work was done in our university in relation to rat leprosy and human leprosy; and it was found that serologically they were the same. Bacteriologically they were the same.

Dr. Everett S. Lain, Oklahoma City: In my examination several years ago of several thousand Indians in Oklahoma, and also in recent years for different skin diseases, I made particular search for leprosy, and have not found any; at least, I have not made such a diagnosis, although the Indians have many of the other common diseases. There-

Digitized by Google

fore, I have concluded that this is an imported disease which has not reached the American Indians, who are inland.

Dr. Howard Fox, New York: In regard to biblical leprosy, I feel convinced, as stated in my chairman's address, that there is no reference in the Old Testament to any disease which can positively be recognized as the leprosy of the present day. If it is impossible to recognize a description of leprosy in the 59 verses of the 13th Chapter of Leviticus, how much less possible is it from some of the miraculous accounts of the disease, as when Moses put his hand into his bosom at the command of the Lord and on drawing it out we read "behold his hand was leprous as snow." Similar to this is the leprosy of Miriam and of Gehazi, the servant of Namaan, the Assyrian general who on account of disobedience was told by Elisha that "the leprosy therefore of Namaan shall cleave unto thee and thy seed forever; and he went forth from his presence a leper as white as snow." Furthermore, the leprosy cured by our Savior after the sermon on the mount cannot be considered as examples of modern leprosy, but might well have been psoriasis.

Regarding the control of leprosy, a great many dermatologists at the present time feel that the disease can only be properly controlled by the federal government and not by the individual states. In New York state we do not have the stringent laws concerning leprosy that are enforced in Pennsylvania and Massachusetts. In consequence there are practically no cases at large in either of these states, while there are probably always forty or fifty cases in New York City, and some would double this estimate. In a paper read before the New York Academy of Medicine in 1911 I made the statement that I had personally examined thirty cases within a period of one year in New York City, though it must be said that a special search was made at this time. It would be wise, it appears to me, in making laws for the isolation or control of lepers, to distinguish between the harmless, anesthetic cases, and the nodular cases in the ulcerating stage.

Dr. Douglass W. Montgomery, San Francisco: As regards the initial lesion in leprosy, I think it is frequently an erythematous leprid. I have seen such a lesion on the forearm in its early stages and have watched the disease creep up the nerves from it. Of course the erythematous leprid may not be the sole initial lesion in leprosy. That leprosy may also enter through an ulcer of the leg or foot, or by causing an ulcer in this situation, would be also a probable eventuality.

I do not think there is any doubt of the desirability of establishing a national leprosarium. The important question then arises, What place should be chosen for the establish-

Digitized by Google

ment of such an institution? Should it be Hawaii, Louisiana, San Francisco or some other place? I think it should be in some place where leprosy is not endemic. We do not know the mode of transmission of leprosy. We know it enters a region, increases with fair rapidity, and then dies out. We know it died out in Central Europe, and we surmise that it did so because of segregation. The same thing took place in Norway, where we think its decrease was due to the segregation of the afflicted, and to the increasing well being of the people owing to the influx of wealth brought by tourists. But there may be climatic conditions which influence the disease, and this is the important point. The leprosarium should be located in a locality where leprosy does not thrive, where it is not endemic, and where the disease runs little chance of increasing, and the afflicted individual runs the best chance of recovering.

As to the miraculous cure of Naaman, I would say that there are naphtha and sulphur deposits on the Jordan, which I think are now being exploited. Naaman was told to go and bathe seven times in the River Jordan, and he probably went into the sphere of influence of the naphtha or sulphur and was cured of the itch.

Dr. Howard Morrow, San Francisco: There is no state law which provides for the segregation of lepers in California. There is a city ordinance in San Francisco which compels us to notify the health department, and they are compelled to keep them in the Isolation Hospital. But if we kept at the Isolation Hospital all the lepers we see from time to time, we would have an institution there to rival Molokai. In the last three weeks I have seen three subjects in various stages of leprosy. One came from Honolulu, with a nodule on her eye and typical leper hands; nothing else. That woman was advised to return to Honolulu and go to Molokai. Yesterday a woman was sent to me from Mexico; she arrived at 10 o'clock, and I saw her at noon; I told her husband what the trouble was, and at 5 o'clock she was on the way back to Mexico. The other was a Spanish boy, and I advised him to return to the Philippines. If he does not, we will put him in the segregation colony. I have kept him here longer than I intended in order to have his appear before the society.

Dr. A. W. Lee, San Francisco: I am entirely unfamiliar with the laws dealing with lepers in different parts of the United States, but, no doubt, every one who has seen a great number of cases of leprosy has had his humane side strongly appealed to. It is difficult for one to force himself to the opinion that isolation is absolutely necessary in all cases. The first patient presented here is of a very high type of mentality, extremely sensitive and readily amenable to reason. If it is possible to give semi-isolation for this young man, it would be a very advisable thing to do.

Digitized by Google

Dr. A. A. O'Neill, San Francisco: When I read the work by Duval and Harris of how they had taken the serum and passed it through Japanese mice, and then increased it so that laboratory animals could be inoculated, I concluded that we might be able to settle how it is transmitted. But since this meeting has started I have learned that Duval has repudiated much of that work.

I have been struck by the fact that leprosy is a disease of the semicivilized. You find it along the coast of other countries to be sure; but it does not thrive in an uncongenial soil. Where leprosy was introduced by a Chinaman into Hawaii, it became ripe. Such is the history of other diseases introduced among such people. It was the same with leprosy in Australia, where the leper made his appearance among the aborigines.

In Hong Kong, in 1894 (speaking of the danger of transmission), I was shown the latrine where the coolies went; it was explained to me that bubo was taken up by those coolies who went barefooted.

I am convinced that more thorough study of the transmission of this disease, such as by the bedbug, and like means, will bring us finally to a solution of the question. I have yet to see a case which had its origin in California. I saw one reputed case in a woman, but there is a question in my mind as to whether she was telling the truth in saying she had not been outside of the state.

To give you an idea of how they try to make their ideas conform to your wishes or views, the man here said he was a native Indian and had not been out of the state; but I recognized that he was a Hawaiian. I was to be shown a native Californian who had not been out of the state.

I would suggest more humane treatment of these persons. One of my patients absconded and went to Denver, where he was placed in the pest house. They had a large number of patients. Every patient with smallpox wanted to flee from the hospital. This man recalls the fact that the number of soldiers returning from the Philippines afflicted with leprosy must not be overlooked by us. We must remember that, visiting such foci, it is not unusual to become infected; and we must remember that leprous husbands have lived with wives, and vice versa; and there are children born to them, notably among the leprous parents at Molokai. The danger of contracting the disease is a very remote one to my mind, when we have this direct evidence of ninety-five people being inoculated without results.

Dr. Ernest Dwight Chipman, San Francisco: I am glad Dr. O'Neill spoke about the transmission of leprosy by parasites. I believes the more we study the surroundings of leprous patients the more we will be convinced of the possibility of various insects being an important etiologic factor.

Digitized by Google

CASES FROM THE SKIN CLINIC OF LELAND STANFORD JR. UNIVERSITY SCHOOL OF MEDICINE

HARRY E. ALDERSON, M.D.
SAN FRANCISCO

CASE 1 (Serial No. 4266).—Leukoplakia of tongue and palate in an Irish painter, aged 68. The dorsum of the tongue is almost entirely occupied by a very thick hyperkeratosis (Fig. 1). There is a similar process on the hard palate. The lesions have existed for over thirty years. The patient has cerebrospinal syphilis (of the meninges), diabetes mellitus and chronic nephritis. These diagnoses have been established by complete physical and the usual laboratory examinations.

CASE 2 (Serial No. 26856).—Tuberculosis verrucosa cutis and epithelioma simulating blastomycosis in a Chinese laundryman, aged 55. For five years a slowly spreading granulating area has existed on the dorsum of the left hand (Fig. 2). The patient has been applying various kinds of Chinese remedies. Occupying most of the dorsum of the left hand there is a well-circumscribed "granulating" mass. Elevated about 3 mm. and slightly detached from it, a similar smaller lesion is over the third metacarpophalangeal knuckle. Scattered thickly through this area are numerous small deeply seated discharging pustules. The resemblance to blastomycosis is very striking. Repeated studies of fresh material, cultures and animal inoculations failed to reveal blastomycetes.

Sections of tissue, taken superficially as well as deeply, showed a well-developed squamous cell epithelioma (Professor Ophüls). Animal inoculations resulted in the development of tuberculosis (guinea-pig). The patient was given Roentgen-ray treatment (Coolidge tube, 4½ inches spark gap, target 10 inches from lesion, 40 M. A. minutes, filtered through 1 mm. aluminum), in May, 1915. He never returned. Our social-service department reported that he had left for China.

CASE 3 (Serial No. 11436—11).—Lupus vulgaris of scalp in an Italian woman, aged 68. The history is very indefinite. The patient states that her trouble began in 1904 (?) in a pustule which was surrounded by an inflammatory zone on

Digitized by Google

Fig. 1.—Leukoplakia of tongue.

Fig. 2.—Tuberculosis verrucosa cutis and epithelioma simulating blastomycosis.

Digitized by Google

Digitized by Google

her scalp. Her health always had been good. It is probable that the lesion existed for years before it was noticed. She presents typical nonulcerating lesions involving almost her entire scalp, forehead and face as far as the middle of the nose, almost the entire right cheek and right ear. The hair of her scalp is entirely absent in the affected areas. When she was first seen, in 1907, the diseased areas were covered with seborrheic crusts with marked infiltration beneath the same. The disease has slowly advanced downward over the face.

Some facts were of special interest. The Moro tuberculin reaction was positive. One injection of Koch's old tuberculin (0.00001) was promptly followed by severe focal as well as local reaction, headache and malaise. She has had Roentgen ray (Coolidge tube), 4½ inches spark gap, target 10 inches from the skin and a 1 mm. aluminum filter interposed.

August 1914, 32 M. A. minutes (followed by pronounced erythema).

October, 1914, 36 M. A. minutes (followed by pronounced erythema).

January, 1915, 26 M. A. minutes (followed by pronounced erythema).

As the radiodermatitis subsides, cicatrization extends in the diseased areas and the lupus foci seem to diminish in number; but still there remain many active lesions and the prognosis seems almost hopeless.

Case 4 (Serial No. 22373).—Epithelioma responding to Roentgen-ray treatment in a Greek laborer, aged 26. In 1907 a small nodule appeared on the right cheek near the nose. This soon ulcerated and advanced in an outward direction, followed behind by healing. Syphilis was excluded. When first seen, the patient presented a thin, depressed scar 2 by 4 cm. extending horizontally under the right lower eyelid, with a deep ulceration (about 12 mm. wide and 12 mm. deep) at its outer termination adjacent to the outer canthus. This deep cavity was the result of the use of a cauterizing agent of unknown nature applied by some physician. There was no adenopathy. Under Roentgen-ray treatment (Coolidge tube) 4½ inches spark gap, target 10 inches from the skin and a 1 mm. aluminum filter interposed, the cavity steadily closed until now it has almost completely healed over. At present there is a deep red erythema due to the last treatment four weeks ago.

The following is a record of the Roentgen therapy:

December, 1914	72 M. A. minutes
January, 1915	30 M. A. minutes
February 1915	36 M. A. minutes
March, 1915	76 M. A. minutes
April, 1915	36 M. A. minutes
May, 1915	30 M. A. minutes

Digitized by Google

CASE 5 (Serial No. 13334).—Alopecia universalis in a boy, aged 12, who was born in California. The disease began in 1909 with several typical patches of alopecia areata. Within a year the entire scalp and also the eyebrows and eyelids became completely devoid of hair. The loss of the hair of the eyebrows was preceded by redness and slight swelling there. Off and on small abortive tufts of hair an inch long have grown over the occiput only to fall out in a short while. Under the chin there has remained constantly very fine lanugo hair, but the hair inside the nostrils and ears has been lost. The family history is negative.

Complete neurologic examination by Doctor Schaller revealed no evidence of organic nervous disease, although it was noted that the boy was rather irritable and of a neurotic disposition. He is of average intelligence and appears strong physically. He has adenoids and an enlarged left tonsil. His teeth are irregular, deformed and decayed. The postcervical glands are enlarged and the left epitrochlear gland is palpable.

A complete physical examination revealed no other abnormalities. The blood Wassermann reaction is negative. Owing to the difficulty of doing anything with the patient, other blood examinations and other laboratory work (excepting urinalyses) so far have not been possible. However, it is hoped to accomplish this soon.

CASE 6 (Serial No. 16845).—Recurrent erysipelas of the face with concomitant impetigo contagiosa in a girl, aged 13.

During the past year the patient has had four or five repeated attacks of typical impetigo contagiosa, with erysipelas involving the entire right upper half of the face, accompanied by the usual constitutional symptoms. At one time the process was complicated by the development of a right parotid abscess which had to be treated surgically.

Each time the condition has subsided after several injections of polyvalent streptococcus vaccine (50,000,000 dosage) and the usual local treatment. No foci could be found in the sinuses, but there exists a chronic lacunar tonsillitis, and both inferior turbinates are hypertrophied and in contact with the septum. The rôle of the streptococcus in these two affections is very evident here.

CASE 7.—Keratosis palmaris and plantaris hereditaria in two boys, (aged 2 and 4 years respectively) both presenting typical very marked lesions on the palms and soles, which lesions have been present since birth. The mother, several uncles and aunts and grandfather have the same abnormality. The condition is always better in the summer.

240 Stockton Street.

Digitized by Google

ABSTRACT OF DISCUSSION

Dr. George M. MacKee, New York: I would advise the use of the Roentgen ray in the case of keratosis plantaris et palmaris. I base this opinion on the fact that several examples of keratosis (ichthyosis, erythrodermia ichthyosiforme congenitale, keratosis palmaris et plantaris, senile keratosis, hyperkeratosis, callositas, etc.) have been cured in this manner in Dr. Fordyce's clinic.

Dr. Oliver S. Ormsby, Chicago: About fourteen years ago we treated a patient with keratodermia, whose lesions were more extensively developed even than those present in the case demonstrated by Dr. Alderson. Very shortly after birth, in this instance, the palms and soles were almost black in color and the thickening was pronounced. Radiotherapy was employed in moderation, with beneficial results. We feel, however, that this method of treatment should be employed in this disorder with the greatest of care.

Dr. Joseph Zeisler, Chicago: An interesting feature of the case of keratosis lies in its hereditary element. The mother who has both hands affected, shows two little boys with the same affection. In a case like this which has come to my notice, I told the father that if he had children the girls would be affected. This is an observation which is not original with me, that hereditary features are transmitted. As regards treatment, I endorse what has been said here as to the effect of the Roentgen rays; but as Dr. Alderson has asked for suggestions, I should ask him to try the internal administration of thymus and watch the effect carefully.

With regard to the case of lupus vulgaris of the scalp, I should like to investigate the history of this disease. It is against my experience to think that this disease should have started so late in life. I should think it has been there for a number of years; and the earliest features, such as nodules, were not noticed. In a case of lupus commencing after 40 years, I should always doubt the diagnosis. I would like to suggest a treatment I have employed recently in an almost identical case of leukoplakia of the tongue and palate. I have often used radium, but it is not entirely satisfactory. I have frozen these patches with carbon dioxid snow to the point of exfoliation, with a good deal of success.

Dr. Everett S. Lain, Oklahoma City: As to Roentgen-ray treatment of keratosis, my experience has proved that the slow method does not give good results; but the intensive doses do. I would give this patient intensive doses, or push it to the second point of reaction and then cease treatment.

Dr. Richard L. Sutton, Kansas City, Mo.: After trying practically all of the various methods that have been recom-

Digitized by Google

mended for the treatment of leukoplakia, I have found radium by far the most efficient. An exposure of from twelve to twenty milligram hours is usually sufficient to bring about a cure. Unfortunately, in some instances, as in this one, the areas are very extensive, thus rendering the choice of a suitable plan of treatment a difficult matter.

Alopecia may result from any one of a number of causes. In some instances a general intoxication may give rise to an alopecia which is clinically identical with alopecia universalis. In this particular instance, however, to me the symptoms are suggestive of syphilis, and I should like to ask Dr. Alderson if a serum test has been made. With respect to the treatment of alopecia areata, I have found small doses of hexamethylenamin (gr. 5 to 10 after meals) beneficial. It is probable that while some cases of alopecia areata are due to trauma or to direct ganglionic injury, the majority are due to infection, either of the ganglion or of certain nerve trunks, with a specific microorganism. It is probable that this is the reason why drugs like hexamethylenamin prove efficient.

Dr. A. J. Markley, Denver: I have observed a number of cases of leukoplakia in the hands of Dr. Levy of Denver treated by fulguration. The reaction is quite severe but subsides rapidly and is the most satisfactory method that I have so far observed.

Dr. Howard Fox, New York: My experience is that of nearly every dermatologist, that practically nothing can be done to cure leukoplakia. All that can be done is to have the patient use a bland mouth wash and avoid smoking. I have never had permanent results even from the galvanocautery. I have recently seen a case of leukoplakia temporarily improved by radium (treated by a colleague). When last seen the lesion was slowly returning to its original condition.

Dr. Ernest Dwight Chipman, San Francisco: I do not know that Dr. Alderson knew it, but the boy with alopecia had a positive Wassermann and had specific treatment for a considerable period five or six years ago when I first saw him.

Digitized by Google

FACTITIOUS DERMATOSES

OLIVER S. ORMSBY, M.D.
CHICAGO

The object of this paper is to record a group of cases of self-inflicted dermatitis, which have occurred during the last several years in the practices of the late Dr. James Nevins Hyde, the late Dr. Frank Hugh Montgomery, and myself.

Much confusion exists concerning the dermatitis herein described, and the physician who is originally consulted in these cases rarely is able to recognize their character, commonly on account of prejudice, through personal acquaintance with the patient or family. It is on account of this failure to appreciate the possibilities in these cases that it has been thought worth while to record this group of thirty-four cases.[1]

Opinions differ among men who recognize these, and some able observers have recorded cases as being of spontaneous origin, in hysterical persons, which later have proved to be factitious. That there are some cases in which a spontaneous origin can hardly be doubted, there is no question. Yet the large majority, according to most observers, have an associated, though often unrecognized, factitious origin.

In public practice, paupers and others are not infrequently seen who inflict injuries for the purpose of securing financial or other aid. In Europe, the professional malingerer is not uncommon, and the degree of skill exhibited by these people in imitating disease is at certain times high. In this country this class of cases is uncommon.

1. A number of these were collected and the histories written by the late Dr. Montgomery for a paper which he read before a medical society. These are included in this report for the reason that no publication of the report was made.

Digitized by Google

There is another class in which existing skin diseases are aggravated by irritation, and prolonged by the patient for various reasons. All of these types are excluded from this paper.

The major portion of the patients recorded here were women and poor girls of a highly neurotic temperament, and showing distinct stigmata of hysteria. As will be noted from the case histories, the lesions occurred on accessible parts of the body, such as the breasts, abdomen, and limbs; all were areas accessible to the right hand. The right arm was commonly exempt, except in left-handed individuals. The lesions occurred suddenly in all cases, and usually developed during the night, when the patient was alone; and several of the patients were able to predict the exact spot where a lesion was going to develop, much to the astonishment of their friends.

An interesting feature, in a large number of cases, was the fact that the disease was initiated through accident. This may have been trifling, and the dressing employed in the treatment gave the suggestion to the patient as to how to carry out the deception.

The symptoms in the cases vary from a simple erythema to vesicular, bullous, gangrenous and ulcerating lesions, with their sequels.

A number of cases are on record, and there occurs one in this series, in which tissue destruction has been marked, and amputation of fingers, the whole hand, and even the arm has been performed, with the full consent of the patient.

The methods employed by these patients are varied, and are at times exceedingly difficult to detect. A long list of animal, vegetable and mineral substances is included in this category. Those most commonly used are phenol (carbolic acid), croton oil, cantharides, mustard, various acids and alkalies, including lye, tartar-emetic ointment, cresol and compound solution of cresol. Other methods employed have been

Digitized by Google

burning with matches, with pieces of hot metal, or with bottles containing very hot water, and friction with the fingers, sandpaper, and other rough substances. In one patient whom I saw, intense dermatitis was aroused by rubbing tobacco briskly into the skin of the genital region. The character of the lesions and the intensity of the inflammation depend not only on the agent employed, but also on the strength of the solution, the duration of the application, and the tissue resistance.

ETIOLOGY

The cause of these peculiar actions in the individual must be sought in derangement of the nervous system. All the intricate processes concerned in hysteria could be brought forth to explain the condition here. In some cases there is exhibited a desire on the part of the patient to escape from disagreeable duties or surroundings; in others, to gain attention, sympathy, interest or pity, or to achieve notoriety. In some instances, no possible explanation can be given, and it may be, as suggested by Pernet and Towle, that in a certain proportion of cases there is a dual personality, or a subconscious state, in which the lesions are produced, while in the normal condition the patient has no recollection of the acts performed in the other state.

Towle[2] explains the production of these lesions from the standpoint of hysteria, on the ground that the initial wound which occurs in numbers of cases serves as a suggestion to the patient, who afterward enters into a somnambulistic state, in which he is powerless to control the suggestion of producing wounds by any means at hand. On emergence from this state, the patient has no memory of the somnambulistic period or of the production of the wounds, and honestly believes the wound appeared of itself.

2. Towle: Gangraena Cutitis Hysterica: A Report of Four Cases Occurring in Hysterical Individuals, with a Review of Ninety Cases in the Literature, Part of Which Were Artificial, the Remainder Being Reported as of Spontaneous Origin, Jour. Cutan. Dis., 1907, xxv, 477.

Digitized by Google

Pernet[3] concludes that in some instances there is an altered personality, whereby the self-infliction of wounds is not remembered by the patient at the time they are examined. In all these cases hysterical stigmata can be found.

Galloway[4] states that the more these cases are investigated, the less probable does their spontaneous origin become.

Jelliffe,[5] in a discussion of hysteria, states that the various cutaneous manifestations occurring in hysteria, such as bullous dermatitis and other lesions, are, in the vast majority of cases, artefacts; yet there remain a few in which this factor cannot be proved.

In the major portion of recorded cases the factitious element is present, though it has not been proved in many of them, for various reasons. Many cases of pemphigus gangrenosus of supposedly spontaneous origin have been proved to be factitious by the discovery of the materials used, and later by confession of the patient. That spontaneous cases do occur is strongly supported by Van Harlingen.[6]

Corlett[7] reported a case having lesions of this type. The patient was a hysterical girl, aged 15. This case was recorded as one of spontaneous gangrene.

White[8] recorded a case of recurrent, progressive, bullous dermatitis in a hysterical subject. This case was well studied, and in the opinion of the reporter was one of spontaneous occurrence. In the discussion which followed the reading of the paper, opinion was divided as to its spontaneous or factitious origin.

Illustrating the difficulties encountered in arriving at conclusions on this point, may be mentioned a case

3. Pernet: The Psychological Aspect of Dermatitis Factitia, Jour. Cutan. Dis., 1909, xxvii, 547.
4. Galloway: Allbutt's System of Medicine, 1911, xi, 54 and 55.
5. Jelliffe, in Osler and McCrae: Modern Medicine, 1910, vii, 846.
6. Van Harlingen: Recent Contributions to Our Knowledge of the Hysterical Neurosis of the Skin, Jour. Cutan. Dis., 1903, xxi, 403. An excellent summary of recorded cases of factitious and spontaneous eruptions occurring in neurotic patients, with extensive bibliography.
7. Corlett: Jour. Cutan. Dis., 1897, xv, 551.
8. White: Jour. Cutan. Dis., 1903, xxi, 415.

Digitized by Google

recorded by Shepherd.[9] This is the record of a patient, aged 20, who had suffered with a recurrent bullous eruption of the face for four years. After much study, the reporter concluded that the eruption was feigned. The possible connection of this eruption with the menstrual epoch was discussed. The interesting feature was its localization on the face alone.

An interesting case of factitious origin was described by Stelwagon.[10] This is the record of a female patient, aged 19, who had produced lesions on the forearms and legs, over a period of several months, by constant rubbing with the finger. The object of the patient was not to create sympathy, but there was an irresistible impulse to rub the skin, which apparently created an agreeable sensation.

Another instructive case was recorded by Weber.[11] This patient, a woman aged 37, was suffering with hysterical functional nervous affections, and was also a malingerer. The lesions consisted of bullae, with superficial ulceration, and were located on the front of the abdomen. Their duration was seven months. A starched bandage was applied, in order to detect deception. The bandage, however, became loosened, probably by deflating the abdomen, by means of which the patient was able to introduce her hand under the upper anterior portion. In this area bullae developed, and on examination some dark specks were detected in the raised epidermis over the bullae. These specks proved to be powdered cantharides. In spite of the finding, the patient would not acknowledge the deception.

Weber also reported a patient who produced spurious Roentgen-ray ulcers by means of hydrochloric acid. In this patient an appendectomy had been performed, as well as three other abdominal operations. On account of menorrhagia, she was treated

9. Shepherd: A Case of Recurrent Bullous Eruption of the Face, Probably Pemphigus Hystericus, Jour. Cutan. Dis., 1906, xxiv, 164.
10. Stelwagon: Arch. Dermat., 1882, viii, 236.
11. Weber: Brit. Jour. Dermat., 1912, xxiv, 78.

Digitized by Google

with Roentgen rays, and later developed ulcers which spread over the whole abdomen, and which were produced as stated above.

Shepherd[12] recorded four cases which are instructive:

1. Gangrenous patches on the skin of the arms, in a woman aged 30, produced by some heated object. No hysterical stigmata.

2. Woman, aged 44, suffering with a bullous dermatitis, produced by some blistering agent, probably cantharides, phenol, acetic or other acid; the object was to avoid disagreeable work.

3. Woman, aged 28, hysterical stigmata present. Bullous lesions produced by cantharides. Object, to excite sympathy and interest.

4. Woman, aged 24; no hysterical stigmata. Gangrenous patches on foot and leg. Agent used not discovered. Original lesion due to an accident, subsequent ones to design.

Pernet[13] recorded two cases of trichotillomania, associated with other factitious manifestations. These occurred in young women aged respectively 20 and 22.

Illustrating each side of the contention are cases recorded by Wende.[14]

The first case, in a young woman aged 17, had its beginning following the application of phenol to a wart situated on the back of the right hand. Subsequent to this, gangrenous areas began to develop on other parts of the body.

In the second patient, aged 18, the disorder followed an accident sustained while sleigh-riding, the first lesions appearing as a group of vesicles on the nates. In this case, the recurrences were always confined to the original area. The peculiar location of the lesions, in a situation hard to reach by the hand, and the character of the lesions, placed the case, in the mind of the reporter, beyond the possibility of being factitious.

Two affections described under other titles should be mentioned here. Under the title "Zoster gangrenosus atypicus," Kaposi[15] described two cases of cuta-

12. Shepherd: Jour. Cutan. Dis., 1897, xv, 543.
13. Pernet: Brit. Jour. Dermat., 1915, xxvii, 85.
14. Wende: Dermatitis Vesico-Bullosa et Gangrenosa Mutilans, Jour. Cutan. Dis., 1900, xviii, 548. Report of two cases having a hysterio-traumatic origin.
15. Kaposi: Arch. f. Dermat. u. Syph., 1889, xxi, 561.

Digitized by Google

neous disease occurring in hysterical young women. He later described others, making a total of eleven.[16] In these cases, recurrent lesions appeared, consisting of grouped vesicles and papules, followed by crusting. In some cases, by coalescence, large areas of gangrene were produced, which, after the sloughs had separated, were followed by cicatrices, which often showed keloidal developments.

Rona[17] (Budapest) stated that in 1889 he reported a case of zoster gangrenosus atypicus, and attempted to solve its etiology. Since that time his views had radically changed. In four of the five cases under his observation there were definite hysterical stigmata; in four, the lesions followed a trauma, two from a needle wound of the finger; one followed operation; one followed abortion. In two of the cases, caustic soda was found secreted. That all the cases were identical with those described by Kaposi he believed there was no doubt, and that the differences in the descriptions of the disorder are due to the different chemical substances used in their production, and the concentration, mode and place of application.

Recently, a group of cases has been described under the title "dermatitis symmetrica dysmenorrhoica," by Matzenauer and Polland.[18] They report six cases, occurring in persons of unstable mentalities. The lesions were usually linear, and developed rapidly. The authors set up a hypothesis explaining the spontaneous occurrence of these lesions on the ground of some change in the internal secretions.

Kreibich[19] discusses the same subject, but proposes the term "gangrenosa neuroticum dysmenorrhoica."

Friedeberg[20] describes a case, under the title "dermatitis symmetrica dysmenorrhoica," of a woman, aged 30, who suddenly developed bullous lesions on the

16. Kaposi: In Crocker's Diseases of the Skin, Ed. 3, 1903, p. 534.
17. Rona: Arch. f. Dermat. u. Syph., 1905, lxxv, 256.
18. Matzenauer and Polland: Arch. f. Dermat. u. Syph., 1912, cxi, 385 and 454.
19. Kreibich: Arch. f. Dermat. u. Syph., 1913, cxiv, 165 and 172.
20. Friedeberg: Arch. f. Dermat. u. Syph., 1913, cxiv, 173.

Digitized by Google

cheek, which in the course of a few days became crusted and healed without scarring. At the next menstrual period, a similar process occurred on the trunk.

Mathes[21] discusses the etiology of these cases.

Török[22] (Budapest) discusses the cases of dermatitis symmetrica dysmenorrhoica, and concludes that the most probable explanation of these cases is the presence of a factitious element.

DIAGNOSIS

The diagnosis is usually not difficult to one familiar with cutaneous disorders, since the lesions, though of a simple inflammatory nature, are different from those of any recognized disorder. The most important points are the following:

The lesions occur within reach of the patient's hands, and are usually most numerous on regions easily accessible to the right hand. These include the anterior surface of the body, the left arm, forearm and hand, the lower extremities, and the right side of the face and neck. As a rule, the palms and soles, eyelids, mouth, nose, ears, scalp, and genitals are spared.

The lesions are always sharply outlined, and of unusual, often fantastic, shape. They appear suddenly, at irregular intervals, usually one or two at a time, and run a fairly rapid course. When fluid caustic is used, it frequently happens that one or more drops run down the skin from one of the lesions, leaving a characteristic streak, which is usually lighter in color and shows a more moderate degree of inflammation than the patch from which it depends. When the caustic is applied with a needle or pin, as is frequently the case in gangrenous areas, the border shows a finely jagged or serrated edge, made by the numerous punctures in the advancing border. When gangrene is present, it is usually very superficial, and is separated

21. Mathes: Arch. f. Dermat. u. Syph., 1913, cxiv, 185.
22. Török: Arch. f. Dermat. u. Syph., 1913, cxiv, 185.

Digitized by Google

from the normal skin by a narrow, vivid red line. The fingers, nails or some article of clothing are often stained by the agent employed.

Subjective sensations, usually pain and burning, may be greatly exaggerated by the patient, who will cringe or jump at the slightest touch during the examination, and will complain bitterly about the distress caused by the simplest and lightest of dressings. On the other hand, some of the areas are largely anesthetic, and some of these individuals like to exhibit their ability to endure pain. Many of the patients enjoy mystifying their medical attendants by predicting, from twelve to twenty-four hours in advance, the exact areas on which new lesions will occur, claiming that during this period they experience in these areas a sense of heat and burning and other abnormal sensations.

The impulse one has is to confront the patient immediately with the charge, and there are several who advocate such procedure. While occasionally this terminates happily, in the majority of cases it probably would fail, in which case it would work an injustice on the patient, her friends and the attending physician. A plan which I pursue is to instruct the patient in methods of treatment, and during the instruction impress her with the idea that there is no question whatever as to what has produced the lesions, and that if she will faithfully apply the remedies suggested, and as faithfully avoid using anything else, she will make a prompt recovery. Then have the patient watched with care, using at a later date, if necessary, fixed dressings; that is, dressings which cannot possibly be removed without detection; or, if driven to extreme measures, take the patient to a hospital, where she can be kept under strict surveillance, both day and night, when, by complete disappearance of the lesions and the nonappearance of new ones, the diagnosis is proved. This, however, does not reveal the causative agent. In an intelligent patient, the appeal to her pride

Digitized by Google

and self-respect has weight. In certain of the cases no impression is made by such an appeal. It may be that a number of these patients belong to the group described by Pernet and Towle, those who really do not know that they have inflicted the injuries.

Further aids to the diagnosis may be found in the general characteristics of these patients, the unusual history of the disorder, the discovery of anesthetic areas, especially of the fauces and conjunctiva, and other evidences of hysteria.

CASE REPORTS

CASE 1.—The patient whose lesions are shown in the illustration was being attended in one of the hospitals of the city for ulcerated, gangrenous lesions occupying the entire length of the left hand, forearm and arm. I saw her in consultation at the hospital. She had been examined by a number of physicians, and apparently was much pleased at the prospect of having another examination. There were several physicians and hospital attendants in the room when the patient was examined. During the undressing of the arm, the following history was elicited: At the beginning, an apparently serious lesion occurred on one finger. A physician was called, who dressed the lesion and stated that he would redress it the following morning. On the second visit, a similar lesion was found immediately above the bandage. This was dressed, and, either daily or on each alternate day for several weeks, new lesions continued to appear immediately above the bandage. They were painless, occurred suddenly, always developed during the night, and the first lesion seen by persons other than the patient was a bulla. The bulla would soon become dark, gangrene would follow, and either deep or superficial ulceration result. At the moment of examination, lesions varying from superficial scars to deep ulcers, through the various stages, were present. They were irregularly shaped, and varied in size from that of a split pea to that of a silver dollar. During the time the dressings were being removed, the lesions were carefully examined, but no questions were asked the patient. She, however, was apparently enjoying the situation and attention. When the dressings were all removed, with no preliminaries, the patient was informed that the lesions were due to the application of phenol made by herself. She was so surprised that before she could master her emotions she admitted the deception, and finally stated that by accident she had learned how to produce the lesions with phenol,

Digitized by Google

and continued the process, as it relieved her from the disagreeable duty of practicing at the piano.

CASE 2.—A case similar in character, location, extent of lesions, and age of patient to the one just described occurred in Indiana, and the patient was brought to me. This happened on a clinic day, and the patient was demonstrated in the clinic. She was a charge in a school, was highly nervous, and showed hysterical stigmata. She had discovered that by mutilating herself she was relieved from work. After a thorough discussion of the case in the clinic, at which time the patient gleaned that her case was understood, she was sent home with the family physician, who, with the aid of the Sister in charge of the school, obtained a confession from her that she had produced the lesions with phenol. After the confession, a prompt recovery took place.

This patient had been treated with potassium iodid and mercury, and ptyalism had been produced.

CASE 3.—Miss J. J. R., aged 28, seen May 27, 1909; duration of the disorder two years; patient of nervous temperament.

The lesions followed an injury, the thumb having been cut while she was slicing meat. The patient stated that the lesions began as red spots, which after several days became dark colored, and finally black. She was very sensitive, complaining when touched. Admitted using phenol for dressing, and knew perfectly well what it meant and what it did.

On examination, the lesions and relics were seen to be located chiefly on the right hand, left breast, right and left forearms (flexor surface), neck and chin. They were of two types, superficial and deep. The superficial lesions showed erythema and crusting; the deeper ones were gangrenous. The lesions varied in size from dime-sized to as large as a silver half-dollar, and were irregularly circular in outline. A deep one on the right knee was well defined and had a smaller lesion joined to it. The scars were similar in shape to the above-described lesions. Those on the right forearm were produced by the use of phenol, by accident; the remainder were identical. There were no lesions on the back or other areas beyond easy reach of the hands.

The diagnosis of factitious dermatitis was made and forwarded to the attending family physician. Four months later, a letter was received from him stating that the diagnosis had been confirmed.

CASE 4.—Miss I. V., aged 22, of nervous temperament, had had the cutaneous disorder one and one-half years. The history obtained from the patient and her mother was as follows:

In the beginning, a finger was burned with nitric acid. The lesion remained open for some time. Three months later an ulcer appeared in the same area. Six months after the beginning, curettage was performed and necrotic tissue

Digitized by Google

removed. One month after the curettage, an incision was made into the hand, after which the lesions disappeared, excepting a small spot. Two months subsequently, the record states, the patient was in good condition. One month later lesions began to reappear. New ones occurred still another month later, and two months subsequent to this they began to appear higher up the arm. The lesions all occurred suddenly and began as blisters.

On examination, the following was noted: The dorsum of the left hand was erythematous, and showed scars from old incisions and lesion relics. One active lesion was present on the side of the face. This was irregular in outline and covered with a brownish eschar. The entire arm and forearm, left side, showed superficial atrophy and scar formation, in irregular areas.

The mother was informed of the diagnosis, and was good enough to cooperate in trying to determine what was being used. Her physicians were also informed, but were skeptical as to the possibility of the disorder being self-inflicted. Eight months afterward, one of the attending physicians reported that, after compound solution of cresol had been found in the patient's stocking, she confessed that the lesions had all been self-inflicted. Following this disclosure, recovery ensued.

Case 5.—Miss F. R., aged 15, had had the cutaneous disorder seven months. The patient was of a highly neurotic temperament and showed marked evidence of hysteria. The disorder began as an abrasion on the left hand, from which lesions spread up the forearm. The early lesions were vesicles filled with semipurulent material. Each new attack was accompanied by marked elevation of temperature, the family stating that it reached as high as 108.5.

Bullae continued to appear from time to time. The day before the patient was examined, a new lesion appeared on the forehead, at which time a temperature of 106.5, as recorded by the mother, was reported. There were never any lesions in the mouth. The patient vomited considerably, but had no nausea. She frequently had spells of fainting; these always occurred when she was with another person.

The patient was right-handed, and was apparently normal mentally; there was no pharyngeal reflex; the corneal reflex was much reduced.

On the forehead a dime-sized, irregular, pigmented, superficial burn was present; healed lesions were present on the left arm; there were irregular hypertrophic scars, with similarly shaped and circular, well-defined, superficial, dried, burned areas on the right arm, in various stages of healing.

Temperature taken at time of examination was normal. Leukocyte count was 8,000. Visual fields were normal and equal.

Digitized by Google

Dermatitis Factitia, Induced by Phenol (Case 1).

Digitized by Google

Digitized by Google

The diagnosis of factitious dermatitis was made and forwarded to the patient's attending physician. A letter received from the latter some months later reported that under the care of a competent trained nurse the diagnosis was confirmed, that phenol was found to be the agent used, and that the patient had made a complete recovery.

CASE 6.—The following patient was seen through the courtesy of Dr. S. C. G. She was seen at the office of the attending surgeon, when lesions such as will be described later were examined, and the following things transpired:

The lesions were dressed by the surgeon, which required about an hour. Throughout the dressing the patient was interested and bore the ordeal without complaint. On completion of the dressing, she had an attack, which she commonly had after each dressing. After a few convulsive movements, she stretched out and became perfectly rigid, lying with her eyes closed for about ten minutes, apparently entirely unconscious. At the end of that time she revived, woke up smiling, and in a short time was ready to go home.

There were many new lesions ready for exhibition on the day of this examination. The lesions, together with the history outlined, bore the imprint of their factitious production. A part of the history of this case was recorded by the attending surgeon in the *Illinois Medical Journal,* 1909, xvi, 657. The abstract is as follows:

The patient was an unmarried woman, aged 28; no occupation. Father living and healthy, aged 60; mother living, but nervous, aged 60. Two sisters died in infancy; one sister living and well, but neurasthenic; two brothers living and well; one of these adjudged insane four years ago; the other, aged 23, strong and well mentally and physically. One sister, who died three months previously, was mentally deficient from the age of 16 to 26, when she died.

Patient's previous history showed she had never been well. At the age of 8 she had had inflammation of the bowels. Always nervous and poorly nourished; had been under the care of a physician for five years for nervous prostration. Menstruation began at the age of 14. For one year the periods were regular, then became irregular and painful. For more than a year there had been a cessation of this function.

The present illness began as a small burn, appearing as a blister about the size of a ten-cent piece, on the right forearm, flexor surface. Two days later, a series of small blisters appeared down the forearm, toward the wrist. In addition, there was a series of scratches on the left forearm, left upper arm, and four 3-inch-long scratches over the chest, between the breasts. All of these had apparently been made with a pin or needle. She denied any knowledge of how they occurred. On the following day, when again seen by

Digitized by Google

the surgeon, she had a number of new scratches over the right hip, which she claimed were made by a cat. After several days, new blisters appeared over the areas of the skin not previously invaded. The lesions that were preceded by scratches showed inflammation along the line of the scratch, then turned white or gray, and a blister formed, filled with clear or cloudy serum. Within a few days the area of blister turned black and dried, forming a gangrenous crust or patch. The lesions not preceded by injury to the skin surface appeared with a slight blush of the skin, followed in a few hours or almost at once by a large blister, sometimes surrounded by smaller ones. During the progress of the disease the blisters varied, some being large and firm, and tensely filled with clear or cloudy serum, occasionally pure blood, almost black in character. Many bullae were multilocular. Some of the bullae were flabby. The lesions were of varying depths. On the lower limbs, large areas consisting of gangrenous, sloughing ulcers occurred. Some lesions persisted for several months, but eventually all healed. The scars were nonadherent and pigmented. The lesions were bilateral, and were situated chiefly on the anterior part of the body, with a few over the gluteal region. Their outline was irregular, some being linear, others nearly square. The mucous membranes of the mouth were free, as were also areas not readily reached by the hands.

This record states that after each dressing and before the clothing had been entirely replaced the patient fell over in a hysterical faint or sleep, which lasted from five minutes to two and one-half hours. The head fell back, the mouth was open and fixed, the breathing was stertorous; the right hand began rubbing over the appendical region; the left hand lay in the lap or hung at the side perfectly quiescent. To control the movement of the right hand, considerable strength had to be exerted. Strong ammonia as an inhalation, cold cloths over the face, or pressure over the ovarian region was necessary to waken her. She always woke up smiling and was ready to walk away.

In the summary, the attending surgeon gave the following points in favor of the factitious origin of the lesions: The patient's unwillingness to go to a hospital or to have a nurse, which relieved her of constant supervision; all lesions appearing on the body only where the hands could readily reach; the apparent enjoyment the patient felt from having the dressings changed; the fact that the patient was able to be up and around and to go to the office for dressings, in spite of the large areas of ulceration.

Notwithstanding all these features, the reporter was not convinced at that time of the factitious origin, but recorded the case as one of pemphigus gangrenosus. This patient was

Digitized by Google

demonstrated at a midyear clinical meeting of the American Dermatological Association, held in 1910, where the usual discussion as to the factitious or spontaneous origin of the lesions occurred.

CASE 7.—A strong, healthy, Scandinavian girl, age 22, presented a peculiar eruption occupying the anterior surface of the right arm from the wrist to a short distance above the elbow. Three weeks prior to examination, she had pricked her finger with a pin; it became sore and painful, and her physician feared blood poisoning. A few days after the accident, she fainted in church. Fearing serious complications, she was taken to a hospital, where she remained two weeks. A day or two after entering the hospital, a small red area, more or less covered by blisters, appeared, which darkened in color and resulted in a few days in superficial necrosis. Several of these areas appeared on the forearm while the patient was in the hospital.

Examination showed the anterior surface of the right arm (the patient was left-handed) to be occupied by about seven separate rectilinear areas of altered integument. These were placed with their long axes in a transverse direction. Roughly estimated, their size averaged from 2½ to 3 inches by 1 to 1½ inches. Each was separated from those adjacent by a strip of normal skin. The borders were well defined, but in places irregular and frayed out. The lesion nearest the hand, opposite the carpal joint, was practically healed, leaving a scar; the uppermost band was the most recent. The lesions from above downward showed the various stages of evolution and involution of a dermatitis due to the application of a solution of phenol. She had evidently first made an application to the wrist, and, being ignorant of the power of phenol, had used enough to cause a fairly deep burn, which resulted in superficial necrosis and ultimate scarring. While lesion No. 1 was under treatment, she caused No. 2 to appear just above the bandage. No. 3 was produced above the bandage which included No. 2, and so on up the arm. The later lesions were noticeably less severe than the first.

It was learned later, from the girl's history and her conduct, that she was a degenerate. She and her sister had the same lover, and, thinking that her sister was receiving too much attention from him, she had taken this means of attracting his interest and sympathy. The lover departed, and no more lesions appeared.

CASE 8.—The patient, Miss M. K., was 18 years of age, of good family, and apparently in good general health, although examination of the urine showed marked albuminuria. The cutaneous lesions had been appearing at short intervals for fourteen weeks. They had disappeared entirely during a week that she had been in the country with a cousin (the subject of the next report), to whom she was very much

Digitized by Google

attached, but appeared again the second day after her return to Chicago.

The lesions were very superficial, sharply outlined, for the most part in the shape of geometrical figures, such as squares, rectangles, or triangles, with clean-cut sides and corners; the diamond-shaped lesion was common. Other areas were somewhat irregular and showed one coarsely serrated or saw-tooth margin. The process, for the most part, did not go beyond the production of acute erythema, though a number of areas were covered with very thin crusts. There were no bullae or vesicles. The lesions were seated chiefly on the face, shoulder, elbow, knee, and only in regions readily accessible to the right hand.

On inquiry of other members of the family, it was found that for a year or more, since she had failed to graduate from the high school with her class, she had been morose, stupid, rebellious, and especially anxious to get away from home to visit her girl cousin in the country. Later, an older sister admitted that she had detected the girl frequently in falsehood, and even in petty thievery of small change from other members of the family. It was noted that she frequently locked herself in her room, in which was a small trunk, which she kept always locked. During her absence, the trunk was opened and her complete outfit of phenol, needles and cloths was found. Even when confronted with these articles, she declared she did not know how they got in the trunk, and that she did not remember ever having used them. After this confrontation, however, no more lesions developed.

Case 9.—Miss B. K., a cousin of the preceding patient, 19 years of age, in fair general health, but suffering from severe headaches, and of general neurotic type, consulted Dr. Montgomery, in 1903, for acne, and for a transitory erythema, of four months' duration, on the trunk. Irregular and various sized areas of hyperemia would appear on the trunk suddenly, and, after lasting from one to three or four days, would gradually disappear. The outline of these areas was for the most part well defined, but in some instances had more of the appearance of the redness produced in a sensitive skin by violent rubbing with the finger. The skin, when tested by rubbing over it a blunt-pointed instrument, showed no evidence of dermatographism. One day she came in, evidently in some alarm, with two pronounced lesions on the body, and one sharply outlined band, 1 inch wide and 3 inches long, on her right cheek. The lesions were of much deeper color than the others had been, and on one slight vesiculation was beginning.

On being accused of producing the lesions herself, she partially confessed, and there was no recurrence of the peculiar erythema.

Digitized by Google

CASE 10.—The patient, Mrs. J. H. W., was 30 years of age, and fond of society. She had been married twelve years, but had never been pregnant. Her husband, who was 25 years older than she, was a minister and circuit-rider, his work taking him away from home a large portion of the time. She was a well-nourished woman of average weight, with some tendency toward hysteria, her physician stated. In December, 1905, she had a hemorrhage from the uterus, which examination showed had come from an ulcer of the uterine wall. Diagnosis of adeno-carcinoma was made and the uterus curetted.

The patient stated that the first skin lesion appeared, simultaneously with the hemorrhage from the uterus, as a small pinkish patch on the face. This appeared suddenly. The color gradually deepened for two or three days, then slowly faded out, leaving a stain, which eventually disappeared entirely. Later, numerous patches appeared from time to time on different parts of the body. During a year and a half she had rarely been entirely free from them for more than a week or two at a time. On the body, many of the later lesions had been of rather severe type, the redness being followed by the appearance of numerous small vesicles, or larger bullae. The contents of these bullae, if allowed to flow over the sound skin, produced new lesions.

On examination, the face showed a number of irregularly shaped but sharply outlined areas of erythema, in varying stages of involution. There were no scars on the face. On the body, especially over the breast and on the left arm and forearm, were numerous sharply outlined areas of irregular, and occasionally fantastic, shapes in varying stages of evolution and involution, including acute erythema, vesicles and bullae on hyperemic bases, superficial necrosis, pigmentation and, finally, a few scars.

She had been in the hands of a dozen or more physicians, and stated that she was generally known in her section of the country as "the medical puzzle." She said she always knew from twelve to twenty-four hours in advance, from certain burning sensations, exactly where the lesions would appear; and that the drawing of a blunt instrument over her skin, as had been done by several physicians to test the reaction, was always followed, in from twenty-four to thirty-six hours, by a new lesion. She was frankly told what the trouble was, but denied all knowledge of how the lesions occurred. Six months later, we learned that there had been no recurrence of the lesions.

CASE 11.—The patient, Mrs. B., was a woman 53 years of age, well nourished and apparently in excellent health, of strong, robust type, with a ruddy complexion, and bright, intelligent, and cheerful in disposition. She had borne six children, five of whom were dead, two of diphtheria and two

Digitized by Google

of tuberculosis. The living child was a frail girl, 8 years of age. The patient was the eldest of nine children. Three of her sisters and one brother died of tuberculosis. There was a further history of tuberculosis in relatives on both sides of the family.

The woman stated that her health was always good up to the time of her marriage, at the age of 18. After the birth of her first child, she had what was considered an unusual form of erysipelas of the head, lasting four weeks. From this date she had had frequent and varied illnesses, including persistent cough, and had proved an exceedingly trying patient to all the physicians in her vicinity. Not long after her first attack of erysipelas, she fell from a wagon and injured her right arm, which had since shown signs of partial paralysis and atrophy, the fingers being flexed on the palm. Careful examination by a local physician and a Chicago surgeon discovered no cause for the condition. Her ability to use the hand varied widely, depending on the attending circumstances. Beginning with the forty-fifth year, there had been some slight irregularity in the menstrual function, which, however, still persisted.

The lesions had been seen by her attending physician at intervals for about eighteen months. The first was an irregular band, about 4 inches wide, extending from the groin to the middle of the inner surface of the left thigh. The patch was of a dark-brown color, with a distinct red areola; the center covered with a slight crust, the outer portions cracking and weeping. Removal of the crust showed a granular-looking surface covered with pus and serum.

The patient was seen daily for a month, during which time new areas appeared on the limbs, many of them extending peripherally as they healed in the center or at one end. During the following month, there were involved both lower extremities, the anterior surface of the trunk, especially about the breast and umbilicus, the right arm, the face. and finally both of the hands, though never both at the same time. The lesions appeared suddenly, and the patient was able to outline accurately the next areas to be involved, because of the pain and burning experienced in those regions. As the lesions disappeared, they left a purple pigmentation, which gradually faded, leaving, as a rule, no scar. At one time the skin remained well for several weeks, during which time, however, her cough became so severe that relief was obtained through sleeping potions.

The patient was examined by numerous physicians, with various diagnoses. Repeated microscopic examinations disclosed no pathogenic organisms. Her attending physician suspected self-inflicted disorder, owing to the fact that the lesions were all within reach of the hands, and that from some of the areas a line of lesser inflammation extended to more

Digitized by Google

dependent portions of the body, suggesting the flowing of a drop of caustic fluid over the skin. This was noted repeatedly, but was explained on the supposition that the exuding serum was responsible for its appearance. Prolonged watching of the patient did not reveal her methods, and she stoutly denied any knowledge of the origin of the lesions.

The examination revealed the fact that the lesions were clearly those of factitious dermatitis, and, reinforced by this assurance that his suspicions were well grounded, the family physician took the husband into his confidence, and the patient was threatened with exposure if she continued her practice. As is usual in these cases, she did not make a full confession, but practically admitted that the lesions had been produced with croton oil, which had been recommended to her for use on her nipples during her first confinement. After cutting off her supply of croton oil, there were no more cutaneous lesions. She had later, however, a phantom pregnancy that kept her physicians busy, was especially fond of medical attention, and had many of the symptoms of hysteria.

Case 12.—A woman, aged 19, married two months, applied for treatment of peculiar lesions which had appeared on her breasts, left upper arm, neck and face. They had been coming, one or two at a time, for five weeks. The first one followed an accidental scratch, to which she had applied an antiseptic liquid given her by a druggist.

On examination, the lesions were seen to be chiefly small, irregular, sharply defined patches of erythema. On the breast were several small bullae surrounded by a narrow hyperemic zone. Subsiding lesions were followed by pigmentation, but no scars were visible. From the under margin of a triangular hyperemic area on the breast there extended downward an irregular band from one-eighth to one-quarter inch wide and 1½ inches long. The inflammatory process forming this band was less severe than that on the area above, and was undoubtedly produced by a drop of liquid escaping and running down over the skin.

The woman had always lived in the country, had never been away from home before, and had come immediately after her marriage with her husband to the city, where they had no friends or acquaintances. He was busy with his work all day, and she was, in consequence, very lonely. The nature of the condition was explained to the husband alone, and he very sensibly recognized the situation and generously stated that he did not blame the girl. He sent her home for a few weeks, and a year later reported that everything had come out all right, and he was greatly obliged for the advice given.

Case 13.—A rosy-cheeked, well-nourished maid, 18 years of age, came to Dr. Hyde's clinic, giving a history of a dis-

Digitized by Google

order affecting the left arm, which had existed for several weeks. She had consulted a number of physicians connected with public charities, particularly those in the County Hospital, where she had been presented at a meeting of the medical staff, for the purpose of securing a diagnosis in what was believed to be an exceedingly obscure disease of the skin. When she appeared at the clinic, her manner was like that of many others of her class, semidefiant and pert, the consultation being preceded by the statement on her part that she had been examined by scores of physicians and no one of them had been able to tell her the nature of her disorder.

The history of the disorder included a description of "blisters" coming irregularly from time to time in crops, followed by repair of the base of the lesions, and the subsequent appearance of new eruptive symptoms in other situations. One or two areas on the forearm strongly suggested the production of the lesions by the dropping of a caustic fluid upon the surface.

The lesions were limited to the left arm, and consisted of discoloration in blotches here and there over the surface, several of these having the shape of a flask with the neck downward in the line of gravity. A few places were the seat of excoriations and crusts. The index finger and thumb of the right hand were stained slightly yellow.

Dr. Hyde made the diagnosis of factitious dermatitis, and the entire arm was placed in a fixed dressing.

One of the students in the amphitheater, after the clinic, informed the patient of the diagnosis made in her case, and she and her mother presented themselves a few days later for the removal of the dressing, and were highly indignant at the charge made in connection with the case. Meantime, however, the lesions had disappeared and no new ones had occurred.

Case 14.—An unmarried girl, 15 years of age, consulted Dr. Hyde for severely ulcerated lesions on the left arm and the right lower extremity, which had persisted for a year, and which had been diagnosed by her physicians as "lupus." She gave a history of agonizing pains, lasting for long periods of time, with nocturnal exacerbation and symptoms of deterioration of the general health, which was distinctly manifested in her cachectic appearance. For relief of her pains, she had received at the hands of the physicians in the state where she resided a series of hypodermic injections of morphin. The pigmented scars resulting greatly disfigured the outer surface of both thighs. After the first consultation, she returned to her home in a neighboring state, and occasionally, at intervals of some months, wrote letters making complaint as to her condition and begging for relief, stating

Digitized by Google

that the ulcers had not healed and that her general condition was much worse.

A free bed was secured for her in one of the hospitals of the city, where she was seen by a number of physicians, all of whom agreed that the ulcers were unique and wholly unlike any they had ever seen before. Some of the ulcers were irregularly shaped, egg- to palm-sized, with indolent floor, scanty secretion, and inactive edges. They had a peculiarly irregular contour, some of them presenting almost a jagged outline. They did not conform to the type of any of the classical ulcers recognized in diseases of the skin.

Arrangements were made for a radical operation — the removal of the ulcers by curettement and cauterization— when suspicion was aroused by the behavior of the young woman in the ward. The nurses notified the intern that she had been seen making applications to some of the ulcers; and, this fact becoming known to the patient, she promptly stole $50 from one of the patients in the ward and escaped from further observation.

In this case it was suspected that the agent employed was phenol, but the patient had acquired a degree of skill sufficient to enable her to produce the ulcer without any of the stains or areas of superficial dermatitis common to this group of cases. She was a degenerate, sallow in hue, menstruating irregularly, and generally cachectic. Her motive was not discovered, but did not appear to be the usual desire to attract attention or elicit sympathy.

Case 15. — A young woman, well nourished, apparently healthy, and comely in appearance, was referred by her local physician because of a peculiar and persistent eruption involving the right breast, right knee and right instep. He had been in charge of the case for several months, and reported that healing of the skin was always followed by a sudden recurrence of the eruption within a short space of time, often during the night. At the time she consulted us, an exacerbation had occurred a few days before.

Upon examination, an extremely interesting condition was seen occupying the anterior half of the surface of the knee, extending from 3 inches above to 4 inches below the patella. The lesion was brownish in color, slightly scaly, and in places, especially at the lower part, showed small areas of erosion, which were moist. The upper border was a well-defined line; the lateral borders were irregular and somewhat frayed out in appearance. The lower border was strikingly peculiar. For the most part it was fairly well defined and horizontal. Near the outer end could be seen two downward projections of brownish discoloration, about 1 inch in length by one-eighth inch in breadth, separated from each other by about three-quarters inch, with concavities directed toward each other. At the lower ends of these projections

Digitized by Google

the discoloration spread out into a small irregular area, with festooning of borders especially marked in the lower part.

The lesion upon the right instep was the size of a hand, and presented the same general characteristics: brownish colorations, slight scaling, occasional areas of erosion, and sharply defined, festooned borders. The lesion on the breast was also similar, with the exception that ulcerations occupied the region of the areola and had practically destroyed the nipple.

A diagnosis of feigned eruption was made, the agent used being a solution of phenol. The method used in the production of the knee lesion, as deduced from the appearance, was as follows: The phenol was applied while the stockings, which were retained by round garters, were on. The upper margin of the stocking was lifted and the solution poured on the skin of the knee, probably while the patient was in a standing position. The agent naturally kept to the sides, and especially downward, where it was arrested by the constricting garter. Under the garter-buckle the acid was enabled to pass further downward along the line of the metal bands which would be present on the inner surface of the buckle, next the skin. Once below the garter, the phenol spread as far as the quantity used would permit.

The patient was evidently neurotic, as was also her mother. The motive seemed to have been a desire to avoid the necessity of working to aid in the support of the family. A confession was not obtained, but under fixed dressings the lesions all disappeared and did not return.

Case 16.—Miss C. S., 28 years old, a recent graduate in medicine, was sent to Dr. Montgomery by one of the surgeons of the hospital in which she was acting as intern. She stated that she had infected her finger three months prior to this date, while doing a necropsy on a man who had died of insanity due to syphilis. Four days after the infection, the finger became sensitive and she pressed out a drop of pus. The finger remained sensitive and slightly swollen, and from time to time she could squeeze out a small drop of pus. A month after the infection, she had the finger opened, but the condition did not improve. A month later (two months after the infection), she had it opened and thoroughly scraped. After this, whenever she dressed it with mercurial ointment for a few hours, the wound would nearly heal; but under ordinary wet dressings there would be recurrence of the inflammation and the pus formation.

On examination, the finger-tip was seen to be slightly swollen and the seat of a small, irregular, ragged, shallow, superficial ulcer, the destruction of tissue apparently not going much below the epidermis. The edges showed evidences of recent irritation from some source. There was

Digitized by Google

no induration, very little infiltration of the base, no local or general adenopathy, and there had been no specific treatment.

The patient was advised to use only a wet dressing and to report in twenty-four hours. During the next month she made three calls, at intervals varying from one to two weeks, stating that nothing had helped her except the local applications of mercurial ointment. This was four months after the infection, and the condition of the finger had not changed, nor had any adenopathy or other symptoms appeared. She was told that unless she let the wound alone we should put on a fixed dressing. A few days later, she received notice of an appointment for which she had been waiting, and the finger promptly healed. A year later, a number of interesting facts in her family and individual history came to light. Two of the members of her immediate family had been insane for a number of years. The patient herself had been guilty of self-inflicted injuries, had at different times manifested marked hysterical tendencies, and on one occasion had tried to commit suicide. She is now an inmate of an insane asylum in the East.

Case 17.—This case does not belong strictly in this list, but is so unusual that it is included. A healthy baby, 2 years of age, was sent to Dr. Montgomery by the family physician for some peculiar lesions which had appeared on the right hand, wrist and forearm. These had been appearing at intervals of a day or two for two weeks. The lesions would appear as bright red spots, which would deepen in color for a day or two, then slowly fade away.

On examination, hyperemic areas were found in the form of ovals, exact squares, and peculiar shaped patches, from one-half to 2 inches in diameter. The most recent were of three days' duration, and had already begun to fade slightly. The others were in varying degrees of involution. Some recent figures more or less completely covered areas of pigmentation left from the other lesions.

The child had been in constant care of a trained nurse, but for two weeks the regular nurse had been away and the child had been in the hands of a substitute, who some years before had had charge of some of the other children in the family. The first area appeared two days after the substitute took charge, and the last six hours after she left. The nature of the cause was explained to the mother, and no more lesions appeared.

Case 18.—A boy of 18 came from one of the neighboring towns of Illinois to Dr. Hyde's clinic, showing on the left arm sharply outlined, irregularly shaped areas of erythema and superficial dermatitis. The picture was a characteristic one, including evidence of marks left by stray drops of the liquid in its passage over the skin. Dr. Hyde accused the

Digitized by Google

boy before the clinic of inflicting these lesions upon himself, and so surprised the latter that he confessed. He had produced them with phenol, at first for reasons not very clearly known to himself, but on finding himself an object of interest, and after having been exhibited before one or two medical societies, and learning that he was of sufficient interest to be sent to Chicago, he not only persisted in his efforts, but intensified them, and admitted frankly that he did this for the purpose of getting to Chicago, a place he had heard much about but had never seen. After his confession, he was very much ashamed of himself, and stopped the practice.

Case 19.—A girl, 16 years of age, full blooded and unusually strong and well, was struck across the middle of the little finger with a knife with which her sister was paring potatoes. The wound became the seat of an acute and severe inflammatory process. At the end of the fourth day the last phalanx had the appearance of white gangrene, and at the end of the sixth day appeared to be completely dead, as it was black and hard as old leather. The phalanx was amputated. The wound did not heal promptly, but showed suppuration, and the gangrenous process continued up the finger. For a day or two she developed a temperature of 102.5, though subsequent to this time it was never higher than 99.5. Under a hot bichlorid dressing, the wound healed, but remained very sensitive. A few days later, there was an area the size of a silver quarter on the finger, having the appearance of a blister or burn. Later there were areas varying in size from that of a dime to that of a dollar on the back of the hand and arm. The skin over these areas became dry, wrinkled, and grayish in color. Under simple ointments, this covering would come off, leaving a deep-red surface, which was sometimes dry, but at other times hemorrhagic. The patient stated that the appearance of the lesions was always preceded by a terrible burning in the areas.

In the course of nine weeks, the arm up to the shoulder was involved with these irregular lesions, some of the older ones healing as new ones appeared. They always appeared rapidly, in the course of a few hours. Several times all the lesions disappeared, but new ones promptly occurred.

A large variety of local applications, as well as systemic treatment and antistreptococcic serum, had been employed without success. Under fixed dressings the lesions healed, and, though the girl did not confess, no more lesions appeared after she was threatened with exposure. It was discovered that the first injury was treated by the girl with a carbolized salve, which evidently was strong enough to produce in her case a severe form of gangrene, necessitating amputation. In the production of the subsequent lesions she

Digitized by Google

probably knew enough either to reduce the strength with some simple fat, or to make the applications of brief duration.

CASE 20.—A girl, aged 18, apparently in good general health, reticent, at times almost sullen, in association with her companions, was a probationer in a Sisters' hospital. While assisting in dressing a patient with a number of ulcers on the skin, she pricked her finger, and it became infected. The lesion was later incised and curetted, and probably healed. Six months later, the tip of the finger became inflamed, and in two or three days turned black. With hot fomentations, the lesion cleared up. During the next six months, the occurrence was repeated several times, until the first phalanx appeared to be entirely gangrenous and was amputated. Two months later, the second phalanx of the same finger became involved in the same manner and was amputated. Following this, she remained well for three months, when the remaining phalanx of the finger became gangrenous, and was amputated by the same physician. Three weeks later, gangrene began to spread over the back and sides of the hand. On account of the rapidity of the process, the surgeon contemplated removing the hand at the wrist, an operation which the patient begged him to perform to save her life. Before the operation was performed, however, a consultation was held. On examination, the gangrene was found to be superficial, and was bounded by a narrow red line. The advancing border showed a finely jagged or serrated edge, in which the marks of individual punctures could be detected. There was slight anesthesia of the fauces and conjunctiva, and the general condition of the girl suggested hysteria.

The patient denied having made any application herself, but under fixed dressings made a complete recovery, and later confessed to the Mother Superior that she had produced the trouble herself with a needle and pure phenol.

CASE 21.—A counterpart of this last case occurred in the same hospital three years later, under similar circumstances. In this case the areas of superficial gangrene appeared on the forearm. Remembering the previous experience, the Mother Superior suspected the nature of the trouble. Application of fixed dressings was followed by complete recovery, and later by a confession from the girl that the lesions had been produced by a needle and phenol.

No motive was given for these acts except the desire for attention and sympathy.

CASE 22.—This was a young woman, Miss B., who had multiple areas of superficial gangrene on the breasts, arm, and back of the left hand. She was 17 years of age, and lived at home. She appeared to be well nourished, but complained of indigestion and insomnia, headaches, and general

Digitized by Google

weakness, which had been present ever since she had been vaccinated, four and one-half years previous to that time. The day following vaccination, she became suddenly blind, but recovered her sight after a few days. A hard lump developed at the vaccination point and remained for several years. During this time, the patient complained of more or less pain in the hand, arm and side. Six months before the present examination, an accidental cut occurred on the hand. An application which had been purchased at the drugstore was made, but the wound refused to heal, grew larger, and became black. Later it was completely excised by her surgeon. Just before healing was completed, a new spot appeared near the first one. From time to time others appeared on the arm and breast. On two other occasions, a surgeon completely excised the gangrenous areas, but new ones continued to appear.

On examination, irregular, sharply outlined areas of very superficial gangrene, bounded by narrow, jagged red lines, were seen on the left arm and breast. There were also several thickened, irregular, and disfiguring scars at the sites of the previous operations; also some superficial scars which had marked the sites of the areas which had healed spontaneously.

In the opinion of Dr. Montgomery, who examined the case, the lesions were produced with the aid of a needle. There was no evidence of the usual accidental drop running over the skin.

The patient did not make a full confession, but admitted that she might have done some things in her sleep which she did not know about, and also that she had some "patent carbolic salve" in her room, which she used occasionally for cuts. After the consultation, the patient made a complete recovery.

Case 23.—Miss A. Y., a girl aged 17, in good general health, was the eldest of nine children, and, on account of the death of her mother two years previously, had had charge of the entire household.

Six weeks previous to the examination, her finger was scratched on a barbed wire. The skin turned black three days later, and blisters appeared on the hand and arm. These began as pimples, which became dark in three days, and gradually became larger.

On examination, there were seen on the outer surface of the left forearm and on the wrists and hands eight or ten irregularly shaped patches, from 1½ to 2 inches in diameter. There were two acutely inflamed areas, with an irregular, finely jagged or serrated outline, thickly covered with pinhead or slightly larger vesicles. These were of but two or three days' duration. Other similar areas were covered with

Digitized by Google

black, gangrenous crusts, surrounded by a narrow red line. There were two rather thick, irregular, pigmented scars. The tissue destruction was deeper than that seen in most of these cases.

On confrontation, the patient admitted that she had produced the lesions with a pin dipped in lye. A letter received some months later from her family physician stated that the patient returned home and made a complete recovery.

CASE 24.—Miss M. A., aged 18, in good general health. While there was no history of hysteria, there was some anesthesia of the fauces. The cutaneous lesions had been present for three weeks, and presented clear-cut, circular, erythematous areas, varying in size from one-half to 2 inches in diameter, which had appeared at intervals of a day or two upon the face. After from one to three days of vivid redness, the lesions gradually faded.

On examination, the circles were found to be distributed generally over the face, but chiefly on the forehead and on the right cheek. The lesions were very superficial, with no vesiculation or crusting. Some bright-red semicircles rested within older and faded areas. Several circles overlapped the lesions, which had evidently been produced by laying on the skin circular pieces of cloth soaked in a dilute solution of phenol. In two places a drop of fluid had run down from the lower margin of a circle, producing the characteristic telltale line.

This patient was informed as to what the trouble was, but indignantly denied it. Upon returning home, however, she had no recurrence of the trouble, and in a few weeks admitted to her father that she had discovered that the soap she had been using contained phenol.

CASE 25.—Mrs. W. B., a married woman, aged 23, in good general health, stated that three years previously she had fallen through a sidewalk, wrenching and spraining her foot. The doctor had used phenol, which produced a running sore, so that she was compelled to go on crutches for a year. Seven times during the last two years, always following some slight bruise or accident, some portion of the skin on her foot or ankle had become inflamed, with the production of small gangrenous-looking areas. In the interval between the attacks, the skin was sound, but was occasionally the seat of an aching or burning sensation.

Three days prior to the examination, she had bruised her ankle on a bicycle, and there had followed the lesion for which she came for treatment. The inner surface of the right ankle and the foot beneath it were covered by sharply defined, irregular areas of very superficial necrosis. The destruction of tissue was limited chiefly, but not entirely, to the epidermis. The areas were bounded by a narrow red line,

Digitized by Google

and showed peculiar serrated or jagged edges. The last area was larger than the others, and showed no serrated edge, but instead an even, sharply defined outline. From the lower border of this area were seen several streaks of lighter discoloration, due evidently to the dropping of the fluid from the wet cloth when it was applied to the foot. The similarly irregular area with the jagged outline about the ankle was evidently made with a needle or a pin dipped in phenol or similar agent.

The patient was of nervous temperament, but showed no evidence of hysteria. Upon being told that the cause of her trouble was known and would be explained to her at her next interview, she disappeared and did not return.

Case 26.—Mrs. J. M. W., a married woman, aged 33, and apparently in good general health, had been seen by many physicians, a number of whom were impressed by the fortitude with which she bore pain. She was equally impressed by the fact that none of her physicians had discovered what the trouble was.

Two and a half years prior to this examination, which was made by Dr. Montgomery, she had all the symptoms of pregnancy up to the seventh month, when suddenly the whole thing disappeared.

The cutaneous disorder was of two years' duration, and had begun in the breast. A month later lesions appeared on the nose. The trunk soon became involved, and finally the limbs. The lesions were accompanied by burning and itching sensations. On the body they began as a blister on the sound skin, or on a slightly reddened area. Frequently, her face had been nearly well. The lesions always appeared suddenly.

On examination, there was found a superficial dermatitis of the nose and cheeks, in irregular, sharply outlined areas, covered with a thin edge of scales or crusts. On the upper surface of the breasts and above them were numerous irregular, sharply defined, erythematous spots, one-quarter to three-quarters inch in diameter. Some of these spots showed slight vesiculation or a superficial necrosis. Areas were seen in all stages of healing and of resulting pigmentation. They were most numerous over the breasts, the abdomen and the left arm. On the breasts were two small areas of erythema, from the lower border of which extended the characteristic streaks caused by the dropping of the fluid over the skin. There were several lesions about the umbilicus, others in the groin and on the inner surface of the thigh.

Her attending physician was informed of the nature of the trouble, and after using fixed dressings for a time he discussed the matter with her. The patient agreed that she

Digitized by Google

would do as he directed, but she promptly put herself in the hands of another physician.

Nearly a year after this examination, I saw the patient in a clinic given before a medical society, when the diagnosis of factitious dermatitis was independently made. The difficulty in making the diagnosis at this time lay in the fact that the patient had become more skilful and was now producing perfectly circular, regular areas, and was not spilling any of the fluid. At least six or eight members of the society discussed the hysterical manifestations seen by them in this case, and all were agreed as to the factitious origin of the lesions.

CASE 27.—Miss E. P., aged 24, a well-to-do patient of nervous temperament, gave a history of having had an extensive burn on the arm from phenol two years previously. About three months ago, lesions began to appear. At first, there would be a whitish area, which would last for a few hours, and be followed by water-blisters. The blisters always appeared during the night and were evident the following morning.

On examination, irregular roundish areas, which were now healing, were seen on the wrist, extending from which were two lines, showing plainly where the fluid had run down from the main lesion.

Some months later, a report was received from the attending physician stating that the factitious element in this case had been proved.

CASE 28.—Mrs. A. B. H., about 40 years of age. Duration of disorder, seven months. The patient was nervous, and had many of the stigmata of hysteria. She frequently suffered with anuria.

The lesions had been occurring at irregular intervals, each appearing suddenly and healing within a reasonable time.

At the time of examination, the lesions were limited to one leg, and consisted of open ulcers, irregular in outline, crusted lesions, scars and stains.

A subsequent report from the family physician stated that the factitious element in this case had also been demonstrated.

CASE 29.—The record of this patient, Miss M. B., aged 27, includes four or five visits to the Presbyterian Hospital, one or more to the County Hospital, and the attendance of several physicians.

About May, 1910, the patient received an injection of tuberculin in the left arm above the elbow. Three days later, the arm swelled, and the patient was sent to the dispensary for treatment. A salve containing phenol was applied, and the patient returned home. Shortly after this, lesions began

Digitized by Google

to occur, extended down on the arm, later appeared on the left leg, and subsequently, as time went by, on the entire trunk, right arm, and all parts of the body within reach of the hands.

I saw the patient shortly after the onset of the trouble. It was evident that the original phenol salve had given her the idea and the material with which to carry it out. She was hysterical, almost always moderately deaf, sometimes entirely so, and was capable of marked imitation. During the years she had been under observation, the type of the lesions had changed. It is likely, therefore, that the materials used had been modified.

Monday, Nov. 4, 1910, the patient was seen in the clinic at which time the lesions were present on the left arm, the trunk, the foot and the lower limbs, the right arm being free. Up to that time she was supposed to be deaf. In the clinic the case was demonstrated, and attention was called to the absence of lesions on the right arm. November 7, three days later, the patient again attended the clinic, and entered the hospital on the same day. At this time she had a number of lesions on the right arm, which apparently showed evidence of suggestion. The house physician, Dr. Tope, made these notes on that day:

"Lesions situated on both arms, from shoulder to wrist. They consist of open ulcers, gangrenous areas, some covered with dirty-gray sloughs, other ulcers that are healing, and many scars, some of which are keloidal. The patient professes ignorance as to the cause or duration of the lesions; professes to be deaf, but can hear much better than she admits. Speaking in ordinary tones to her, she not only hears but understands. If asked if she understands, she says 'No.'"

Nov. 1, 1912, when the patient was again in the hospital, Dr. Pincoffs, the house physician, wrote a description of the cutaneous lesions much as given above.

The record further states that the patient mentally was at first in an antagonistic attitude, but during her stay at the hospital she became more cheerful and went about the ward conversing with other patients. Deafness and blindness were complained of, but these later disappeared. The question of a certain amount of true deafness was not definitely settled, but the amount varied from day to day.

During one of her temporary visits at the County Hospital, she saw numbers of syphilitic lesions in inmates of the same ward. After leaving the hospital, many of her lesions assumed the peculiar circinate outlines which she had witnessed at the hospital.

She was examined as to her mental state by Dr. Bassoe, who discovered marked evidences of hysteria. There were no other neurologic changes.

Digitized by Google

The patient had been under the care of Dr. Mackey during the greater part of this time, and it was the observation of all that during her residence in a hospital the lesions always cleared up. Immediately on her release they would recur. As they were always produced at home, and as we had had no assistance while she was there, we had no means of ascertaining the agent employed, except the one originally suggested, phenol.

CASE 30.—Miss M. M., aged 24, seen Dec. 11, 1909; duration of disease, twelve years.

Nothing was known as to the antecedents of this patient. About the time of the commencement of menstruation, in the twelfth year, she began to have bullae at monthly intervals. These varied in size, and were situated chiefly over the breasts and abdomen.

April 14, 1909, her right arm was injured by a nail. May 1, Dr. T. was called in and has taken care of that lesion since.

On examination, the chest, breasts and abdomen were found to be the sites of large pigmented areas, squarish in outline. The right hand and forearm had linear scars, some of which were keloidal. In addition, there were moderately deep, irregular ulcers and other lesions. All of these had occurred at irregular intervals, and, the patient declared, had been preceded by bullae. Dr. McEwen, who saw the patient, noted that the lesions on the front of the trunk were arranged in the form of a cross, and suggested a possible religious element in the case.

The diagnosis of a factitious eruption was forwarded to the attending physician, with suggestions as to determining the facts. A letter received in May, 1915, from this physician stated that after the visit in Chicago the lesions occurred less often, and finally recurrences ceased. The case, therefore, remains in the group of those not proved.

CASE 31.—The following case, though not identical with the major number of those discussed in this article, is of interest:

The patient, Miss E. G., aged 33, was seen in January, 1911. At that time she presented a large number of keloids, some linear and some of other shapes, and numerous other scars over the forehead, nose, cheeks and chin. There was also considerable hyperpigmentation. She gave a history of having been treated with radiotherapy and other measures for the relief of an acne. At a later date, the electric needle had been used in an effort to remove hypertrophic scars. On examination, it was determined that the patient was melancholic to a high degree.

She remained under treatment for six months and made much improvement during this time, locally and generally. All of the time she had been under the constant care of a

Digitized by Google

companion. At this date it was agreed that she was to go home, and she bade all of her friends in Chicago goodbye. Three months later, however, it was learned that she had not arrived home, and after some search she was located in an apartment-house in the city, where she was living alone. During this time she had mutilated her face with the electric needle and by other measures. Her room was found in great disorder, and it was further found that she had had very little to eat and had had no laundry done for weeks. In spite of all that could be done to persuade the patient to go home, the last heard from her was that she was still living alone in this apartment, and, so far as could be determined, was still mutilating the skin of her face.

In this case, apparently, the mutilation was the result of an insane desire to relieve her disfigurement, and the measures employed tended to increase the trouble, rather than the reverse.

Case 32.—This patient, a physician, aged about 47, came to the hospital with an extensive and unusual dermatitis. There was a marked mental disturbance in the case, and the history the patient gave of the beginning of the dermatitis was that it had followed exposure to plants in the country. He stated that, owing to insomnia, he would run for miles at night with no clothing on, and along part of the course there were weeds and shrubs which struck the skin. The patient was also addicted to morphin.

After being in the hospital a short time, the dermatitis cleared up to a great extent, but suddenly recurred one morning. On careful examination of the genital region, some particles of material were discovered, and on inquiry the patient admitted that he had rubbed short-cut tobacco into the entire region. He had no reason to offer for his action.

At a somewhat later date, this patient was sent to a sanatorium to be treated for insanity.

Case 33.—The two histories outlined below are not complete owing to the fact that the original record was misplaced at the clinic. The first patient was referred to the dermatologic clinic from the surgical department. He was a young man, aged about 24, and came presenting a gangrenous lesion on the left forefinger, involving three fourths of its length. On close examination it was seen that the blackened area was superficial, and was perfectly well defined on the proximal end. In the surgical department a thrombus, cutting off the blood supply of the finger, was suggested.

In the clinic, the patient was demonstrated as one exhibiting a factitious lesion, probably induced by phenol. As rarely happens, the patient acknowledged before the students that he had produced the lesion by putting his finger

Digitized by Google

into a bottle containing phenol, after having had some difficulty with a young woman, in the hope of obtaining her sympathy.

CASE 34.—This was the case of a boy, aged 14 years, who had lesions on the legs and arms which presented the appearance of superficial infections on a scratched or rubbed background. New ones had continued to appear as the older ones were nearly healed. After some observation, the suggestion was made to the parents that the lesions were probably factitious, a matter they later proved. It was found by them that the boy had produced the lesions with sandpaper, in order to avoid going to school.

SUMMARY

Of the thirty-four patients described above, thirty were females. Fifty per cent. were under 22 years of age. Trauma preceded the lesions in twelve cases. Of these, two had been burned with acid, two had had antiseptic applications made by a druggist, and two had been treated with phenolized salve. Of the thirty-four, thirteen confessed and made an immediate recovery; one case was proved under the care of a nurse, and three under fixed dressings; one patient completely recovered after being confronted. Of the total number, twenty-five made complete recovery, three disappeared, one was a degenerate, two gradually recovered after a long time had elapsed, and in two cases the lesions continued. One patient never had lesions while under observation in the hospital, but continued to have them outside.

Of the thirty-four, it was proved that fourteen used phenol, four probably used phenol, one used compound solution of cresol, one phenol and other substances, one croton oil, one lye, one sandpaper, one tobacco, one the electric needle and unknown but liquid applications, six entirely unknown substances, and three unknown liquids. It is interesting to note that several patients recovered after being confronted with the materials they had used, even though denying their use. Change of scene in one case induced recovery, and in another the departure of the person whose

Digitized by Google

presence had irritated the patient. In only four of the group was the diagnosis not positively proved, either by confession or by complete recovery of the case under fixed dressings or constant supervision. In the four, however, the evidence was so strong that there was practically no doubt as to the diagnosis.

CONCLUSIONS

First, it seems probable that the major portion of cases described as pemphigus gangrenosus are in reality examples of factitious dermatitis. That the major number of cases recorded under the title "zoster gangrenosus atypicus" (Kaposi) are of the same type, and also those more recently described under the title of "dermatitis symmetrica dysmenorrhoica," seems probable.

Second, while the disorder is comparatively rare, it probably would appear more common if recognized more generally. As stated in the beginning, the family physician will generally, on account of personal acquaintance with the patient, refuse to admit even to himself the possibility that this particular patient would produce such lesions.

On the recognition of the disorder, the admission of the patient as to its cause, and the cessation of the practice, immediate recovery generally takes place; if not, careful attention to the measures detailed above should be employed, when the desired result is accomplished. Treatment is a simple matter, and requires only the application of the various remedies indicated by the stage of dermatitis present. The only difficulty in any case is to prove the diagnosis.

25 East Washington Street.

ABSTRACT OF DISCUSSION

Dr. Howard Morrow, San Francisco: I have had five or six of these cases in the past ten years. They have all been in women. The majority of the patients have been over 30 years of age. I can recall two who were to me of great interest: One was that of a telephone operator.

Digitized by Google

She disliked her work and stayed away by producing a phenol burn on the arm. Her family had sympathy for her and she was kept at home. She applied the phenol as a compress and produced deep sloughs. Another girl was seen in consultation with Dr. Buckley some time back. She applied phenol to different areas on her leg. She told her folks she was run down and would have to take a trip to get rid of them. After she returned from the trip, these lesions disappeared. After a time they started again. I suggested zinc oxid paste, as the patient cannot remove that, and reapply it. Each day after the application of the paste, new lesions would appear in the neighborhood. After this was done four or five times, Dr. Buckley became annoyed at the patient and he said to her, "You do this yourself and it must be discontinued, or I will report it to your family." She at first denied this but afterward admitted it. No more lesions occurred.

Dr. Lasher Hart, Los Angeles: Dr. George Henry Fox had a case in his clinic. Dr. Fox took the patient into a room and said, "What have you been doing here?" She admitted that the lesions which she had on her forearms had been caused by rubbing salt into them, and that she was seeking sympathy from her employer. Dr. Fox confronted them at once with the idea that he knew that the diseased areas were selfinflicted, and I have always followed out that idea in my own practice since then.

Dr. George M. MacKee, New York: As bearing on possible etiologic factors, we had in Dr. Fordyce's clinic a few months ago a case of neurosyphilis with lesions of factitious dermatitis on the chest, arms and shoulders. The interesting question was whether or not the neurosyphilis had so altered the nervous system as to produce a malingerer. As is well known, cases of malingering are at times exceedingly difficult to diagnose, and are not infrequently confused with other diseases. I recall a case in which the first ulcer developed on the back of the hand; later numerous ulcers occurred on the forearm. The case was investigated for the possibility of sporotrichosis, syphilis, tuberculosis, etc., but later the patient was proved to be a malingerer.

Dr. A. J. Markley, Denver: During the last six or seven years I have had the misfortune to observe a number of cases of this kind and believe that, as Dr. Ormsby has done, it is necessary carefully to distinguish between the two types of individuals in which this occurs; that is, the malingerer and the neurotic. In the malingerer, if the patients definitely know that you are familiar with the manner in which the lesions are produced, they may be frightened off. On the other hand, hysterical and neurotic individuals are less easily dealt with, and when accused of inducing these lesions themselves, are often led by their

Digitized by Google

neurotic tendencies into practices of more serious kind. Such cases belong definitely in the hands of the neurologist. Of this type, a girl in an orphanage in Denver had become a serious charge to the good Sisters who took care of her. She had disfigured herself with some form of caustic, sparing no part of her body which was accessible to her right hand. The only part which she had been unable to reach was the scapular region of the right shoulder. When confronted with the charge of self-infliction of these lesions, she ceased to produce them, but other stigmata of hysteria occurred, and only when she had been placed under proper neurologic care was any permanent benefit obtained.

Dr. Richard L. Sutton, Kansas City, Mo.: I envy Dr. Ormsby the long list of cases which he has had opportunity to observe. The character of the lesions, the region involved, and the fact that the affected areas were usually readily accessible to the right or left hand are also suggestive. I recall a recent case in Kansas City in which a patient, a woman student, had burned herself with nitric acid. The lesions healed, but new ones speedily appeared. The superintendent of the school was a very religious woman, almost excessively so, and she would not believe it possible that a girl placed under her care would do such a thing. It was only when the matter was thoroughly sifted and the diagnosis verified beyond the shadow of a doubt that the girl was sent home as utterly unfit for the training she had taken up. So one must be as careful as possible in approaching the patient as well as her family, if the treatment is to be ultimately successful.

Dr. Oliver S. Ormsby, Chicago: In one of the illustrated cases which I intended to read, the question of autosuggestion arose. It has been thought that sometimes by autosuggestion lesions may be produced spontaneously; that is, a patient is able to bring out a lesion on the body by fixing the mind on it. These, however, are often factitious, and may be illustrated as follows: In a clinic on a certain Tuesday there was a patient who was supposed to be deaf. The lesions were all placed in regions readily accessible to the right hand, on the left side, and I called this fact to the attention of the assistants. On Friday, when the patient returned, she had lesions on the right side, including the right arm and forearm. At a later date, when in the County Hospital, she observed cases of syphilis in women having that disorder, and some months later she began to have lesions which were circinate in outline, and these lesions were supposed by several to be of syphilitic origin. The question of suggestion is sometimes important.

Digitized by Google

ACANTHOSIS NIGRICANS AS AN INDICATION OF INTERNAL MALIGNANCY

A. J. MARKLEY, M.D.
DENVER

There is probably no clinical picture of cutaneous disease more striking and impressive than that presented by the typical case of acanthosis nigricans. Because of its rarity, however, and the dominant character of its skin symptoms, interest in and knowledge of this disease are practically limited to dermatologists. Yet it possesses certain features which render some acquaintance with it of importance to the general profession, and it is toward these particular features, rather than toward detailed consideration, that attention is here directed.

The disease is characterized by the definitely regional and symmetrical development of varying degrees of pigmentation and of multiple hard and soft papillary growths, the sites of predilection for these changes being the sides and back of the neck, the face, the axillae, the genitocrural region, the backs of the hands, the palms, the mucous membranes of the mouth and the vulva, and at times the orifices of the ears, nose and eyes.

More important, however, than the interest attached to it as a rare and striking disease of the skin, is its very frequent association with some form of internal malignancy. So well established is this association that acanthosis nigricans occurring in an adult is regarded by dermatologists as definitely indicating the presence of an internal malignant process even though it cannot be clinically demonstrated.

Digitized by Google

Pollitzer, who, coincidently with Janovsky, originally described it, gave a most comprehensive review of the subject before this section six years ago,[1] explaining in detail its significance and the importance of its early recognition. The desirability, however, of keeping before the profession facts of any kind, even those rarely elicited, which will assist in the earlier recognition of malignant disease, seems sufficient justification for again directing attention to the characteristic features of acanthosis nigricans, emphasizing its relation to internal malignancy and recording a typical case.

CLINICAL FEATURES

Two distinct forms of the disease are recognized: the adult or malignant, characterized by some serious internal disorder, particularly malignancy, short duration, intensity, and wide spread of the skin symptoms, which are at times marked by exacerbation and remissions, even to complete disappearance; and the juvenile or benign, characterized by little or no disturbance of the general health, less marked development and spread of the skin symptoms, which after a short time became stationary and persistent.

The mode of onset varies, in some cases intense itching and pigmentation about the neck and face being the first symptom; more commonly the first evidence has been an eruption of common warts over the backs of the hands and the forearms. Further development is usually rapid, involving symmetrically the regions above mentioned. The papillary growths vary within the widest limits, from small hard warts, the size of a split pea, on the back of the hands, to large soft condylomatous masses in the axillae or groins and long filiform projections on the tongue. The palms and soles may be involved in a diffuse horny thickening, causing much limitation of movement and

1. Pollitzer, S.: Acanthosis Nigricans a Symptom of a Disorder of the Abdominal Sympathetic, THE JOURNAL A. M. A., Oct. 23, 1909, p. 1369.

Digitized by Google

giving the hands a claw-like appearance; the nails show nutritional disturbances and the hair may be similarly affected.

Quite as important as the papillary changes is the pigmentation, which is a most conspicuous feature of the disease, varying from a dirty grayish discoloration through shades of brown to black. It may precede the appearance of papillary overgrowth and affect areas in which the skin is only thickened and presents the appearance known as lichenification. The distribution of the two processes is, however, ultimately the same, except that the mucous membranes are never involved in the hyperpigmentation.

The development of warty and condylomatous masses on the lips, within the cavity of the mouth and along the ciliary borders causes the patient great discomfort and distress and constitutes a most striking feature of the disease; but with the exception of itching, there are no subjective sensations complained of.

The time occupied in the development of such symptoms as above outlined is from a few months to two years, the course usually being terminated by the associated malignant process. The juvenile form, however, as previously stated, may persist indefinitely without untoward results.

In 1909 Pollitzer was able to collect from the literature 52 cases and since that time, about 20 additional cases have been reported, but this certainly does not represent the entire incidence of the disease. Of Pollitzer's list of 52 cases, 35 were of the adult type, the patients being over 20 years of age; in 28 cases, or 80 per cent., the presence of malignant disease could be definitely shown or was highly probable; and the proportion of malignant cases among those reported since that time would tend to make the percentage higher rather than lower. The organs affected have been in their order of frequency, the alimentary

Digitized by Google

tract, the uterus, the breasts and in one instance, recently reported, the lung.[2]

A majority of the cases have occurred in women at that period of life in which malignancy is most prone to develop; that is, between 35 and 50. A typical malignant case, however, has been observed, associated with a malignant uterine neoplasm (deciduoma malignum), in a girl of 19.[3] The appearance of the characteristic features of the disease may precede by some months, or even longer, the development of symptoms referable to the associated internal disorder. Klotz' case[4] is an example in which a sarcoma in the pelvis was not discovered for almost two years after onset of the skin disorder. To this list of the adult malignant form, I wish to add the following.

REPORT OF CASE

Patient.—Mrs. T., aged 54, referred by Dr. J. N. Hall, Jan. 21, 1915. Previous history unimportant, except for indigestion during many years; two years ago sudden pain in stomach and sharp hemorrhage necessitated operation and excision of an ulcer, since that time no digestive disturbance aside from constipation. Has three children, never any pelvic trouble.

Present Illness.—This began eight months ago; first noticed an intense itching over abdomen, next sudden appearance of numerous warts over backs of hands and forearms, soon followed by discoloration about neck and face. Four months ago growths began to appear on tongue and palate; since that time progress has been very rapid.

Examination.—General condition good. Heart, lungs and kidneys apparently normal. Blood pressure 120. The backs of the hands and the extensor surfaces of the arms (Fig. 1) are occupied by innumerable hard papillary excrescences of all sizes up to that of a pea; about the wrists the skin is thickened and fissured and the affected parts are here a dark grayish color. The palms are greatly thickened and almost horny, giving to them a translucent yellowish hue. The axillae are deeply pigmented and there are many soft filiform warts. The sides and back of the neck and the shoulders show pigment changes, ranging from gray to a sooty black, and there

2. Petrini de Galatz: Ann. de dermat. et de syph., 1914, No. 6, p. 331.
3. Spietschka: Arch. f. Dermat. u. Syph., 1898, xliv, 247.
4. Klotz: Jour. Cutan. Dis., 1913, xxxi, 306.

Digitized by Google

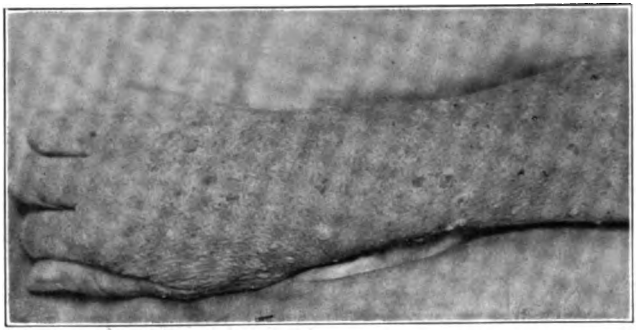

Fig. 1.—Papillary excrescences on backs of hands and extensor surfaces of arms in a case of acanthosis nigricans.

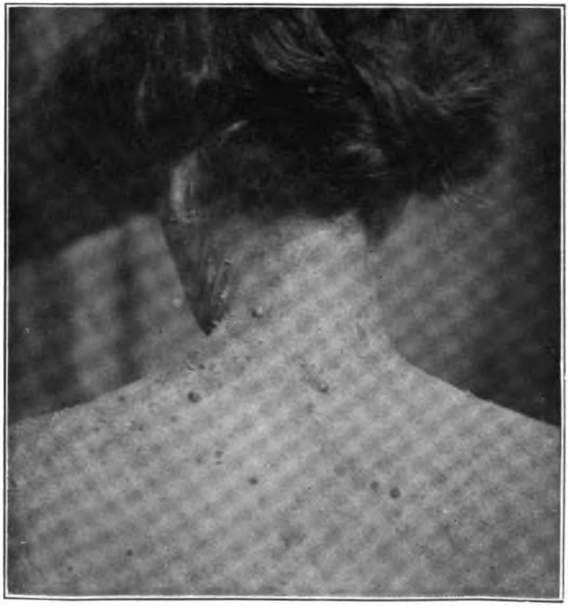

Fig. 2.—Pigment changes and papillary growths over the back of the neck and shoulders.

Digitized by Google

Fig. 3.—Extensive changes in mucous membrane of mouth.

Digitized by Google

are numerous papillary growths over the whole of this region (Fig. 2). The face shows pigmentary changes and few warty growths on the forehead; there is also a growth of coarse white hair. The ciliary borders are granular and there are many large soft papillomas. The auditory canals and the nasal orifices also are surrounded by a rim of small filiform growths. The mucous membrane of the mouth, however, is the site of the most extensive changes. The vermilion borders of the lips are wholly occupied by small and large papillary excrescences; the dorsal surface of the tongue is covered by long filiform projections; the hard palate is completely filled in by a dense condylomatous mass until it is level with the superior teeth, the outer surfaces of the gums above and below are involved and a condylomatous growth protrudes from each interdental space. The inner surfaces of the lips and cheeks are but slightly affected and the fauces and pharynx are entirely spared.

The genitocrural region is not involved in the papillary overgrowth, but is deeply pigmented. The scalp is dry and scaly and the hair falling rapidly.

With such a clinical picture, a diagnosis of acanthosis nigricans was made, and in view of the history of ulcer of the stomach, a cancer of that region was predicted. A most careful examination by Dr. Hall, however, failed to reveal evidence of any intra-abdominal growth; nevertheless we felt justified in having the abdomen opened, and this was done by Dr. Freeman on January 27. Much to our chagrin, after a most careful search, absolutely nothing was found in the abdomen, except a single gallstone of very unusual shape. For a few weeks following the operation, the patient seemed much better, and hope was entertained that removal of the gallstone would be of benefit, but soon the lymphatic glands below the clavicle on each side began to enlarge, indicating, in our belief, the existence of a malignant process somewhere within the cavity of the chest. A careful roentgenographic examination failed to reveal anything in the chest, but the further progress of the case seems, notwithstanding, to point in that direction. Since glandular involvement has increased, the patient has become more cachectic, and no evidence has developed of difficulty with the stomach, which would certainly have occurred had that organ been the seat of a progressive malignant disease.

THEORIES AS TO ETIOLOGY

A satisfactory explanation of the pathogenesis of acanthosis nigricans cannot be given, although it is generally assumed that it is in some manner dependent on disturbance of the abdominal sympathetic, the

Digitized by Google

"mechaniconervous theory" of Darier. This theory assumes the production in the abdominal cavity of pressure from primary or metastatic malignant neoplasms, and a consequent functional disturbance of the nerve structures in that region. It is difficult to reconcile this theory with the juvenile and other benign cases in which no neoplasm is present; moreover, the great frequency of intra-abdominal neoplasms, accompanied by localized pressure, should more often lead to the development of acanthosis nigricans if such pressure were really the cause of that disease. It is also evident that acanthosis nigricans may be associated with malignant growths elsewhere than in the abdominal cavity, as shown by the case of pulmonary cancer previously referred to and my own case.

Porias, in a recent article,[5] develops the theory that the skin dystrophy is brought about by a derangement of certain internal secretions on the action of which the normal condition of the skin is dependent, the active factor in this derangement being some debilitating condition, the most common of which is cancer. Such a theory is not inconsistent with rapidly accumulating evidence of the relation of disordered internal secretions to the production of various dystrophies, and particularly to pigmentary changes; and would more nearly explain the juvenile and other benign cases. In this connection may be cited the case reported by Juan de Azua[6] of an adult in whom no evidence of malignancy could be discovered but who was much benefited by administration of salvarsan, suggesting that syphilis may therefore be the disturbing factor in some cases.

Whatever may be the direct cause of the disease, however, there is no doubt of the clinical fact that in a large majority of acquired cases of acanthosis nigricans in adults, there is present, earlier or later,

5. Porias: Wien. klin. Rundschau, 1913, No. 38, p. 671.
6. Azua, Juan de: Abstr., Jour. Cutan. Dis., 1913, xxxi, 966.

Digitized by Google

some form of internal malignancy. Most commonly, the growth is within the abdominal cavity and may be amenable to modern methods of treatment, the possibilities of which have been greatly increased by recent advances in Roentgen-ray technic for both diagnostic and therapeutic purposes.

CONCLUSIONS

1. The development of acanthosis nigricans in the adult is an indication of some serious internal disorder, the most frequent of which is cancer.

2. The frequency of this association justifies the assumption of a diagnostic relation between the two conditions.

3. Notwithstanding its rarity, acanthosis nigricans should be promptly recognized, and an effort made to locate and if possible, to remove an associated malignant growth, even though no other evidence of its presence exists.

Metropolitan Building.

ABSTRACT OF DISCUSSION

Dr. Oliver S. Ormsby, Chicago: In the report of cases which Dr. Markley spoke of, prepared by Dr. Pollitzer was one of the juvenile type in which I was interested. I saw that patient eight or nine years ago, and this case was classical of the juvenile type. The patient consumed an amount of spirits which was entirely out of proportion to anything I had ever seen in a young person. After a single examination he disappeared. Last year I sent for him to appear at the annual meeting of the American Dermatological Association, and although he preferred not to come he reported himself as well. It is an interesting fact that the type occurring in children is benign, while the adult form is malignant.

Digitized by Google

XERODERMA PIGMENTOSUM

ITS TREATMENT WITH AUTOGENOUS SERUM

J. B. KESSLER, M.D.
IOWA CITY, IOWA

In 1914, two children from Clarinda, Iowa, were sent to the asylum for the blind at Vinton, Iowa. Some time later they were referred to the University Hospital to be treated for weeping eczema.

Family History.—Their father, a carpet weaver, aged 37, was born in Iowa. His health has been good, no history being given of disease or injury before the children were born. Their mother, aged 34, was born in Missouri, and was always healthy. The father and mother are not related, and neither was married before. The mother has had no miscarriages and there is no history of carcinoma, mental disturbance or tuberculosis in the family.

Verdie F., a white girl 8 years old, did not attend school until last summer, at the asylum for the blind. As a baby she was healthy and stout, being undeformed at birth. There is no history of snuffles or adenoids. The present disease began when she was 2½ years of age. It first appeared on the face and limbs as little red spots.

On examination we find the child to be small for her age, fairly well nourished; hair is light colored, the scalp covered with scales. Her face is thin and pinched, the ears are atrophied and hard, the nose is drawn and pinched, the nostrils are flattened, the lips are thin and hard and cannot be everted without pain. The whole face has a shiny, almost a glazed appearance, with underlying telangiectases. The eyes are red, and show conjunctivitis and marked photophobia.

An irregular coalesced tubercle formation appears over the left eye, having almost the appearance of a tumor. It is elevated ¼-inch and is dark brown. Similar formations, but more wart-like and smaller, varying in size from a large pin head to a penny are on the forehead. They have scaly tops and are rough, and variable in color.

Digitized by Google

Fig. 1.—Appearance of eruption on front of body. Note elevated nodules on forehead of girl.

Digitized by Google

Fig. 2.—Appearance of eruption on back and legs.

Digitized by Google

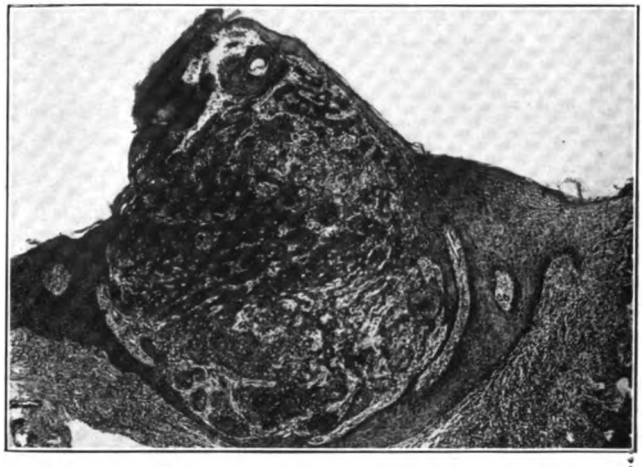

Fig. 3.—Section from nodule incised from eyelid of girl.

Digitized by Google

Digitized by Google

Five of these growths are on the forehead, one on the nostrils and two on the chin. The tumors are all located on the face and head. The other parts involved, show a lentigenous or freckle-like pigmentation, and vascular telangiectases appear from the neck down to the buttocks, caused, probably, from the dress being open in the back. They also appear on the thighs, more profusely on the back than on the front. They are on both front and back of the legs, on the flexors of the feet, and some may be seen even on the toes. The arms show them on both extensor and flexor surfaces. They are on the front and back of the forearms, but on the back only of the hands. The lesions on these surfaces consist of superficial light areas and are scaly with an under pigmentation. They vary in size, and are flat on the surface. On the back of the hands the skin is beginning to take on a furrowed appearance. Conical patches occur which look like those of leukoderma and show no pigmentation. The skin seems to be attached to the underlying structures. The neck is slightly flexed, but rotation and extension are normal. There are no palpable glands. The pulse rate is 84, the temperature at times rises to 99. The lungs and heart are normal. The abdomen shows no pigment. The skin of the neck and face is difficult to pick up; it is hard and stiff and firmly attached. The skin in other regions varies from normal elasticity to almost entire loss of it (Figs. 1 and 2).

The blood count shows whites 11,800, reds 4,980,000; polymorphonuclears 80 per cent., eosinophils 1 per cent., small lymphocytes 17 per cent., large lymphocytes 2 per cent.

The urine is normal. Microscopic examination shows epithelium but no blood cells, an occasional pus cell, no crystals and no bacteria.

Howard F.. white boy, aged 6, began at the age of 2½ to show this disease. The lad is small for his age, and has a shrunken appearance. His legs and arms are small; his face seems to be drawn toward the midline. One is struck immediately by the hanging of the head and the spotted appearance of the face. The chin and the nose are small and angular. The hair is brown, dry and shaggy. The scalp is covered with white scales that are dry and very fine, and closely adherent.

Over the face, neck and ears there are freckle-like spots. The skin has a glossy appearance as if stretched, so that when the boy makes grimaces the skin pulls in fine folds about the neck and mouth. The face has three tints, pink, white and dark brown, which appear as if put on at different times, and cause a mottled appearance. The pigmentation extends entirely over the ears into the external meatus. He has continuous and marked photophobia. His eyes are small

Digitized by Google

and sunken. There are no palpable glands. Freckles and telangiectases appear on the legs, arms, neck, face and ears with marked atrophy of the skin of the ears and face; in appearance he is an exact counterpart of his sister, except that he has no tumors and his back is not freckled.

Orpha F., the oldest of the children, had the same disease, which commenced when she was 1½ years of age, and, at its onset, had the appearance of sunburn. She had atrophic spots, conjunctivitis and photophobia, but no tumors. This child was deformed and an invalid all her life. She died at the age of 13.

One 4-year-old boy at home is healthy. The mother writes us that the children were no more exposed to the sun than her other children and is positive the disease began in the two living children as little red pimples, and in the first one attacked by it as a sunburn. At all events the disease is in locations accessible to the sun's rays.

Gross Pathology (by Dr. Dean).—The tumors removed from the eyelids of the little girl present the following appearance:

The specimen consists of two growths, one removed from the left eyelid and the other from the right. The growth from the left side measured 1.5 by 1.25 by 0.5 cm. It is reddish-gray, is firm and cartilage-like and its outer surface is nodular. The growth removed from the right side is similar in size to the one described, but is thinner, appearing like a piece of skin with a roughened surface.

Microscopic Examination.—A section of the growth from the left side presents at some portions an irregular and unbroken epithelial border, the superficial layers of which are cornified and overlaid with an accumulation of polymorphonuclear leukocytes. At some points this epithelial border sends strands of epithelial tissue into the underlying structure. These appear as larger and smaller strands or islands, the centers of which show a concentric laminated arrangement of cornified epithelium which stains brightly with eosin. These epithelial islands are present in great numbers, but individually are small and occupy only a small part of the section. The tissue which intervenes between them is, to some extent, of a fibrous nature, but for the most part is made up of round cells, closely packed, sometimes shown in the form of cords of cells, but more frequently arranged in dense masses. Where the round cells are arranged in cords the intervening spaces present a fibrous appearance, which stains a bright blue with hematoxylin. These round cells are a little larger than a red blood cell. The nucleus occupies nearly the whole substance of the cell. It is granular in appearance. Frequently mitotic figures may be seen. A section of the growth from the right side presents the

Digitized by Google

same appearance as that described in connection with the left, but to a much less extent (Fig. 3).

From these findings we would make a diagnosis of squamous-celled carcinoma.

A microscopic section of the contiguous skin shows the superficial epithelium cornified and desquamating. Occasional points of thickening of the epidermis are noticeable by a bulging on its surface and more active cell multiplication in the lower layers. The corium is dense and more or less diffusely infiltrated by small mononuclear lymphocytes. The infiltration is more marked in the vicinity of the hair follicles and excretory apparatus. Small hemorrhages are seen here and there.

Diagnosis.—The appearance of the disease in early childhood, the six kinds of lesions present in the majority of cases, namely, lentigenous or freckle-like pigmentation, atrophic spots, vascular telangiectases, warts, superficial ulcerations and tumors render it unmistakable for any other disease. We were unable to find in the literature any form of treatment of this disease that promised a cure. At a venture we used autogenous serum, thinking it could do no harm. We gave the little girl five treatments and the lad six, at weekly intervals, with daily applications of theobroma to the skin. The general condition of the children has improved and they are gaining in weight. The improvement has seemed to result from the autogenous serum, so that if given in the beginning of the disease, I believe it would be highly beneficial.

I am indebted to Dr. Royce for the pathologic findings.

ABSTRACT OF DISCUSSION

Dr. Oliver S. Ormsby, Chicago: It is interesting to see these cases occur in family groups. They are like the family groups reported by Dr. Hyde several years ago; there are now several such families. That these growths are malignant and that the disease terminates fatally, is interesting. The disease is a type of carcinoma. Some of you may have seen the family group which was imported. One of those children developed a huge tumor in the orbit and died very soon. But we do have indigenous family groups in this country and they are interesting.

Digitized by Google

Dr. J. B. Kessler, Iowa City: The point I lay stress on in this paper was not what I did in these two cases, but what might be done if the cases had been taken in the beginning. The disease in the little girl had existed four or four and one-half years, and that of the little boy two and one-half years. He had not reached the tumorous stage, but had a growth on the cornea. I should certainly try this treatment if I got a case in the beginning. There was an apparent improvement, I did not say there was a cure; that could not be expected after it had gone as far as it had with these children.

Digitized by Google

CUTANEOUS CANCER OF THE EXTREMITIES

H. H. HAZEN, M.D.
Professor of Dermatology, Georgetown University, School of Medicine; Professor of Dermatology, Howard University, School of Medicine
WASHINGTON, D. C.

Skin cancers may arise from different layers of the surface epithelium, from different structures in the skin, such as hair follicles, sebaceous glands, and sweat glands or ducts, or from congenitally displaced epithelial structures. There are really but four important groups of cutaneous carcinomas, the prickle-celled, the cuboidal-celled, the basal-celled and the nevocarcinoma or malignant mole. The neoplasms arising from the hair follicles take on the structure and peculiarities of the basal-celled group, and the growths originating from the glands are very rare, although they do occasionally occur.

The prickle or spino-celled cancers must be sharply divided into two groups, cancer proper and the malignant wart. The former are to be clinically distinguished by their rapid growth, their deep infiltration, their rough, almost verrucose surface, and their tendency to metastasize to the lymph glands. On section the cancerous acini are large and appear as fine white lines radiating downward. The latter are distinctly wart-like from the onset, may be more or less pedunculated, and have no cancerous infiltrate at the base, although there is often an inflammatory hardness there. Microscopically both are characterized by the large size of both the alveoli and of the individual cells, and by the fact that epithelial whorls or pearls

Digitized by Google

are usually formed. The cells usually stain better with an acid than with a basic dye.

The cuboidal-celled tumors are difficult to distinguish in the gross from the preceding group. Microscopically the alveoli are large and the cells are also large, but never form epithelial pearls. These growths act very much as do the prickle-celled ones, for they frequently form growths in the glands.

The basal-celled carcinomas grow slowly, have a smooth surface, do not deeply infiltrate the tissues, and when sectioned fail to show large alveoli. On microscopic examination the cells are small and stain intensely with the basic dyes. For further details of this group, Krompecher's monograph[1] may be consulted.

The nevocarcinomas or malignant pigmented moles are not universally conceded to be epithelial in origin, as Fordyce[2] has well pointed out. Nevertheless, since certain of these tumors have been shown to be epithelial,[3] and since practically none of them have been proved to be of mesoblastic origin, it seems only right to include them in this study. As is now well known, these neoplasms usually arise from pigmented moles that have been the subject of irritation, and speedily form metastatic nodules in the skin, viscera and glands.

Because of the failure to distinguish between the various types of cutaneous cancer, many of the older articles on carcinoma of the extremities are practically worthless from a modern point of view. Howard Fox[4] has recently reported an interesting case of cancer of the hand which metastasized to the mediastinal glands, and has reviewed the literature. After studying various articles, notably those by Heimann,[5] Gurlt,[6]

1. Krompecher: Der Basalzellenkrebs, Jena, Fischer, 1903.
2. Fordyce, John A.: Melanomas and Some Types of Sarcoma of the Skin, THE JOURNAL A. M. A., Jan. 8, 1910, p. 91.
3. Gilchrist: Jour. Cutan. Dis., 1899, xvii, 117. Waelsch: Arch. f. Dermat. u. Syph., 1900, xlix, 249. Whitfield: Brit. Jour. Dermat., 1900, xii, 267. Darier: La pratique dermatologie, iii, 1903. Schalek: Jour. Cutan. Dis., 1900, xviii, 147. Ravogli: Jour. Cutan. Dis., 1901, xix, 1.
4. Fox: Jour. Cutan. Dis., 1915, xxxiii, 22.
5. Heimann: Arch. f. klin. Chir., 1898, lvii, 911.
6. Gurlt: Arch. f. klin. Chir., 1880, xxv, 421.

Digitized by Google

von Winiwarter,[7] Neumann,[8] Bulkley and Janeway,[9] von Brunn,[10] Volkmann[11] and Franz[12] he comes to the conclusion that cancer of the limbs is comparatively a rare disease as compared to cutaneous cancer in other portions of the body. Fox, referring to cancer of the hand, further says: "In spite of the malignancy of these cases from a microscopical standpoint, there can be no doubt that clinically they are relatively benign, generally running a slow course, and only late, if at all, invading the lymphatic glands." On the other hand, in a discussion[13] of this paper both Schalek and Corlett reported cases in which metastases had occurred, while Wile called attention to the fact that cancers originating in arsenical keratoses usually metastasized.

Bloodgood[14] has consistently contended that the lymphatic glands should be removed in all cases of prickle-celled cancer of the body, no matter where located, but especially on the limbs, for here it is always easy to remove the draining lymphatics. Steiner,[15] writing from the clinic of Dollinger, states that a routine practice is made of removing lymph glands in all cases of cancer of the extremities. A summary of the literature would seem to indicate that cutaneous cancers of the extremities are not especially common, that they are more common on the lower than on the upper limbs, that they always follow some precancerous conditions, that they are usually of the prickle-celled type, that they are rare on the palms of the hands, and that when occurring on the backs of the hands they are relatively benign. Regarding their

7. Von Winiwarter: Beiträge zur Statistik der Carcinome, Stuttgart 1878.
8. Neumann: Beitrag zur Kenntnis der Extremitäten-Krebse im Anschluss an zwei Fälle der Freiburger Klinik, Inaug. Diss. Freiburg im Breisgau, 1911.
9. Bulkley and Janeway: Med. Rec., New York, lxxiii, 465.
10. Von Brunn: Beitr. z. klin. Chir., 1903, xxxvii, 227.
11. Volkmann: Samml. klin. Vortr., 1889, No. 102.
12. Franz: Beitr. z. klin. Chir., 1902, xxxv, 171.
13. Schalek and Corlett: Jour. Cutan. Dis., 1915, xxxiii, 29.
14. Bloodgood: Progressive Med., December, 1904, 1907, 1908, 1912.
15. Steiner: Deutsch. Ztschr. f. Chir., 1906, lxxxii, 363.

Digitized by Google

tendency to form metastases there is considerable diversity of opinion.

With a view of clearing up the last point, which is of great practical importance, especially now that radium, the Roentgen rays, fulguration, desiccation, and similar nonoperative procedures are making great bids for the treatment of these conditions, I present the statistics shown in Table 2, derived largely from Dr. Bloodgood's surgical-pathologic laboratory of the Johns Hopkins Hospital, from the surgical wards of the Freedman's Hospital and from my own practice.

TABLE 1.—DISTRIBUTION ON UPPER AND LOWER LIMBS OF THE VARIOUS TYPES OF CANCER

	Prickle	Malignant wart	Cuboidal	Basal	Malignant mole
Upper limb...	19	5	0	4	1
Lower limb...	18	0	4	6	1
Total	37	5	4	10	2

There were a total of fifty-eight cases (Table 1). It will readily be seen that the commonest tumor is the spino-celled one, and that the basal-celled one ranks next. Malignant warts are much commoner on the upper than on the lower extremity, while the reverse is true of the cuboidal-celled carcinomas. Cancer of the upper limb is just about as common as is cancer of the lower limb.

Studying the prickle-celled growths, we find that they sprang from the following precancerous dermatoses, and that metastases occurred as shown in Table 2.

TABLE 2.—METASTASES OCCURRING IN PRICKLE-CELLED GROWTHS

Origin	Total Cases	Cases Followed Three Years	Metastatic Cases
Roentgen-ray dermatitis.....	2	2	2
Scar of burn.....	8	5	3
Scar of trauma.....	6	4	1
Ulcer	2	0	?
Wart	7	2	2
Senile keratosis.....	2	1	0
"Pimple"	4	3	1
Arsenic keratosis.....	1	1	1
Blastomycosis	1	1	0
Bone sinus.....	1	0	?
Undetermined	3	1	1
Total	37	20	11

Digitized by Google

The observation that cancer originating from Roentgen-ray dermatitis and from arsenic keratosis usually metastasizes is borne out here. Cancer springing from the scars of burns has given a rather high percentage of metastatic growths.

TABLE 3.—METASTASES WITH REFERENCE TO LOCATION OF PRIMARY GROWTH

	Total Cases	Cases Followed Three Years	Metastatic Cases
Finger	4	2	2
Back of hand	8	3	1
Wrist	1	0	?
Forearm	1	0	?
Elbow	2	1	1
Upper arm	3	2	1
Foot	2	2	1
Ankle	3	1	0
Lower leg	7	4	2
Knee	2	2	1
Thigh	4	3	2

With respect to the influence that location of the primary growth has on the liability to metastatic formation I present Table 3.

In such a small series of cases it is impossible to determine just what influence position has on the liability toward metastasis, but it would appear to have very little. The high percentage of metastases in the followed cases is notable. It will probably be objected that most of these cases were surgical ones, and that they were severe cases and of long duration. Now, as a matter of fact, in six of the metastatic cases, the primary cancerous changes had been present for three months or less. In one notable case there was a cancer of the lower leg that had existed for two months. Under divided doses of the Roentgen rays the primary growth healed and stayed healed, but five years later metastases developed in the inguinal glands and the patient succumbed. In the other ten instances recurrence in the glands followed amputation in five cases and local surgical removal in five. The nine patients who stayed cured for more than three years were all subjected to local operation alone.

Digitized by Google

A study of these few figures should clearly show that prickle-celled cancer of the skin is comparable to cancer of the breast, tongue or lips, and just as no good surgeon would think of treating a true cancer of these organs by local removal alone, so should he shrink from the mere local removal of an analogous condition of the cutis. In many instances it is impossible to tell the exact nature of a cutaneous cancer. Here the correct procedure is undoubtedly to excise the entire growth and then make a study of it. To attempt to cure a malignant neoplasm of the limbs without first ascertaining its nature is both foolhardy and dangerous, to say the least, and will undoubtedly result in the sacrifice of many lives.

There were four cases of cuboidal-celled cancer, one of which originated from a varicose ulcer of the leg and was cured by the cautery. One developed on the scar of a bed sore on the thigh and was cured by local excision. Another originated in a senile keratosis on the thigh and recurred in the inguinal glands seventeen months after local excision. The last occurred in the scar of a trauma on the thigh, and promptly recurred in the inguinal glands after local excision. All growths were of less than one year's duration. All were in women. It is plainly evident that cuboidal-celled cancer is analogous to spino-celled cancer in the way that it metastasizes, and that it should be treated accordingly.

There were five cases of malignant warts, three on the back of the hand, one on the wrist and one on the forearm. All originated in warty growths. Bloodgood,[16] in a careful study of malignant warts, comes to the conclusion that they never metastasize and that complete local removal is sufficient to effect a cure. Yet in one case in this series metastasis and death did follow a local operation, probably not a complete one. Inasmuch as these growths are more common

16. Bloodgood: Progressive Med., December, 1904, p. 147.

Digitized by Google

on the back of the hand than elsewhere, inasmuch as they show a spino-celled structure, and inasmuch as they very rarely metastasize, it is probable that those who have stated that cancer of the hand is a benign affection have had most of their experience with this variety of tumor.

There were ten basal-celled cancers, which arose from the following dermatoses:

Ulcer	6
Scar or burn	1
Pigmented mole	1
"Pimple"	1
Nodule	1

They arose in the following areas:

Finger	1
Hand	1
Upper arm	2
Ankle	1
Lower leg	4
Thigh	1

In one remarkable case the glands later developed metastatic growths that showed all of the peculiarities of a spino-celled carcinoma. So far as known there were no other metastases in this group.

In two instances there were multiple melanotic growths, secondary to pigmented moles. One occurred on the arm of a woman who had suffered but a single trauma to a pigmented mole. This immediately ulcerated and was excised, but promptly recurred. During the next five years there were a number of local operations. She then entered the hospital with a mass of inoperable glands in the axilla, but with no signs of metastatic growths in the body. It is more than probable that a complete early operation, including the axillary glands, would have resulted in permanent cure. The other instance occurred in a negro man, this being probably the only case on record of a malignant mole in one of this race. The primary growth was in the sole of the foot. There were metastases both to the glands and to the lungs, and death speedily ensued.

Digitized by Google

CONCLUSIONS

1. Carcinoma of the skin of the limbs is not a common affection.

2. The majority of skin cancers arising in these locations are prickle-celled neoplasms, and the majority of these metastasize, some at an early date.

3. Inasmuch as a certain diagnosis can only be made in the early cases by the gross or microscopic appearance, and inasmuch as it is usually deemed unsafe to excise a bit of tissue for examination, it is plain that the proper treatment is to excise the growth in toto and make the diagnosis from the entire growth. If it is found to be of a cuboidal or spino-celled variety the neighboring glands should be removed.

4. The basal-celled growths can be treated by local removal with perfect safety.

5. It is possible that the prognosis in some cases of malignant mole is not absolutely bad if a wide local and glandular operation be done at the onset.

6. Malignant growths always arise from a preexisting abnormality, so are usually preventable.

The Rochambeau.

ABSTRACT OF DISCUSSION

Dr. A. Ravogli, Cincinnati: This paper has a great deal of practical interest on account of the frequency with which we see these growths on the hands. I see very often—especially in farmers—the beginning of epithelioma on the back of the hands, between the thumb and index finger, on the metacarpal region of the hand. Sometimes they are of very slow growth, and take a long time until they reach a certain point, after which they grow very fast. As the author stated, they involve the epitrochlear and subaxillary glands in a brief time.

The question of blastomycosis has to be overruled. I had a case sent to me as carcinoma of the hand, and I found it necessary to remove all the affected tissues, which I did; instead of having a resistant tissue, there was only a decayed condition, like a poultice. I found under the microscope that this was a case of blastomycosis, which has a very deleterious action in the tissues, and sometimes affects the subaxillary glands. Sometimes I have seen the

Digitized by Google

epithelioma of the back of the hand preceding that of the lower lip. I find there is some relation between those parts by rubbing the lips with the back of the hands. In a gentleman from Indiana with an epithelioma, first on the back of the hand, and then on the inferior lip, I obtained perfect recovery. I removed the growth with a curet and cauterized it with my method. Then he was treated with Roentgen rays. He died at about 74 or 75 years of age, and the reproduction of the epithelioma was not verified. When we put the knife in these growths we open the blood vessels and make possible the absorption of cancerous cells into the blood or lymph circulation, or underneath the tissues. Therefore, according to my experience, the best thing is scraping with a sharp curet the epithelioma, and after scraping, the use of the caustic.

Dr. Sherwell claims great good with strong nitrate of mercury. I advocate my method of compound solution of cresol, formaldehyd and perchlorid of iron, mixed in the same proportions and applied on a tampon of cotton for five or ten minutes. The formaldehyd has a peculiar cornifying action on the epitheliomatous cells, the compound solution of cresol dissolves the plasma cells, which involve the cancerous elements forming the little nests; and then the perchlorid of iron stops the lymphatic blood and vessels, preventing absorption. In the case of the Indiana farmer I had splendid results with this method.

Dr. Richard L. Sutton, Kansas City, Mo.: This paper of Dr. Hazen is an extremely interesting one, and contains far more than would appear on first thought. He has his own statistics and those of Dr. Bloodgood. They are not clinical statistics, but statistics backed by pathologic findings.

I have seen but few cases of cancer of the limbs. They are rare in the Middle West, as well as elsewhere. But carcinoma of the dorsal surface of the hands is fairly common. In the majority of instances the lesions are of the squamous variety, and in my experience secondary involvement of the lymph nodes is not unusual. Consequently the only safe plan of treatment is radical excision, followed, if the subsequent histologic examination and symptoms should indicate it, by removal of the neighboring lymph nodes. Superficial cauterization with carbon dioxid snow, silver nitrate, and similar agents is worse than useless; it is criminal. Roentgen and radium therapy may be employed as an adjuvant measure, but if the operation is properly performed these agents will not be needed. Above all, I would suggest that one be exceedingly careful in dealing with these cases. Early and radical treatment is indicated, and there is far more danger of undertreatment than of overtreatment.

Digitized by Google

Dr. Douglass W. Montgomery, San Francisco: Epithelioma of the extremities is not frequent. Dr. Culver and I have had some cases, but we have not had any with metastases. One patient I saw not long ago was of peculiar interest diagnostically. The lesion lay behind the external malleolus, and when the patient came to me first some years ago it was very small and looked like a small ulcus cruris. Recently I was called to see the patient in consultation, and the ulcer had grown in the meantime and resembled a gangrenous ulcer of the leg of the fulgurating type, due to streptococcic infection. I advised treatment in accordance with this opinion.

I was subsequently again called in consultation, and as I examined the lesion it struck me that its border was altogether too rolled and too large for ulcus cruris, and it gradually dawned on me that the lesion was an epithelioma. Its treatment presented a very grave question. To cut it out as recommended here today would involve such loss of tissue that an amputation would be preferable, and yet an amputation for such a lesion would not commend itself to the patient. Nevertheless, we are compelled from Dr. Hazen's findings to accept the fact that these growths are much more dangerous than I, for one, ever realized.

Dr. Harry E. Alderson, San Francisco: The fact that half-way measures in the treatment of these conditions are extremely dangerous cannot be too strongly repeated and emphasized. I think most of us agree in the use of the Roentgen ray as intensively as possible. Most of the cases of complicated epithelioma are in patients who have had the early lesion treated with the half-way measures advocated from time to time.

Dr. George M. MacKee, New York: I agree that the best way to treat a malignant epithelioma is by excision. The knife, however, should not enter the growth. If there is the slightest suspicion that malignant cells have been left in situ either radium or the Roentgen ray should be employed as a postoperative prophylactic measure, and this treatment should also be applied to the neighboring lymphatics. The fact that some cases of malignant cancer will respond to radium or the Roentgen rays without the aid of surgery certainly speaks in favor of using these agents postoperatively. It should be remembered that the basal-cell epithelioma is sometimes fatal. I have seen three cases end in death. I have never seen a basal-cell epithelioma change its character and become a squamous-cell growth. I have personally seen only one case of basal-cell epithelioma on the back of the hand. This was in a young man who had taken arsenic for several years. He suffered from arsenical pigmentation, palmar keratoses and had about fifty superficial basal-cell epitheliomas scattered over the body.

Digitized by Google

Dr. Everett S. Lain, Oklahoma City: This has been especially interesting because Dr. Hazen, Dr. Sutton and Dr. MacKee are leading writers on epithelioma, and the statistics given are corroborative of my own in treating epitheliomas of the extremities. My treatment of this disease on the hands has not been very satisfactory. In fact, in my paper I say this location on the body is most unsatisfactory. The first step, I believe, is to block the absorbing channels, the blood vessels, with the Roentgen ray, and then turn the patients over to the surgeon.

Dr. Howard Fox, New York: In regard to the frequency of cancer of the extremities, we have heard the statistics of Heimann, who showed that out of twenty odd thousand cases of cancer in general, only 207 affected the extremities. That is indeed a small proportion. My study of a year ago was confined to cancer of the hand. I found that cancer of the hand is microscopically malignant, though it seems to run a comparatively benign course clinically. My conclusions were based on a résumé of the literature, and not from personal experience, as we see few cases of cancer of the hand in New York. I agree with Dr. Sutton that in possible cases of cancer of the hand or extremities a microscopic examination should always be made to avoid mistakes in diagnosis, as in my case, in which the possibility of an epithelioma did not occur to any of those who examined the lesion.

Dr. H. H. Hazen, Washington, D. C.: I think carbon dioxid snow is one of the most abominable things ever brought out. I have seen four cases on which snow had been used, and each one was made worse, although pronounced a cure by the men who applied it. No more carbon dioxid for me in the treatment of cancer.

I think probably dermatologic excision with a knife would open up the channels, but not a surgical excision. By a proper surgical excision I mean cutting one-half an inch outside the malignant area, and not getting the knife into any of the cancerous material. I fear that dermatologic operations are less radical.

Dr. Ravogli referred to the curet and cauterization with nitrate of mercury. Dr. Sherwell admits that he has not followed these cases, but thinks he has had about 10 per cent. of recurrences.

We do not follow our cancerous cases as we should. In Bloodgood's clinic, there were three or four cases which were curetted and cauterized afterward. We tried to trace them up through the physicians who sent them in, but none of them had followed them up.

There is one way of taking out a cancer when there is little margin, and that is by the actual cautery, as in cancer of the lip and tongue. I think that is preferable to the

Digitized by Google

knife, and you have material for pathologic study. We do not want to produce any larger scar than necessary, but the cure is many times more important than the cosmetic result.

I want to make it plain that we must distinguish between prickle and basal-celled neoplasm. The latter can be removed locally, and the former should be so treated as to block the migration of the cancer cells. The statement that basal-celled growths become malignant can be explained by the fact that cuboidal-celled tumors are often mistaken for basal-celled ones, and also that a basal-celled tumor may occasionally change in type.

Digitized by Google

THE ROENTGEN-RAY TREATMENT OF SKIN DISEASES *

GEORGE M. MacKEE, M.D.
Instructor in Dermatology, College of Physicians and Surgeons, Columbia University; Chief of the Department of Dermatology and Syphilology, Vanderbilt Clinic; Consulting Dermatologist, St. Vincent's Hospital; Visiting Dermatologist Sea View Hospital
NEW YORK

THE DERMATOLOGIST AND THE RADIOLOGIST

Now that Roentgen-ray work is becoming highly specialized, there seems to be a tendency to separate dermatology from roentgenotherapy. This is both desirable and undesirable. So far as concerns the Roentgen-ray treatment of skin diseases, two general attributes are essential — a knowledge of dermatology and skill in modern Roentgen-ray technic. The dermatologist possesses the former and he can easily acquire the latter, for the difficulties are more imaginary than real. The pure roentgenologist, while being expert in Roentgen-ray technic, lacks a dermatologic training, as also do many of the physicians who refer patients to him for treatment. To avoid errors in diagnosis and the obvious consequences, it would seem advisable to adhere to one of three schemes: for the dermatologist to employ the Roentgen ray; for the roentgenologist to have at least a clinical knowledge of dermatology; or for both to combine their skill in behalf of the patient.

TECHNIC

In a short, practical paper of this kind it is not possible actually to describe a technic. A general outline of modern methods may, however, be of interest.

* From the Department of Dermatology and Syphilology, College of Physicians and Surgeons, Columbia University, New York.

Digitized by Google

Two methods are in vogue at the present moment, namely, intensive and divided doses.

Intensive Method.—Here the quality of the ray used is ascertained by direct measurement (Benoist, Walter or Wehnelt instruments), while it is maintained by means of indirect measurement (milliamperemeter, spark-gap, etc.). The quantity is measured directly, through the employment of reliable radiometers such as those originated by Holzknecht and Corbett. In this way every dose is estimated as accurately as modern science will allow. An intensive treatment may consist of enough ray to produce a second degree Roentgendermatitis, a simple erythema, a loss of hair without erythema, or a dose that is too small to produce a visible effect on the normal skin, but yet too large to allow of its repetition within three or four weeks. The method is thoroughly established and is sufficiently accurate for all practical purposes. No better example of its accuracy can be demanded than the excellent results associated with the intensive Roentgen-ray treatment of ringworm and favus of the scalp.

There is a difference of opinion regarding the quality of ray to be employed in different cutaneous diseases. Contrary to the general consensus, I have found a "hard" ray (B 8 to 10) preferable for routine work and seldom use a ray of lower penetration.

In considering the quantity, the question of idiosyncrasy and susceptibility should be discussed. True idiosyncrasy must be a very rare phenomenon. Again I direct attention to thousands of cases of tinea tonsurans that have been treated with intensive Roentgen radiation without a single example of idiosyncrasy having been encountered. As a matter of fact, as an operator becomes more expert and experienced he employs the term less frequently. I do not deny the possibility of true idiosyncrasy—it undoubtedly does exist—but it is extremely uncommon. Hypersusceptibility, on the other hand, is very common. Some parts of the body are more sensitive than others. The skin of aged individuals will tolerate larger doses than will the integument of children. Chemicals, such as iodin, tar, mercury, chrysarobin, salicylic acid, etc., will markedly enhance the action of the ray. The skin of individuals suffering from certain diseases—mycosis fungoides, goiter, eczema, psoriasis—may be hypersensitive. The intensive dose will vary in amount according to the effect desired and the disease treated. In epithelioma, it will be in the neighborhood of 8 or 10 Holzknecht units; in keloid, from 4 to 6 units; tinea tonsurans, 4 to 5 units; eczema and psoriasis, 2 to 3 units, etc.

Digitized by Google

Divided Method.—The divided technic is not as accurate and in some diseases it is not nearly as efficacious as is the intensive method. In fact, there are diseases, such as epithelioma and tinea tonsurans, in which the divided method may even prove injurious. On the other hand, in diseases in which stimulation is beneficial (eczema, psoriasis, etc.) it is as good if not actually superior to intensive treatment. In speaking of the divided method it must be recognized that we are dealing with a modernized technic and not with former obsolete methods in which from 50 to 200 exposures were administered in the treatment of an epithelioma. As a matter of fact, the divided method of today, when compared with older technics, is decidedly intensive.

Briefly the technic is as follows: Certain fixed indirect factors are established and used as "constants." That is to say, the anode of the tube is always at the same distance from the skin; the milliamperage, the spark-gap distance, the length of the conducting wires, the speed of the motor, the transformer cycle, the rheostats, and, in fact, all adjustable parts are always employed in exactly the same manner for every treatment. Now, with all these "constants" established the time necessary to produce the so-called pastille or erythema dose (about 5 H) is ascertained. Let us assume that the required time is twenty minutes. This may be divided into four treatments of five minutes each or eight treatments of 2½ minutes each, and administered at intervals of from three to seven days, so that the full erythema dose is given in the course of one month.

There are several technics for the divided method; it will vary according to the apparatus employed, and, also, in accordance with the training, skill and experience of the operator. Personal equation is an important factor.

DISEASES AMENABLE TO ROENTGEN-RAY TREATMENT

INFLAMMATIONS

Erythema Induratum (Bazin's Disease). — This affection, now known to be a true but benign type of cutaneous tuberculosis, yields readily, as a rule, to the Roentgen ray. One intensive (suberythema) dose will usually suffice to produce a cure in the ulcerative type of the disease. The subcutaneous nodules are more rebellious. Rest, hygiene, tonics, etc., will usually suffice to cure this disease in a few months, but in stubborn cases the Roentgen ray is of considerable service.

Digitized by Google

Granuloma Annulare.—I have treated only one case of this disease. The patient presented numerous tumors on the hands, arms and ears. Each lesion disappeared under the influence of a single treatment of 4 H units of a B 9 ray — in other words, a suberythema dose. The Roentgen ray, of course, will have very little if any influence on the future course of the disease.

Prurigo.—Small doses of Roentgen ray produce favorable effects in this recalcitrant juvenile affection, chiefly through its antipruritic powers. It does not materially alter the course of the disease. The divided-dose technic is indicated here and after one course of treatment an interval of several months should elapse before another course is given in order to avoid possible injury to the epiphyses.

Lichen Planus.—From a practical point of view the Roentgen ray is of service only in the hypertrophic type of the disease, when there are a few isolated, resistant patches. Here it is extremely efficacious. A few days after a single suberythema dose the itching ceases and in two or three weeks the lesions disappear.

Psoriasis.—Ordinarily, psoriasis is easily controlled by the proper use of dermatologic remedies, so that the use of the Roentgen ray is limited to resistant lesions or to the so-called inveterate patches of the disease. The psoriatic skin is hypersensitive to Roentgen radiation, possibly on account of the previous use of chrysarobin or other irritating chemicals. For this reason and, also, because, as a rule, very little ray is required, it is preferable to employ the divided-dose technic. In stubborn cases the Roentgen ray will be found of real value.

Eczema.—In eczema the Roentgen ray is of service only in the subacute, chronic and rebellious types of the disease, especially where there are a few isolated, thickened, pruritic patches that have resisted ordinary measures. There is, however, one exception, namely,

Digitized by Google

the acute or subacute vesiculosquamous eczema occurring in patches on the dorsal surfaces of the hands and fingers. Here the Roentgen ray is exceedingly efficacious, and is specifically indicated, because this clinical type of the disease is notoriously rebellious to all other therapeutic measures. The obstinate keratotic eczema of the palms and soles will usually yield rather promptly to the Roentgen ray after refusing to respond to other forms of treatment. In most types of eczema, as in psoriasis, the Roentgen ray is not indicated until regular dermatologic remedies have been tried, for, as a rule, the simpler measures will suffice. Again, as in psoriasis, and for the same reasons, the divided-dose technic should be employed.

Lichenification and Lichen Circumscriptus.—In these affections, a single small dose of the Roentgen ray will usually suffice to overcome the itching at once and cause the eruption to disappear in a few weeks, especially if the treatment is reinforced by ordinary dermatologic remedies. The divided technic gives equally good results.

Pompholyx (Disidrosis). — Fractional doses of Roentgen ray are a help in combating this not infrequently stubborn affection.

Hypertrophies

Clavus, Callositas and Verrucae.—Corns will usually respond to one or two intensive doses. It is necessary, however, in order to avoid recurrences, to ascertain and overcome the cause, such as pressure from tight or improper shoes. Some of my most brilliant therapeutic results have been obtained in the Roentgen-ray treatment of callositas, or painful plantar warts; certainly the patients are very grateful for the relief. I know of no other treatment that can compare with the Roentgen ray in efficiency. The thickened horny layer should be removed with a razor and then an intensive dose of the Roentgen ray administered. The first treatment may consist of H 4, B 9.

Digitized by Google

In some instances this one application will suffice. More often, however, a second treatment will be necessary, and this should not be given in less than four weeks from the first application, and the dose may be increased, unless contraindicated, to H 6, B 9. I have never been compelled to give more than three treatments to produce a complete cure, and as yet I have not had a single recurrence. My results with the intensive treatment have been far superior to those obtained before I developed the intensive technic. The common wart (verruca vulgaris) will usually disappear as a result of a single intensive treatment. Not infrequently the treatment of one wart will cause the disappearance of similar lesions in the same neighborhood. Various types of hyperkeratosis may be influenced by the Roentgen ray, such, for example, as senile keratosis, keratosis palmaris et plantaris, ichthyosis, keratodermia, etc.

New Growths

Keloid.—Excellent therapeutic and cosmetic results can be obtained in hypertrophic scars, traumatic and "spontaneous" keloids and acne keloid (dermatitis papillaris capillitii). The Roentgen ray is indicated in these affections not only because of its efficacy, but because there is no other reliable treatment. In very large keloids it is preferable to ablate and then apply the Roentgen ray as a prophylactic. This may be done, also, in small keloids, in order to obtain a perfect cosmetic result. I have never observed a recurrence after Roentgen-ray treatment. Unfortunately, keloid requires large quantities of Roentgen ray, and for this reason the intensive method is to be preferred. A well-developed keloid will necessitate from two to six intensive treatments. It is not safe to apply more than six or eight intensive doses at intervals of from four to six weeks, because of the danger of permanent injury to the skin. In very obstinate

Digitized by Google

cases it is preferable to intervene surgically and employ Roentgen ray as a prophylactic, or to give the intensive doses in courses, each course consisting of three treatments at intervals of four to six weeks, with an interval of one year between courses.

Nevus Vasculosus.—The Roentgen ray is capable of producing good results in vascular nevi. The treatment is apparently more efficacious in deep-seated nevi (cavernous angioma) than in the superficial "portwine" marks. In the past, judging from the literature, radium has produced better results in this affection than has the Roentgen ray, but perhaps the future will see the two agents favorably compared in this respect. More experimental work is required, especially in regard to the quality of ray to be used. The few cases that I have treated have required several intensive doses of a "hard" ray before much effect was observed. It is possible that a "soft" or even an "oversoft" ray will prove more effective.

Rinoscleroma.—The Roentgen ray is almost a specific in this rare, disfiguring and uncomfortable disease. It should be employed intensively, and on account of the fibrosis a well-filtered, "hard" ray is indicated.

Tuberculosis Cutis.—In the literature one finds reports of cures obtained with the Roentgen ray in tuberculous ulcers of the skin and mucous membranes, but I have found such lesions exceedingly stubborn unless of a benign type, such as lupus vulgaris or tuberculosis verrucosa cutis. The hypertrophic and ulcerative types of lupus vulgaris, even when involving the mucosa, usually yield to from one to three intensive doses. The atrophic type of disease, with deeply embedded (apple-jelly) nodules, resists the treatment; at least this has been the case in my hands. In the treatment of lupus vulgaris I have found the intensive technic superior to the divided dose method. Relapses may occur, but not as a rule. Personally I

Digitized by Google

have not had a single recurrence where the patient remained under treatment until the lesion completely disappeared.

Tuberculous adenitis, with or without scrofuloderma, yields good results with the intensive treatment. Here my best results have been obtained by the use of a "hard" ray filtered through 3 mm. of aluminium, the dose ranging from 4 to 8 H; several treatments are necessary as a rule.

Tuberculosis verrucosa cutis, if the warty excrescence is first removed by the curet, will yield to a single intensive application. Otherwise several treatments may be necessary. The cure seems to be permanent.

Lupus Erythematosus.—Although records of cures of lupus erythematosus by means of Roentgen radiation are found in the literature, I have failed to cure a single instance of the disease by this method and therefore I prefer other measures, such as the solid carbon dioxid. It seems unwise, in lupus erythematosus and atrophic lupus vulgaris, to apply enough ray to permanently injure the skin, because these diseases seem to invite the development of malignant epithelioma and excessive Roentgen-ray dosage simply adds fuel to the fire.

Epithelioma.—The ulcerative type of basal-cell epithelioma (rodent ulcer) can be completely cured with one erythema dose. The nodular type may require two or three treatments unless the lesion is first curetted. Recurrences are uncommon, there is no pain, no scarring and no interference with business, so that it would seem that the Roentgen ray might be considered the method of election in the treatment of this affection. There are cases, however, that will not yield to the Roentgen ray, but, fortunately, such instances are extremely uncommon. The most rebellious examples that I have encountered are those in which the lesion had been treated by obsolete Roentgen-ray methods. A few years ago it was not

Digitized by Google

uncommon to hear of an epithelioma receiving as many as 150 Roentgen-ray treatments — small, oft-repeated, stimulating doses. These lesions improved to a certain extent and then became very recalcitrant to all forms of treatment; or if they healed under the influence of the Roentgen ray they were very likely to recur. The explanation is possibly that so many stimulating doses taught the tissues to resist the beneficial action of the Roentgen ray; again, it is possible that so much ray produced an analogous effect to that seen on the hands of the pioneers in Roentgen-ray work. It would, therefore, seem advisable to employ intensive treatment and to obtain the maximum benefit with the minimum amount of ray.

I have had occasion to treat a number of benign epitheliomata that had been previously rayed by obsolete methods, and while most of them have responded to the intensive technic, some have remained unaffected and many of them have recurred within a year or two. In general it may be said that the longer the lapse of time subsequent to former Roentgen-ray treatment, the greater is the chance of recovery under the intensive technic.

In squamous-cell (malignant) epithelioma of the skin the Roentgen ray is uncertain, although very brilliant results are occasionally obtained. Personally I prefer to elicit surgical aid in these instances and employ the ray intensively as a prophylactic, unless, indeed, the case is inoperable. The fact that the Roentgen ray will occasionally cure malignant epithelioma warrants its use in inoperable cases, and as a prophylactic in postoperative cases. In such instances it is wise, also, intensively to treat the neighboring lymphatics, even when these are not palpable.

The same remarks may be repeated in discussing epithelioma of the lips, tongue and other mucous surfaces. I have cured (temporarily at least) a number of epitheliomata of the lip, but they have been superficial and the glands were not involved. At the pres-

Digitized by Google

ent moment it would seem advisable to refer lip cases to the surgeon and rely on the Roentgen ray as a prophylactic, unless the disease is detected in the earliest stages or unless the case is for any reason inoperable. In regard to epithelioma of the tongue, buccal mucosa and glans penis, I refer all such cases to the surgeon as soon as the diagnosis is established.

Paget's disease, especially if diagnosed early, will yield to a single erythema dose. The preepitheliomatous lesions (keratoses) occurring in xeroderma pigmentosum can be removed by intensive Roentgen-ray radiation. This is interesting, as such lesions are supposed to be caused by the action of direct or indirect sunlight on a peculiarly susceptible skin. In this connection, too, the keratoses produced by the Roentgen ray can be cured by this same agent, especially if employed intensively, and especially, also, if the parts have not been exposed to the Roentgen ray for several years. Senile keratoses (senile verruca, seborrheic warts), which are forerunners of epithelioma, readily respond to a single erythema or even a suberythema application of the Roentgen ray. If there is much thickening of the horny layer, it is advisable to use the curet in order to ensure recovery with one application of the ray.

Sarcoma Cutis.—Sarcoma of the skin and, also, of the glands, will not infrequently respond promptly to Roentgen radiation if properly administered. In fact the results have been so good that the Roentgen ray should always be considered, either with or without surgery, in the treatment of this fatal malady. In treating a sarcoma the lymphatics draining the region should also be Roentgen rayed. While, in my hands at least, the effect of the Roentgen ray on sarcoma is more certain than in the case of malignant epithelioma, yet it cannot be relied on and should not replace surgery. The fact, however, that many cases of sarcoma will yield to the Roentgen ray warrants its employment in postoperative recurrences and in inoperable

Digitized by Google

tumors. There are clinical types of sarcoma that are relatively benign, such, for instance, as Kaposi's multiple hemorrhagic sarcoma, which can be successfully controlled by the Roentgen ray alone. On the other hand, I have seen cases of malignant sarcoma that failed to respond to any treatment. In most instances the respite offered by the Roentgen ray is but temporary, for sooner or later, as a rule, the patient will succumb either to a metastatic or the primary growth in some other part of the body. In all examples of sarcoma the ray should be employed intensively.

Mycosis Fungoides (Granuloma Fungoides).—Brilliant temporary results may be achieved in this incurable affection by the proper use of the Roentgen ray. The lesions both in the premycosic and tumor stages, involute under the influence of small doses. This is fortunate, because the skin of patients afflicted with mycosis fungoides is likely to be hypersensitive to the Roentgen ray. For these reasons it is preferable to employ the divided technic, or if the intensive method is utilized, the initial dose should not exceed H 2, B 9 or 10. Again, especially at the beginning, considerable caution must be exercised against the possibility of a systemic reaction provoked by a too rapid involution of the lesions. For this reason not more than one or two lesions or areas should be treated at one time. I personally prefer the intensive treatment of mycosis fungoides. After one or two treatments the exact quantity necessary to cause a complete disappearance of the lesion is ascertained, and then this quantity is administered to a different lesion or area each week. After an intensive application it requires from two to four weeks for complete involution, so that when such a treatment is given each week there is a gradual increase of the strain on the system which is accompanied by the necessary toleration. I have never personally encountered the severe systemic reactions following the use of the Roentgen ray that are found in the literature. The most that can be hoped

Digitized by Google

for in the Roentgen-ray treatment of mycosis fungoides is to keep the patient in good health and comfortable for a few years. Sooner or later, if death does not occur from some intercurrent affection, the disease will cease to yield to the Roentgen ray and the patient succumbs. In this respect splenomyelogenous leukemia is a striking analogy. The best result in my series of cases is in a case that is still under observation. The patient was first treated by Howard Fox six or seven years ago when he was literally covered with lesions, which disappeared under Roentgen-ray treatment. Later, during a relapse, he was treated by Fordyce with the same good result. I have had him under observation for two years. He is in the best of health, but occasionally there develops a split-pea sized tumor which promptly disappears under the influence of one dose of H 2, B 9. On the other hand, I have seen instances in which the disease was malignant almost from the beginning and in which new lesions developed faster than the older ones disappeared.

Leukemia Cutis.—I have treated only one example of this malady — a patient who was kindly referred by Dr. J. C. White. As a result of my best efforts neither the disease nor the lesions were materially benefited.

Lepra.—The literature contains reports of the efficacy of the Roentgen ray in leprosy. We have a series of cases under treatment at Dr. Fordyce's clinic, but as yet no material improvement has been noted. I remember treating a patient some eight or ten years ago, but the result was not striking, although the patient failed to continue the treatment for a sufficiently long time to make the observation of much value.

Neuroses

Pruritus.—The itching accompanying mycosis fungoides, some types of eczema, prurigo, lichenification, lichen planus, and lichen circumscriptus, often disap-

Digitized by Google

pears after small doses of the Roentgen ray. The Roentgen ray does not seem to have much influence in allaying the itching of acute and more or less transient dermatoses such as urticaria, the parasitic affections, etc.

Personally I have had very little success with either the divided or intensive technic in the treatment of pure pruritus, such as senile pruritus, pruritus vulvae, pruritus ani, etc., although occasionally good results are obtained.

DISEASES OF THE APPENDAGES

A. Diseases of the Nails

Onychia.—Although good results may be obtained in psoriasis and eczema of the nails, these diseases in this location are likely to be exceedingly rebellious to Roentgen-ray treatment. The same may be said of onychia and paronychia of unknown etiology. I am not prepared to say which of the two methods (divided or intensive) is the better for the treatment of diseases of the nails.

B. Diseases of the Hair and Hair Follicles

Hypertrichosis.—It is possible to obtain good results in this condition, but not without considerable danger of disfigurement. The epilating dose will cause hair to fall out without the advent of an erythema. The defluvium will occur about three weeks after the treatment and the hair will regrow in from one to three months. A second epilating dose should be given about six weeks after the first application, before the follicles have regenerated. At times the two treatments will suffice to produce permanent alopecia, but more often it is necessary to administer three or four or even five similar treatments. Permanent alopecia is produced by an atrophy of the hair follicles. At the same time it is impossible to avoid atrophy of the other glandular appendages and, also, a certain amount of atrophy of the epidermis and even of the dermal

Digitized by Google

tissues. The end result, therefore, may be a slight wrinkling of the skin, and in some instances, more or less telangiectasia. In some cases, especially on the body, or where the growth of hair is exceedingly heavy on the face, Roentgen-ray treatment would appear justifiable, but the patient and the patient's immediate relatives should thoroughly understand the possible consequences. On the whole, I am in accord with the general consensus of opinion, namely, that hypertrichosis should not be treated with the Roentgen ray. The epilation dose will vary according to the location; it should never exceed H 5, B 9-10, and on the face the initial dose should not be in excess of H 2 or 3. It is a notorious fact that a downy growth (lanugo hair) is far more difficult to remove than is coarse hair.

Sycosis Vulgaris.—Some cases of this affection will yield to a surprisingly small amount of Roentgen ray. In such instances it is possible that the soil is modified by the production of autogenous vaccines. It is quite certain that the Roentgen ray has no direct action on the pyogenic bacteria. In other cases it is necessary to continue the treatment until permanent alopecia is obtained, and, finally, there are instances in which the disease continues even after the advent of permanent alopecia. A few patients at Dr. Fordyce's clinic received divided treatments on one cheek, while the corresponding cheek received intensive doses (H 4, B 9-10). The results did not differ materially, excepting that the intensive treatment was a trifle more efficacious.

Diseases of the Sebaceous Glands

Seborrhea.—Oily seborrhea of the face sometimes improves under a few divided doses. More often, however, it fails to respond until atrophy of the sebaceous follicles is obtained. In such instances it is preferable to abandon the Roentgen ray because of the danger of permanent and visible injury to the skin.

Digitized by Google

Eczema seborrhoeicum of the body, especially when of the psoriatic type, has been successfully treated with the Roentgen ray, but other measures will usually suffice and are to be preferred.

Comedo.—At times "blackheads" will disappear after a few divided doses. If, however, the condition is rebellious, as is likely to be the case, it is not advisable to produce an atrophy of the cutaneous appendages for the reasons mentioned in discussing hypertrichosis.

Acne Vulgaris.—As a rule this affection responds readily to the Roentgen-ray treatment. Acne indurata yields much more quickly than do the other forms of the disease — acne pustulosa, papulosa and comedo. Occasionally a case of acne is encountered that will not respond to the Roentgen ray. Again, it is not uncommon to see the disease relapse in a few months. These recidives, however, respond as readily as do the original attacks. Although the Roentgen ray is virtually a specific in this disease, its use is not justified until other methods of treatment have been given a trial. The majority of cases will respond to hygiene, diet, internal medication, vaccines and the local use of appropriate chemical agents. On the other hand, if the condition is at all obstinate, the use of the ray should not be delayed, as the disease is likely to produce undesirable sequelae, such as scars, dilated follicles, seborrhea and, perhaps, hypertrichosis. Considerable caution must be exercised in the Roentgen-ray treatment of acne in order to avoid visible atrophy, telangiectasia and radiodermatitis. For this reason one should employ a safe dose even when the disease fails to respond, and in order to obtain the maximum effect with the minimum amount of ray, recognized dermatologic remedies and measures should also be employed. Inasmuch as the disease responds at times to very small doses and, also because local stimulants are employed, the divided technic is indicated,

Digitized by Google

although I frequently employ small intensive applications with equally good results.

Rosacea.—The acne that is so often associated with rosacea will, of course, respond to Roentgen-ray treatment, but I have had very little success with the Roentgen ray in the treatment of pure rosacea. The same can be said regarding hypertrophic rosacea and rhinophyma.

Diseases of the Sweat Glands

Hyperhidrosis.—Brilliant therapeutic effects may be obtained in excessive sweating of the axillae, hands and feet. Hyperhidrosis of the arm pits is often associated with intertrigo, eczema and bromidrosis, all of which may be relieved by roentgentherapy. It usually requires about four treatments, each consisting of H 3 or 4, B 9-10, at intervals of four weeks, to produce the desired relief. This will also cause permanent alopecia and occasionally slight atrophy. When treating the hands it is advisable to employ Pirie's instrument, which allows of equal dosage to the entire palmar surfaces of the hands and fingers.

Parasitic Diseases

Tinea Tonsurans.—Ringworm of the scalp and, also, favus of the same region, should be treated by the Kienböck-Adamson method, which consists of applying the epilating dose to five different areas mapped out on the scalp. Three weeks subsequent to the Roentgen-ray treatment defluvium occurs over the entire scalp. The hair regrows in from six weeks to three months. The Roentgen-ray has no direct action on the parasites, but it is possible that the soil is so modified that they find a less favorable medium on which to grow. The defluvium, however, is probably the main factor in affecting a cure. As a rule, it is advisable to depilate the entire scalp, but if there are but one or two small patches of disease, the hair may be removed only from these areas. Not infrequently,

Digitized by Google

Fig. 1

Fig. 2

Fig. 1.—Granuloma annulare.

Fig. 2.—Same as Figure 1 after one dose consisting of H 4, B 9.

Fig. 3.—A group of hypertrophic lichen planus papules on the wrist. Also two common warts, one on the little finger and one at the base of the index finger.

Fig. 4.—Same as Figure 3 after one dose of H 4, B 9 was applied to the lichen lesions. Note the area of temporary pigmentation at the wrist. Note also that the warts have disappeared without having been exposed to the ray.

Digitized by Google

Fig. 5.—Chronic eczema with acute exacerbations.

Fig. 6.—Same as Figure 5 after three treatments at weekly intervals, totaling about H 6, B 9.

Digitized by Google

Fig. 7.—Eczema seborrheicum or psoriasis of six years' duration.

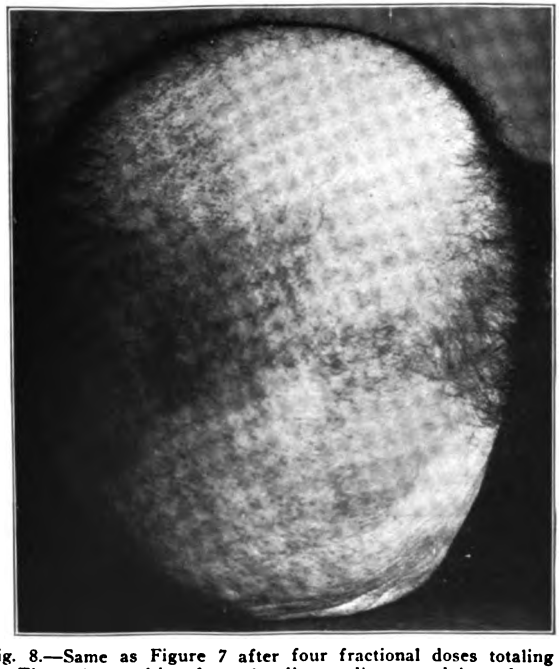

Fig. 8.—Same as Figure 7 after four fractional doses totaling H 8, B 9. The stain resulting from the disease disappeared in a few weeks.

Digitized by Google

Fig. 9.—Hyperhidrosis of the axillae with secondary eczema.

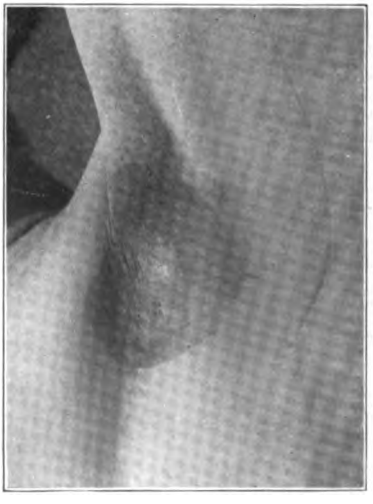

Fig. 10.—Same as Figure 9 after one treatment (H 4, B 9). The staining was temporary.

Digitized by Google

Fig. 11.—Painful plantar wart of 4 years' duration.

Fig. 12.—Same as Figure 11 after two intensive treatments, each of which consisted of H 6, B 9.

Digitized by Google

Fig. 13.—Multiple common warts.

Fig. 14.—Same as Figure 13 after one treatment consisting of H 4, B 9.

Digitized by Google

Fig. 15.—A favorite site for the common wart and a difficult situation to curet or apply acid. One Roentgen-ray treatment will usually suffice in such a case.

Fig. 16.—Verrucae planae juveniles (flat warts). These do not respond to Roentgen treatment.

Digitized by Google

Fig. 17.—An exceedingly hard keloid following an electric burn.

Fig. 18.—Same as Figure 17 after five intensive treatments totaling H 40, B 9, filtered through 3 mm. of aluminum.

Digitized by Google

Fig. 19.—Keloid following an operation for adenitis.

Fig. 20.—Same as Figure 19, after seven intensive doses totaling H 28, B 9.

Digitized by Google

Fig. 21.—Dermatitis papillaris capilittii (acne keloid) in a negro.

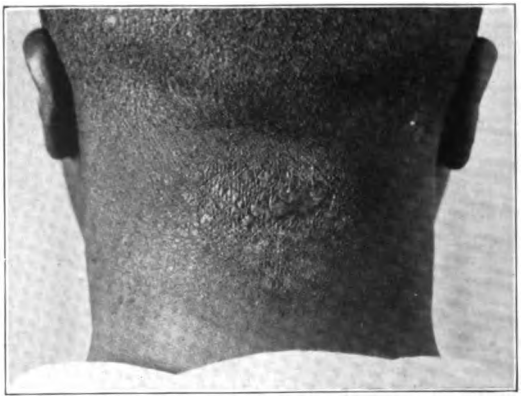

Fig. 22.—Same as Figure 21 after treatment. The lesions were unusually obstinate, and required ten intensive treatments totaling H 50, B 9. The treated skin was depigmented, a defect corrected by using a cutaneous stain.

Digitized by Google

Fig. 23.—A large acne keloid measuring 3 by 2½ inches and six-eighth inch thick.

Fig. 24.—Same as Figure 23 after treatment. Record lost. Response was unusually rapid.

Digitized by Google

Fig. 25.—Hypertrophic lupus vulgaris returning after operation.

Fig. 26.—Same as Figure 25 after one intensive Roentgen-ray treatment.

Digitized by Google

Fig. 27.—Ulceronodular lupus vulgaris involving the mucosa of the nose and throat.

Fig. 28.—Same as Figure 27 after two filtered intensive doses. The mucosa has also improved considerably, and breathing is much easier.

Digitized by Google

Fig. 29.—A case of ulcerative lupus vulgaris, with involvement of the nasal and pharyngeal mucosa, tuberculous adenitis and scrofuloderma cured several years ago with massive doses of the Roentgen ray.

Fig. 30

Fig. 31

Fig. 30.—Small anatomic tubercle (tuberculosis verrucosa cutis).
Fig. 31.—Same as Figure 30 after one dose of H 4, B 9.

Digitized by Google

Fig. 32

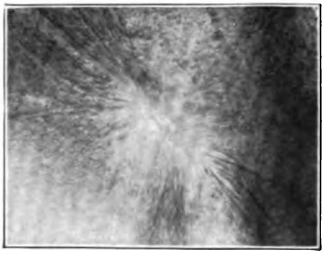

Fig. 33

Fig. 32.—Ulcerating basal-cell epithelioma with considerable induration of margin.

Fig. 33.—Same as Figure 32 after one intensive treatment consisting of H 8, B 9. Treated three years ago — no relapse.

Fig. 34.—Ulceronodular epithelioma of inner canthus — a favorite situation and a difficult position for operation.

Fig. 35.—Same as Figure 34 after one intensive treatment of H 8, B 9. Treated three years ago — no relapse.

Digitized by Google

Fig. 36.—Ulceronodular basal-cell epithelioma not affected by long-continued fractional doses.

Fig. 37.—Same as Figure 36 after three filtered intensive treatments totaling H 38. Patient disappeared in June, 1914, without being pronounced cured.

Digitized by Google

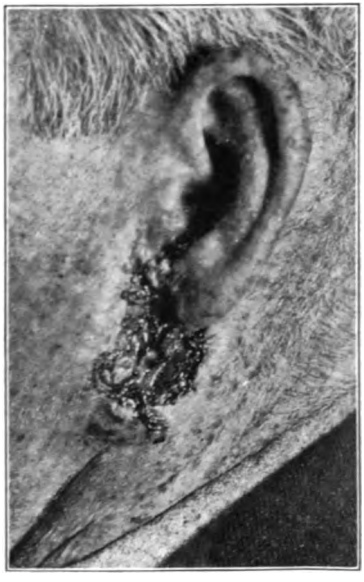

Fig. 38.—Squamous cell (malignant) epithelioma — hard and deep seated.

Fig. 39.—Same case as shown in Figure 38 after two filtered, intensive doses of H 16 each. There was no operative procedure or any other form of treatment. There has been no relapse for one year.

Digitized by Google

Fig. 40.—Photomicrograph of small piece of tissue removed from lesion shown in Figure 38.

Digitized by Google

Fig. 41

Fig. 42

Fig. 41.—Squamous-cell epithelioma resulting from a chronic radiodermatitis on the hand of a Roentgen-ray worker. The growth was removed surgically, but returned immediately.

Fig. 42.—Same case as Figure 41 after two filtered, intensive applications of H 14 each. There has been no relapse during a period of two years. This patient had several other Roentgen-ray keratoses, one of which was beginning to ulcerate. These failed to respond to the Roentgen ray, but they did disappear under the influence of radium.

Fig. 43.—Preepitheliomatous keratosis of the lip.

Fig. 44.—Same as Figure 43 after two intensive treatments of H 8 each.

Digitized by Google

Fig. 45.—Epithelioma of lip without glandular involvement. The lesion consisted mostly of a keratosis, but there was some clinical infiltration. This should probably be considered a preepitheliomatous lesion, or a very early epithelioma.

Fig. 46.—Same as Figure 45. The thickened horny layer was first removed, and then two intensive doses of H 8 each were administered. There has been no return over a period of two years. There was a little leukoplakia, which also disappeared.

Digitized by Google

Fig. 47.—Melanoma.

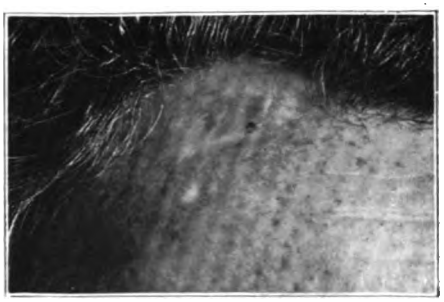

Fig. 48.—Same as Figure 47. Patient received three unfiltered, intensive treatments totaling H 14. A few months later there was a relapse. Two filtered treatments totaling H 24 were then given. No relapse since November, 1914.

Digitized by Google

Fig. 49.—Hemorrhagic, pigmented sarcoma (Kaposi). The lesions are deeply pigmented and elevated. The hand is edematous and very painful.

Fig. 50.—Same as Figure 49 after two intensive applications to each lesion (H 3 filtered). The edema and pain quickly subsided. The infiltration gradually disappeared. When the photograph was taken, there was still some pigmentation, which was gradually disappearing.

Digitized by Google

Fig. 51.—Sarcoma of eye, lids and cheek. Originally the lesion extended to the ear, the commissure of the mouth and onto the forehead. The photograph was taken after considerable improvement had followed an intensive Roentgen-ray treatment. The diagnosis was made by means of the microscope.

Digitized by Google

Fig. 52.—Same as Figure 51 after the second intensive application. Later, and without further treatment, the disease entirely disappeared. The patient finally died of either pulmonary tuberculosis or possibly sarcoma of the lungs.

Digitized by Google.

Fig. 53.—Mycosis fungoides.

Digitized by Google

Fig. 54.—Same as Figure 53 after one mildly intensive treatment. The patient was first "immunized" by fractional doses applied to lesions on other parts of the body.

Digitized by Google

Fig. 55.—Sycosis vulgaris—both sides of face equally involved.

Fig. 56.—Same as Figure 55 after one treatment (H 4). Photograph shows a relapse which necessitated additional treatment.

Digitized by Google

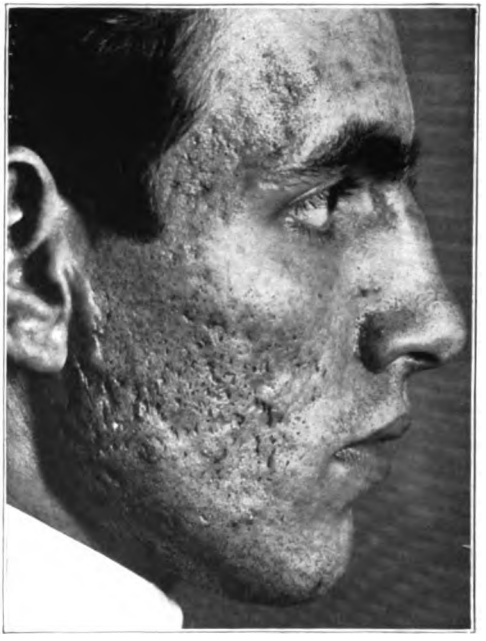

Fig. 57.—Acne vulgaris of long standing quickly and permanently cured with the Roentgen ray without visible injury to the skin. The disfiguring scarring shows the fallacy of postponing Roentgen-ray treatment in obstinate cases until so much destruction has occurred.

Digitized by Google

Fig. 58

Fig. 59

Fig. 58.—Ringworm of scalp (*Med. Rec.*, New York, Aug. 7, 1915).

Fig. 59.—Same as Figure 58 after one epilating dose (*Med. Rec.*, New York, Aug. 7, 1915).

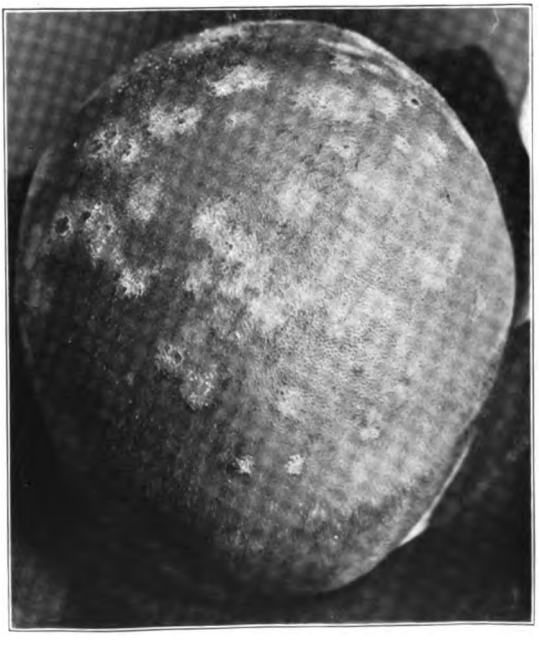

Fig. 60.—Depilation of entire scalp by the Kienböck-Adamson method (*Med. Rec.*, New York, Aug. 7, 1915).

Digitized by Google

Fig. 61.—Cheilitis glandularis of long standing, with a few herpetic vesicles on chin and right commissure.

Fig. 62.—Same as Figure 61 after one intensive application (H 4, B 9).

Digitized by Google

Fig. 63.—Ichthyotic skin.



Fig. 64.—Same as Figure 63 after one intensive treatment.

Digitized by Google

Fig. 65.—Hairy nevus.

Fig. 66.—Same as Figure 65, showing effect of an epilating dose. Two or three such treatments are required to produce a permanent alopecia.

Digitized by Google

however, the disease will continue to spread so that subsequent complete depilation becomes necessary. By the proper use of the Roentgen ray it is possible to cure tinea tonsurans in a few weeks, a fact of great importance in localities where the disease is common.

Tinea Sycosis.—This affection can usually be successfully controlled by removing the hairs by vulsion and applying antiparasitic ointments. A single epilating dose of the Roentgen ray applied to the affected region will usually suffice to produce a cure, if mild antiparasitic agents are also employed.

Onychomycosis.—I have seen ringworm of the nail disappear as a result of a single erythema dose. This, however, is the exception rather than the rule. Usually several such treatments are necessary, and I have encountered instances in which the Roentgen ray failed to produce the desired result.

Miscellaneous Parasitic Affections.—Actinomycosis, and especially blastomycosis are greatly benefited by radiotherapy. I am not in a position to advocate any special technic, but I prefer the intensive method.

Miscellaneous Diseases.—I have had a few good results in cases of leukoplakia by utilizing the intensive method. On the other hand, most of my attempts have been failures. Roentgenotherapy will often prove helpful in the treatment of cheilitis glandularis.

I desire to thank Prof. John A. Fordyce for placing the facilities of the clinic at my disposal, and Dr. John Remer for searching the records and obtaining the necessary data.

Digitized by Google

RADIANT ENERGY IN THE TREATMENT OF DISEASES OF THE SKIN

EVERETT S. LAIN, M.D.
OKLAHOMA CITY

In the discussion of this subject, I am presuming that with the present-day knowledge of radiant energy and the physical laws which govern it, whether this energy emanates from the sun or an electrical source, no progressive medical man can longer deny that radiotherapy has come to stay. Even the shrewd merchant in the commercial field has perceived its popularity and has named his goods, "Radium Diamonds," "Violet-Ray Lotions," "X-Ray Corn Solvents," etc.

Radiotherapy is no longer an experiment, and the proved field is becoming more and more widened until all departments of medicine have had to give it consideration.

Surgical diagnosis without the aid of the Roentgen ray is an antiquated art. Medical diagnosis and treatment with some form of this energy has become a matter of daily routine, though perhaps to the dermatologist these agents lend their greatest therapeutic aid.

The forms and sources of radiant energies which are being used by dermatologists are so numerous that I shall be able, within one paper, to mention but few. Of these perhaps the most commonly used are the Finsen light, violet ray, high-tension current effluvia (commonly though incorrectly called the violet ray), radium, and the Roentgen or x-ray.

I have not had personal experience with the application of the Finsen ray or with a strong potency of radium; therefore I shall leave the discussion of these

Digitized by Google

two agents to others who have had sufficient experience and await their tabulated results. So far, however, as I have been able to observe recorded cases, I am convinced that the physiologic and histologic effects of both of these agents are not unlike those of the Roentgen ray, except that each differs from the other in potency and in the periods of time required to produce like changes in cellular life. In fact, the effects of the Finsen ray, violet ray, high-tension effluvia, radium, and Roentgen ray, when applied to the skin for different periods of time, give reactions which are so nearly alike that it has seemed convenient to divide these effects into the same divisions which have previously been applied to the effects of the Roentgen ray alone:

1. When one of these agents is applied directly or in near contact to the skin for a period, we note, when the reaction becomes visible, quoting from Tousey, "a stimulation of the sympathetic nerves, a pouring out of the blood plasma, increased oxidation, and metabolism."

2. When a greater degree or longer period of application has been given, we note an increase of each of the first-named changes, with the additional increase of hyperemia, elevation of temperature, and a beginning of cell degeneration with a slight exfoliation of the superficial layers of the skin.

3. If the application is continued longer or in a still more intense degree, we note an exaggeration of all the second-degree symptoms, with the beginning of an inflammation in the delicate lining membranes of both the blood and lymph channels, producing an obliterating endarteritis and lymph block throughout the area receiving the direct rays. This may be of such degree as to cause a complete death and slough of the tissue. These degrees of reaction more correctly describe those which are produced by radium, violet ray, and Roentgen ray.

Digitized by Google

The reactions, following the application of high-frequency effluvia (that is, the violet-colored light with its shower of sparks produced by the passing of a high-tension current through a glass vacuum electrode), of fulguration (the hot spark of the same current when allowed to leap from a pointed electrode), and of diathermy (the intense heat of the tissues which is produced by the double or bipolar high-tension current placed in contact with the surface of the lesion on opposite sides) are similar to the agents named above, though they produce their reactions *immediately* following their application.

It is a demonstrable fact that cellular life is stimulated and metabolism increased within the first degrees of reaction, while within the second and beginning third degrees cell life undergoes degenerative changes, the pathologic cells degenerating at an earlier period and with more rapidity than the normal cells. To this law we owe the successes accomplished in the treatment of malignant and other pathologic growths; also, may I suggest, in the first degree or its effects is found, no doubt, the secret of many of our failures.

Then, as already implied I believe that whenever we have more carefully studied the histopathology of diseases to be treated, and acquired a more accurate technic of application, we shall more nearly agree as to the value of these energies and have our efforts more commonly crowned with success in the treatment of a certain class of superficial malignancies and diseases of the skin.

I have often longed for the time when skin diseases might possibly be classified with reference to their etiology, histopathology, etc., so that we might study these methods of treatment more systematically and be able to present them to medical students in a more intelligent manner. I have in recent months undertaken such a classification, and though as yet it is tentative, it coincides with my experience in the appli-

Digitized by Google

cation of electrotherapeutic methods. These conclusions are based on an experience of nearly thirteen years with the use of one or more forms of these energies, the last seven years being devoted exclusively to dermatology and electrotherapy.

Under the first division or class of skin diseases, I have placed those which have not been favorably influenced by the application of radiotherapy, except in the region of its local application. These diseases constitute a class whose etiology is yet unknown, though they are supposed to have their origin in some toxic product which has been absorbed or has failed to be eliminated by the internal organs, whose function it is to act on them, such as dermatitis herpetiformis, the different varieties of erythemas, the lichens, psoriasis, etc. By way of parenthesis permit me to say that since hearing Dr. Rosenow's report on his discoveries in erythema nodosum, I have been making radiograms of the teeth of a number of these patients and have collected strong evidence tending toward a conclusion of focal infections as a possible etiology in many of this class of diseases; but I am not yet in a position to report on these cases.

Under a second division, I have named a class of diseases which appear to be an inexplicable derangement or condition of the superficial glands, nerves, or of metabolism within the cells, no doubt internal or central in origin, which are favorably influenced by some form of radiotherapy, though with few exceptions they are best relieved by medicinal means combined with some form of radiant energy. Among there are such as: hyperhidrosis, pompholyx, pruritus, prurigo, herpes zoster, most forms of eczema, etc.

In a third class I place most of those diseases which are superficial in origin and are due to local infection of a micro-organism of some variety, such as acne vulgaris, staphylococcic and streptococcic infections, erysipelas, and practically all the mycoid and fungoid

Digitized by Google

infections of the skin, including the tineas, blastomycosis, sporotrichosis, etc. A large percentage of this class will yield nicely to one or more forms of the radiant energies without the use of medicinal applications, though in most of these cases I would prefer to use a combination of medicinal treatment and radiotherapy.

In a fourth class I shall place practically all lesions or diseases which are characterized by an increased development of pathologic cells, whether of a benign or a malignant nature, such as fibroma molluscum, rhinophyma, keloids, superficially located epitheliomas, etc.

I believe that most of the above-named classes of lesions are amenable to some form of radiotherapy alone, if this is applied with intelligent and cautious technic in the earliest stages of the development of the lesion.

Briefly reviewing, then, and speaking more specifically with reference to a few of the above-named classifications, I believe that an attempt to treat a class of skin diseases which are evidently systemic in origin, whether of a toxic or infectious nature, by radiotherapy locally applied, may give some temporary relief, though it is like an attempt to destroy the life of a serpent by beginning at its tail. These agents, therefore, can be recommended only as one of the aids of dermatologic therapy. I have found the Roentgen ray in the treatment of hyperhidrosis, dyshidrosis and several forms of eczema an almost indispensable aid if pushed to a point of first reaction in the first series of treatments, though without other or medicinal treatments these eruptions are prone to recur. The Roentgen ray has given me valuable aid in the treatment of all forms of pruritus and in one case of true prurigo I have been entirely successful.

Perhaps the most remarkable effect observed on any disease under the second classification, is the almost certain relief from the lancinating and burn-

Digitized by Google

ing pains, so characteristic in herpes zoster, which occurs when the high-frequency effluvia is vigorously applied over the trunk and superficial nerve supply of the parts affected. This relief sometimes comes immediately following only one application.

In view of the clinical reports of the treatment of tineas with the Roentgen ray by Sabouraud several years past, it is unnecessary to comment on my own verifications of it, since most of you have doubtless experienced the same gratifying results.

Notwithstanding the fact that the treatment of acne vulgaris and acne rosacea by Roentgen ray has been disparaged by many dermatologists as dangerous, and giving unsatisfactory sequelae, etc., I have continued to use this most valuable aid as a routine for ten years in the treatment of these diseases and in not a single case as yet have I had cause for regrets.

Erysipelas has long been known as a local and superficial infection with systemic products. With this in mind I began, in 1910, to treat the early manifestations of this disease by a single series of Roentgen-ray exposures and after treating a number of cases, beginning at an early stage of the disease, I am fully convinced that it is a most valuable aid. Indeed, in some of these cases, I noted after either a single or a second exposure an immediate flushing of temperature, which, however, subsided within from two to six hours, with an abating of all symptoms and an uneventful recovery.

Of the fourth classification, perhaps the most uncertain results I have obtained have been in the treatment of the different varieties of sarcomas by radiotherapy. This class of malignant growths has not proved a very favorable one to treat by radiotherapy alone. No doubt this is due to their channels of absorption, the blood vessels, which are not rapidly and quickly blocked without an unusually strong treatment. With this exception, I have found the treating of this class of lesions by fulguration, diathermy, or

Digitized by Google

Roentgen ray one of the most successful and satisfactory phases of all my work, and furnishing an unbounded field for dermatologic practice.

The treatment of superficial epitheliomas before the stage of well-developed metastasis has been a large part of my practice and I cannot refrain from reporting a few of the totals and percentages briefly gleaned from my records of the past few years.

For these cases and for most valuable assistance rendered in the treatment of them I am much indebted to my many professional friends of Oklahoma and other states, and to my associate in practice for the past six years, Dr. M. M. Roland. The length of this paper will not permit more than a statement of totals, without comment. A number of years have elapsed since treating my first case of epithelioma with the Roentgen ray, and it is therefore impossible at this time to trace the after-history of all of my early cases. Therefore, taking our records consecutively for the last seven years, we have been able to trace 177 cases of epitheliomas of different varieties and located superficially on various parts of the body. In a large number of these cases the diagnosis was verified both microscopically and clinically. From this number we have to deduct fifteen cases in which the patients have later died of the same disease or have had a recurrence, and we count them as Roentgen-ray failures. This leaves us a balance of 162, or 91 per cent., in which the patients are now living with no evidences of return.

We have learned that epitheliomas located on the hands and on the alae of the nose, just at its fold on the cheek, perhaps owing to a greater mobility and irritation, are of an uncommonly stubborn nature, and five of our failures have been in such cases. If therefore, we had subtracted the cases at these particular locations, we should have 94 per cent. living instead of 91 per cent. of those treated by Roentgen ray alone on selected locations.

Digitized by Google

And now, you may say, what of the much-discussed location of epitheliomas on the lips? We have traced twenty-seven consecutive patients who were treated by the Roentgen ray alone during the past seven years. Of this number, twenty-two, or 81 per cent., are still living without recurrence. Some of these were treated five and some seven years ago, and we have no doubts that a majority of these are entirely well.

It may be said that no such record can be made except in select cases. This I admit, although in a number of these cases the lesions were well-developed indurated growths as large as a hazelnut or larger, and one of these cases had perceptible evidence of metastasis in the submaxillary region. Most of them, however, were those, as above mentioned, in which treatment was begun before evidence of metastasis, and had not more than one third of their surface covered by the mucous membrane.

In conclusion, then, I shall say that my experience with the use of radiotherapeutic agents in skin diseases has taught me:

1. It is necessary to look carefully into the pathology and etiology of a disease before attempting to treat by one of these methods.

2. These agents are valuable aids in the treating of a certain class of skin diseases when combined with medicinal and other methods.

3. There is a class of skin diseases, chiefly local in origin, which can be treated my radiotherapy more successfully than by any other method.

4. While the treatment of malignant lesions with these energies is much abused by the unskilled, yet we are coming to recognize that radium and the Roentgen ray, when properly administered in a selected class of cases, have proved themselves superior to all other methods which have been used to the present time.

Digitized by Google

ABSTRACT OF DISCUSSION

Dr. Richard L. Sutton, Kansas City, Mo.: The results attained by these two speakers have done much to convince me of the value of the massive dosage method. In order to avoid disastrous results, however, great care and a considerable degree of skill are necessary. I well recall a recent instance in the practice of a colleague in which this method was employed in the treatment of a case of ringworm of the scalp. A severe burn resulted, and extensive skin grafting was required to correct the ensuing deformity. With regard to the prognosis in cancer of the skin, I have found carcinomas involving the mucous membranes, the lower lip, the cartilage of the ear, the parotid region, and the backs of the hands to be the most dangerous.

Dr. Ernest Dwight Chipman, San Francisco: I remember reading the discussion of Roentgen-ray treatment at a meeting in New York in which some one expressed the view that in New York the Roentgen ray was no longer seriously regarded as a therapeutic agent in dermatology. It seemed to imply that we poor souls in the provinces who still use it are hopelessly behind the times. I am glad Dr. MacKee's paper does not confirm this notion. Dr. MacKee expresses dissatisfaction with small doses and we all must have corroborated that idea in our own experiences. I have noted not only in epitheliomas but also, and particularly, in psoriasis, that while one gets a temporary recovery, recurrence takes place, and the recurrence is more difficult to get rid of than the original trouble. I may have misunderstood Dr. Lain in his reference to erysipelas; I gathered from his paper that the Roentgen ray was a parasiticide, which I have never believed and which I would be glad to hear him explain.

Dr. Douglass W. Montgomery, San Francisco: In epithelioma I like to curet out the neoplasm to get down to the base; and I do that because I believe the Roentgen rays do not act very deeply. Furthermore, there is no object in sparing the diseased tissue. After scraping away the diseased tissue I burn the base with a good penetrating caustic. This serves two purposes; it eliminates any cancerous tissue that may still remain, and it seals the wound against infection. This gives a cleared base on which the Roentgen rays can best act effectively. Dr. MacKee mentioned that in the previous discussion.

Dr. MacKee mentioned a most interesting and difficult matter when he spoke of warts under the nails. We have had now for a long time a girl under our charge with sweating palms and with most persistently recurring warts of the volar surfaces of the fingers. The sweating persisted and the warts recurred even after the employment of Roentgen rays. Some assert that flat warts, verrucae planae, may be removed

Digitized by Google

by Roentgen rays, but I do not see why Roentgen rays should be used on flat warts, and I think it is better to treat them with the curet and strong acetic acid.

Dr. H. H. Hazen, Washington, D. C.: During the past winter I have been doing Roentgen-ray work as done by Dr. MacKee, and I want to say it has been the biggest gain in therapy that I know. There is no more comparison between the old and the new methods of using the Roentgen ray than between any other widely separated things.

It seems tc me it might be theoretically dangerous to curet a cancer before using the Roentgen ray. I think the best thing to do when you want to get rid of the surface is to use the electric cautery. That opens up no channels.

I was interested in Dr. Lain's statement that he cured 90 or 91 per cent. in a group of epithelioma. Were those cases followed up by Dr. Lain for a period of five years? We had no statistics over this five-year period in Roentgen-ray work; but I hope that Dr. MacKee and Dr. Lain and others using the Roentgen ray will publish their results. We need in the worst way those results, in order to compare them with results obtained by surgical procedures.

Dr. Harry E. Alderson, San Francisco: The reason we hear of different results from the use of Roentgen rays in the hands of different men is that there is no common standard of measurement of the dosage in use. I think very often great chances are taken by individuals in attempting to apply the Roentgen ray without using any of the known means of measuring the doses. Should burns result from such unmeasured doses there is no doubt in my mind that legal action could be successfully conducted against the operator. The fact that half-way measures in the treatment of epitheliomas are extremely dangerous cannot be too strongly emphasized. Either the knife should be used thoroughly or the ray intensively, or both should be used. We prefer the knife and afterward the ray. Most of the cases of extensive epitheliomas that we see are in patients who have had the early lesions treated with the various "half-way measures" advocated from time to time.

Dr. George M. MacKee, New York: I prefer to curet the nodular type of basal cell epithelioma. If this is done a cure can usually be effected as a result of a single erythematous dose of the Roentgen ray. I do not curet the squamous cell type of epithelioma.

Regarding the parasitic or germicidal action of the Roentgen ray, it is the general consensus of opinion that it has none. We know, for instance, that a very small amount of Roentgen ray will sometimes cure sycosis vulgaris, but this prompt action is probably due to a modification of the soil rather than to direct action on the bacteria.

Digitized by Google

Dr. Everett S. Lain, Oklahoma City: Dr. MacKee answered Dr. Chipman's question, only I wish to add that by blood count following the Roentgen-ray treatment, that is, a count within from thirty minutes to two hours, you will note in most treatments, quite remarkable changes in the count of the red and white corpuscles. You usually have an increase in the leukocytes. There is no doubt to one who has made the test, that indirectly the Roentgen ray does serve as a parasiticide. Dr. Haven asked how long we followed these cases. I said in my paper that they covered seven years. I might have included in that nearly 200 cases that antedated that period. These cases I did not have time to trace after I decided to write this paper. About 20 per cent. of the reported cases have been treated in the past two years. About 60 per cent. prior to that time. According to former statements of surgeons, that is a good test of a cure. We believe these patients are well. However, we can allow a reduction of the percentages and yet have a fair percentage of recovery.

Dr. H. H. Hazen: What percentage of five-year cures have you had?

Dr. Everett S. Lain: I cannot give the figures without looking up my records, but making a guess, I should say not less than 35 per cent., excepting those on the hands, which as I said have been uncertain.

Digitized by Google

LIST OF FELLOWS OF THE AMERICAN MEDICAL ASSOCIATION REGISTERED IN THE SECTION ON DERMATOLOGY

List of Fellows of the American Medical Association who registered in this Section at one or more of the last five Annual Sessions, together with Fellows who are subscribers to the transactions of the section for 1915. The figures following the names indicate the record of attendance at Annual Sessions. (4 indicates 1914; 3, 1913, etc.) T indicates a subscriber to the transactions.

Abernethy, Claude O., 423 Fayetteville St., Raleigh, N. C. 4.
Abramowitz, Elias Wm., 950 Ave. St. John, New York City.
Alderson, Harry E., 240 Stockton St., San Francisco. 5.
Andrus, A. P., 212 6th Ave.. W., Ashland, Wis. 3.
Ankrim, L. F., 5014 Penn Ave., Pittsburgh. 6, 8, 9, 4.
Armstrong, J. M., 227 Lowry Arcade, St. Paul. 3.
Atkinson, A. D., 921 N. Charles St., Baltimore. T.
Babcock, I. G., Cumberland, Wis. 3.
Baer, C. A., 128 Wisconsin St., Milwaukee, Wis. 4.
Baeslack, F. W., 472 Penna Ave., Detroit, 3, 4.
Bathurst, Wm. R., 810 State Bank Bldg., Little Rock, Ark. 9, 3, 4.
Baum, Henry C., 813 University Blk., Syracuse, N. Y. 4.
Baum, Wm. L., 30 N. Michigan Blvd., Chicago. 4.
Bechet, Paul E., 40 E. 41st St., New York City. 4.
Bernheimer, H. L., 4th and Main, Terre Haute, Ind. 3.
Best, Wm. H., 1198 Bushwick Ave., Brooklyn. 4.
Biddle, Andrew P., 938 D. Whitney Bldg., Detroit. T.
Bierhoff, F., 10 W. 61st St., New York. T.
Blake, Charles R., 707 MacDonald Ave., Richmond, Calif. 5.
Boggs, Russell H., Empire Bldg., Pittsburgh. 6, 7, 9, 4.
Boreen, C. A., Syndicate Bldg., Minneapolis. 3.
Bradley, Mark S., Conn. Mutual Bldg., Hartford, Conn. T.
Brayton, A. W., 330 Newton Claypool Bldg., Indianapolis. T.
Brown, Warren, 207 Equitable Bldg., Tacoma, Wash. 4.
Brownson, W. C., Medical Bldg., Asheville, N. C. 4.
Bulkley, L. D., 531 Madison Ave., New York. 2, 3, 4, 6, 7, 9, 3, 4, 5.
Bull, Thomas M., 253 Church St., Naugatuck, Conn. T.
Burke, John G., 8122 Jenkins Arcade, Pittsburgh. T.
Calkins, F. R., 4 Cleveland Bldg., Watertown, N. Y. T.
Campbell, R. R., John Brockman Bldg., Los Angeles. T.
Carbaugh, Eugene, 611 Sharp Bldg., Kansas City, Mo. 3.
Chipman, E. D., 240 Stockton St., San Francisco. 9, 3, 5.
Clark, Thomas J., 6446 Harwood St., Oakland, Calif. 5.
Clark, Wm. L., 1809 Chestnut St., Philadelphia. 4.
Cole, H. N., 2047 E. 9th St., Cleveland, 4.
Collings, S. P., Dugan Stuart Bldg., Hot Springs, Ark. T.
Corlett, Wm. Thos., 3618 Euclid Ave., Cleveland. 4.
Corson, Edw. F., Cynwyd, Pa. 4.
Councilman, W. T., 78 Bay State Road, Boston. T.
Cousins, W. L., 231 Woodfords St., Portland, Maine. T.
Cox, Thos. J., 701 I St., Sacramento, Calif. T.
Cregor, Frank W., Hume-Mansur Bldg., Indianapolis. 4.
Crume, G. P., 636 Syndicate Bldg., Minneapolis. 8, 3.
Culver, George D., 150 11th Ave., San Francisco. 5.
De Foe, W. A., 221 S. Jefferson St., Saginaw, Mich. 3.
Desmond, M. A., Akeley, Minn. 3.
Dowling, Oscar, Last Nat. Bk. Bldg., Shreveport, La. T.
Dunning, Z. F., Philmont, N. Y. T.
Dyer, Isadore, 124 Baronne St., New Orleans. 3, 4, 3, 4.
Eldredge, J. S., 10 Main St., Kansas City, Mo. 3, 5.
Engman, Martin F., 219 Wall Bldg., St. Louis. 4.
Erdman, Bernhard, 432 Newton Claypool Bldg., Indianapolis. T.
Farrell, John T., 10 Lillian Ave., Providence, R. I. 7, 8, 9, 3, 4.
Fewsmith, Joseph, 47 Central Ave., Newark, N. J. 5.
Field, G. J., Judge Bldg., Salt Lake City. T.

Digitized by Google

Finck, Edward Beecher, 1120 Girard St., Philadelphia. 6, 7, 8, 9, 4.
Fitzgerald, Clara P., 137 Pleasant St., Worcester, Mass. 5.
Foerster, O. H., 128 Wisconsin St., Milwaukee. 6, 8, 9, 3, 4.
Fordyce, I. A., 8 W. 77th St., New York City. 3, 4, 7, 8, 9, 4.
Foster, Burnside, Lowry Arcade Blk., St. Paul. 4, 6, 3.
Fox, George Henry, 616 Madison Ave., New York. 7, 9, 3, 4.
Fox, Howard, 616 Madison Ave., New York City. 4, 5.
Fox, Wm. G., 48 E. Orange St., Lancaster, Pa. 4.
Frauenthal, Henry W., 783 Lexington Ave., New York. T.
Freeman, Chas. D., 642 Lowry Bldg., St. Paul. 8, 3.
Frescohn, Leonard D., 3944 Aspen St., Philadelphia. 4.
Frick, Wm., 212 Benton Road, Kansas City, Mo. T.
Friedlander, David, 146 Grant Ave., San Francisco. 5.
Gnichtel, A. L., 257 W. 44th St., New York. 6, 7, 8, 9, 3, 4.
Gold, James D., 839 Myrtle Ave., Bridgeport, Conn. T.
Gottheil, W. S., 154 W. 77th St., New York. 2, 4, 6, 7, 9, 4.
Grant, W. W., 304 Mack Bldg., Denver. T.
Haase, Marcus, 1222 Memphis Trust Bldg., Memphis, Tenn. 8, 9, 4.
Hailperin, Clement J., 181 Hunterdon St., Newark, N. J. 4.
Hamilton, Geo. L. A., 701 Central Ave., Kansas City, Kan. 4.
Harris, F. G., 6617 Woodlawn Ave., Chicago. 3.
Harris, M. L., 1528 Dearborn Parkway, Chicago. T.
Hart, Lasher, 318-20 Title Ins. Bldg., Los Angeles. 5.
Hartzell, Milton B., 3644 Chestnut St., Philadelphia. 2, 7, 8, 9, 4.
Hazen, H. H., The Rochambeau, Washington, D. C. 9, 3, 4, 5.
Heidingsfeld, M. L., 19 W. 7th St., Cincinnati. 2, 3, 4, 6, 7, 8, 9, 3, 4.
Hirschler, Rose, 126 S. 17th St., Philadelphia. 4.
Howe, Lucien, 522 Delaware Ave., Buffalo. 4.
Hulburd, H. L., Morris, Minn. 3, 5.
Hunt, W. J., 21 Notre Dame St., Glens Falls, N. Y. T.
Irvine, H. G., 601 Syndicate Bldg., Minneapolis. 3.
Jackson, Geo. T., 616 Madison Ave., New York. T.
Johnson, Murrey L., 621-24 First Nat. Bk. Bldg., San Francisco. T.
Jones, P. M., Butler Bldg., San Francisco. T.
Katzenstein, G. P., 1915 N. Broad St., Philadelphia. 9, 4.
Keck, Frederick C., 948 Market St., San Francisco. 5.
Kellogg, J. H., Battle Creek Sanit., Battle Creek, Mich. T.
Kellow, W. J., Flower Bldg., Watertown, N. Y. T.
Kessler, J. B., Iowa City, Iowa. 3. 4, 6, 7, 8, 9, 3, 4, 5.
Kilroy, Philip, 61 Chestnut St., Springfield, Mass. T.
Kimball, Harry W., 276 Benefit St., Providence, R. I. 4.
King, J. C. E., Corbett Bldg., Portland, Ore. 3.
King, J. M., Eve Bldg., Nashville, Tenn. 3.
Kingsbury, Jerome, 32 W. 48th St., New York City. 4.
Knowles, F. C., 2022 Spruce St., Philadelphia. 9, 4.
Kovacs, Richard, 223 E. 68th St., New York City. 4.
Lacy, J. W., Lisbon, Md. 4.
Lain, Everett S., State Natl. Bank, Oklahoma City. 8, 3, 5.
Landfried, Charles J., 5907 Garfield St., New Orleans. T.
Lea, J. I., 303 Stevens Bldg., Detroit. T.
Le Fevre, W. I., 218 Lennox Bldg., Cleveland. 3, 4.
Lespinasse, V. D., 7 W. Madison St., Chicago. T.
Lieberthal, David, 31 N. State St., Chicago. 2, 4, 6, 8, 3.
Linneman, N. L., Fidelity Bldg., Duluth, Minn. 3, 4.
Long, W. Bayard, 1257 Washington Ave., New York. T.
Lowy, Otto, 549 High St., Newark, N. J. 4.
Luce, Thomas W., 82 Court St., Portsmouth, N. H.
Lutz, F. J., 3337 Lafayette Ave., St. Louis. T.
MacGowan, Granville, 602 Lissner Bldg., Los Angeles. T.
MacKee, G. M., 58 W. 58th St., New York City. 3, 4, 5.
Malone, W. F., 324 Madison St., Milwaukee, Wis. T.
Markley, A. J., 432 Metropolitan Bldg., Denver, Colo., 3, 5.
Marvel, Philip, 1616 Pacific Ave., Atlantic City, N. J. T.
McDavitt, Thomas, Lowry Bldg., St. Paul. T.
McDonnell, R. A., 1142 Chapel St., New Haven, Conn. T.
McEwen, Ernest L., 1703 Chicago Ave., Evanston, Ill. 4.
McGavock, E. P., 301 E. Franklin St., Richmond, Va. 4.
Menage H. E., 1241 Baronne St., New Orleans. 3, 6, 3.
Michailovsky, Michael, 235 W. 71st St., New York. T.
Miller, Robert W., 414 Laughlin Bldg., Los Angeles. 5.
Montgomery, Douglass W., 323 Geary St., San Francisco. 5.
Mook, W. H., 219 Wall Bldg., St. Louis. T.
Morrissey, Michael J., 18 Asylum St., Hartford, Conn. 4.
Morrow, Howard, Butler Bldg., San Francisco. 5.
Murray, John L., 347 Nicholas Bldg., Toledo, Ohio. 4.

Digitized by Google

Murrell, Thos. W., 17 E. Grace St., Richmond, Va. 4.
Nadler, Alfred G., 377 Orange St., New Haven, Conn. 4.
Newman, E. D., 81 New St., Newark, N. J. 9, 4.
Nichols, Henry J., % U. S. A., Washington, D. C. 4.
Ober, George Eugene, 632 Kossuth St., Bridgeport, Conn. T.
Ormsby, Oliver S., 25 E. Washington St., Chicago. 5.
Pels, I. R., 922 W. North Ave., Baltimore. 4.
Pickett, J. Cameron, 133 Geary St., San Francisco. 5.
Pollitzer, Sigmund, 51 E. 60th St., New York City. 4.
Powell, Barton J., Physicians' Bldg., Stockton, Calif. 5.
Purdy, A. H., 307 Grand Ave., Milwaukee, Wis. 5.
Pusey, William Allen, Chicago Savings Bank Bldg., Chicago. 2, 4, 7, 8, 9, 3, 4, 5.
Randolph, R. L., 609 Park Ave., Baltimore. 4.
Ravitch, M. L., Atherton Bldg., Louisville, Ky. 8, 3, 4.
Ravogli, Augustus, 5 Garfield Pl., Cincinnati. 2, 4, 6, 7, 8, 9, 3, 4, 5.
Rindlaub, J. H., Fargo, N. D. 3.
Rindlaub, M. P., Fargo, N. D. 3.
Rosenheim, P. J., 508 W. 112th St., New York City. 4.
Rosenthal, Melvin S., 1928 Linden Ave., Baltimore. T.
Rostenberg, A., 1872 Washington Ave., New York. T.
Sarles, W. T., cor. Oak and Water Sts., Sparta, Wis. T.
Schalek, Alfred, 518 Brandeis Theatre, Omaha, Neb. 3.
Schamberg, J. F., 1922 Spruce St., Philadelphia. 4.
Scheer, Max, 901 Fox St., Bronx, New York City. 4.
Schiller, Leopold, 830-34 Caswell Blk., Milwaukee, Wis. 3.
Schmitt, L. S., 830 Butler Bldg., San Francisco. 5.
Schwartz, Arthur H., New Jersey Bldg., Duluth, Minn. 3.
Schwartz, L. L., 905 Keenan Bldg., Pittsburgh. 4, 5.
Shedd, G. H., N. Conway, N. H. T.
Shedd, J. Z., N. Conway, N. H. T.
Shelmire, Jesse B., Main St., Dallas, Tex. 4.
Simpson, C. Augustus, 1217 Conn. Ave., Washington, D. C. 4.
Simpson, F. E., 59 E. Madison St., Chicago. 3, 4.
Stelwagon, Henry W., 1634 Spruce St., Philadelphia. 2, 4, 6, 7, 9, 4.
Stearns, B. W., Unadilla, N. Y. T.
Strauss, Abraham, 1226 Spruce St., Philadelphia. 4.
Sumney, H. C., 1011 New Woodman of the World Bldg., Omaha, Neb. 4.
Sutton, R. L., 726 Lathrop Bldg., Kansas City, Mo. 3, 4, 5.
Swarts, Gardner T., State Board of Health, Providence. 2, 3, 4, 6, 7, 9, 4.
Sweitzer, S. E., 625 Syndicate Bldg., Minneapolis. 3, 4.
Thompson, Wesley, Huntington Park, Calif. 5.
Thorndike, T. W., 20 Newbury St., Boston. T.
Towle, Harvey P., 453 Marlborough St., Boston. T.
Tucker, E. D., 227 Michigan St., Toledo, Ohio. 8, 9, 3, 4.
Van Gaasbeek, G. H., 29 Berkley St., Springfield, Mass. T.
Varney, H. R., Kresge Bldg., Detroit. 2, 3, 4, 6, 7, 8, 9, 3, 4.
von Toll, Edward, 915 Belmont Ave., Chicago. 3.
Wallhauser, H. J. F., 47 New St., Newark, N. J. T.
Wareham, Arthur, Morrisville, Pa. 4.
Washburn, Wm. H., 1240 Wells Bldg., Milwaukee, Wis. T.
Waugh, J. F., 1527 E. 65th St., Chicago. 3.
Weiss, Ludwig, 42 W. 91st St., New York City. 4.
Wende, Grover W., 471 Delaware Ave., Buffalo. T.
Wertheimer, H. G., Westinghouse Bldg., Pittsburgh. T.
White, Chas. J., 259 Marlborough St., Boston. 4.
Whitehouse, Henry H., 38 East 49th St., New York. T.
Wilcox, R. S., 656 Broad St., Providence, R. I. T.
Wilkenson, L. B., Russellville, Ky., 3.
Wiltsie, S. F., 811 Cobb Bldg., Seattle. T.
Winfield, Jas. M., 47 Halsey St., Brooklyn. 4.
Wise, Fred, 24 W. 59th St., New York City. 3, 4.
Yates, John C., Box 331, Coronado, Calif. 5.
Zeisler, Joseph, 30 N. Michigan Ave., Chicago. 8, 3, 5.
Zurawski, K. A., 4630 S. Ashland Ave., Chicago. 8, 3.

Digitized by Google

Digitized by Google

INDEX

PAGE

Acanthosis nigricans as an indication of internal malignancy; paper by A. J. Markley 165
Discussion 171

Alderson, H. E.: paper on cases from the skin clinic of Leland Stanford Jr. University 124
Discussion on cutaneous cancer 186
Discussion on radiant energy in skin diseases 215

Autogenous serum in treatment of xeroderma pigmentosum; paper by J. B. Kessler 172
Discussion 175

Burns, management of; paper by A. Ravogli 42
Discussion 53

Cancer, cutaneous, of the extremities; paper by H. H. Hazen 177
Discussion 184

Chipman, E. D.: paper on the etiology and treatment of leprosy 108
Discussion on same 123
Discussion on burns 54
Discussion on palmar eruptions 64
Discussion on radiant energy in skin diseases 214
Discussion on skin cases 128

Culver, G. D.: paper on lupus erythematosus of the mucous membranes 67
Discussion on palmar eruptions 65

Cutaneous cancer of extremities; paper by H. H. Hazen 177
Discussion 184

Dermatology of the ancients; paper by H. Fox 13

Dermatoses, factitious; paper by O. S. Ormsby 129
Discussion 162

Fox, H.: paper on dermatology of the ancients 13
Discussion on cutaneous cancer 187
Discussion on leprosy 121
Discussion on palmar eruptions 64
Discussion on skin cases 128

Hart, L.: discussion on factitious dermatoses 163

Hazen, H. H.: paper on cutaneous cancer of the extremities 177
Discussion on same 187
Discussion on lupus erythematosus 83
Discussion on radiant energy in skin diseases 215, 216

Kessler, J. B.: paper on autogenous serum in treatment of xeroderma pigmentosum 172
Discussion on same 176
Discussion on lupus erythematosus 80

Lain, E. S.: paper on radiant energy in treatment of skin diseases 206
Discussion on same 216
Discussion on cutaneous cancer 187
Discussion on leprosy 120
Discussion on lupus erythematosus 80
Discussion on palmar eruptions 64
Discussion on skin cases 127

Lee, A. W.: paper on the diagnosis of leprosy 96
Discussion on same 122

Leprosy, diagnosis of; paper by H. Morrow and A. W. Lee 117

Leprosy, etiology and treatment; paper by E. D. Chipman 108
Discussion 117

Leprosy, history of: paper by D. W. Montgomery 84
Discussion 117

Lupus erythematosus of the mucous membranes; paper by G. D. Culver 67
Discussion 79

McCoy, G. W.: discussion on leprosy 118

Digitized by Google

PAGE

MacKee, G. M.: paper on Roentgen-ray treatment of skin diseases.. 189
Discussion on cutaneous cancer..... 186
Discussion on factitious dermatoses..... 163
Discussion on radiant energy in skin diseases..... 215
Discussion on skin cases..... 127

Markley, A. J.: paper on acanthosis nigricans as an indication of internal malignancy 165
Discussion on factitious dermatoses..... 163
Discussion on lupus erythematosus..... 83
Discussion on palmar eruptions..... 65
Discussion on skin cases..... 128

Montgomery, D. W.: paper on the history of leprosy..... 84
Discussion on same..... 121
Discussion on cutaneous cancer..... 186
Discussion on lupus erythematosus..... 82
Discussion on palmar eruptions..... 64
Discussion on radiant energy in skin diseases..... 214

Morrow, H.: paper on diagnosis of leprosy..... 96
Discussion on same..... 122
Discussion on factitious dermatoses..... 162
Discussion on palmar eruption..... 63

O'Neill, A. A.: discussion on leprosy..... 117, 123

Ormsby, O. S.: paper on factitious dermatoses..... 129
Discussion on same..... 164
Discussion on acanthosis nigricans..... 171
Discussion on skin cases..... 127
Discussion on xeroderma pigmentosum..... 175

Palmar eruptions, symptomatology and treatment of; paper by R. L. Sutton..... 55
Discussion 63

Pickett, A. J.: discussion on palmar eruptions..... 65

Pusey, W. A.: discussion on burns..... 53
Discussion on lupus erythematosus..... 81
Discussion on palmar eruptions..... 63

Radiant energy in treatment of skin diseases; paper by E. S. Lain. 206
Discussion 214

Ravogli, A.: paper on the management of burns..... 42
Discussion on same..... 54
Discussion on cutaneous cancer..... 184
Discussion on leprosy..... 119
Discussion on lupus erythematosus..... 82
Discussion on palmar eruptions..... 63

Roentgen-ray treatment of skin diseases; paper by G. M. MacKee.. 189

Sarcoid, multiple benign, of skin; paper by J. Zeisler..... 33
Discussion 40

Schmidt: discussion on leprosy..... 120

Skin cases; paper by H. E. Alderson..... 124
Discussion 127

Sutton, R. L.: paper on symptomatology and treatment of common palmar eruptions 55
Discussion on same..... 65
Discussion on benign sarcoid..... 40
Discussion on cutaneous cancer..... 185
Discussion on factitious dermatoses..... 164
Discussion on leprosy..... 120
Discussion on radiant energy in skin diseases..... 214
Discussion on skin cases..... 127

Xeroderma pigmentosum, autogenous serum in; paper by J. B. Kessler 172
Discussion 175

Zeisler, J.: paper on multiple benign sarcoid of the skin..... 33
Discussion on burns..... 53
Discussion on leprosy..... 117
Discussion on lupus erythematosus..... 79
Discussion on skin cases..... 127

Digitized by Google

Digitized by Google

Digitized by Google

Digitized by Google

Digitized by Google

UNIVERSITY OF MICHIGAN
3 9015 06991 2296

Digitized by Google

Digitized by Google